

# Paint It Black: Staining of the Yeast *Cryptococcus neoformans* with India Ink

## ABSTRACT

**Aims:** To rectify the application of negative staining using India Ink dye in order to visualize the opportunistic yeast, *Cryptococcus neoformans* and its capsule

**Discussion:** The yeast *C. neoformans* is generally considered an opportunistic fungal pathogen due to its propensity to infect immunocompromised hosts, particularly those with HIV (+). This yeast responsible for causing severe disseminated *Cryptococcus meningoenephalitis* (CM) in humans. The type of clinical sample commonly sent for laboratory analysis of suspected patients is the cerebrospinal fluid (CSF) that usually obtained from spinal tap or lumbar puncture procedure. laboratory analysis to confirm CM initially by direct visualization of *Cryptococci* via light microscopy. Visualization of capsule, as the hallmark of *C. neoformans* is easy when appropriate number of yeasts are available in the clinical sample. India Ink is the dye of choice to stain *C. neoformans* and its capsule. The pathognomonic resemblance of its capsule is that of a halo appearance, whether thin or thick, surrounding the cell made visible by suspending the yeast in India ink preparations.

**Conclusion:** India ink stain is still widely used for the detection of *cryptococci* in CSF, particularly in resource-limited laboratory/health service. Its sensitivity can be improved.

*Keywords: Meningitis, Cryptococcosis, encapsulated, halo, cell, dye, cerebrospinal fluid*

## 1. INTRODUCTION

*Cryptococcus meningoenephalitis* (CM) is a fatal and complicated opportunistic fungal infection associated with Human Immunodeficiency Virus infection [1,2]. It is accounted responsible for >600,000 global unexpected deaths annually [3]. The etiology agent is primarily *C. neoformans* [4], which is commonly found in bird dropping, where bird act as carriers and spreaders in the environment [5], and or in the decaying wood in tree trunk hollows which act as natural substrate of the yeasts comfort zone and nutritional source [6].

If the environment basidiospores accidentally breathed in by the host [7], it then goes to the lung, and able to penetrate deeply into lung alveoli [8], enter and multiplies itself inside the alveolar macrophage [9] without causing any damage to the phagocyte cell [10]; it can stay that way for a long period [11], as long as the host's cellular immune system is intact and well-function [12]. Spread to the brain is possible if the host experiences a definite reduction in the number of CD4 cells (<200 cells/ $\mu$ L) and this condition called CM.

Mycology laboratory Diagnosis of CM requires analysis of cerebrospinal fluid (CSF) as the clinical sample [13]; and required at least three simple but reliable technique namely direct examination using India ink [14], culture the sample [15], and CrAg testing [16].

Considering the importance and widely used India ink in *Cryptococcal's* CSF analysis across many laboratory, this paper aimed to revisited the application of India ink as a negative stain used to smear CSF of patient suspected infected with CM.

## 2. THE PRINCIPLES

Negative staining represents one of the simplest, reliable and speedilier procedures in case of specimen preparation [17], but unfortunately is limited in applications, including its tendency to diffuse and with only low to moderate sensitivity [18].

Negative staining is preferred for the observation of flawless microorganisms or other cell structures without disturbing its cellular morphology [19].

The procedure pertained to as negative staining which employs the use of an acidic stain, due to repulsion between the negative charges of the carbon particles inside the stain and the negative charge of microbial cell surface, and because of that repel the microorganism cells/portion are not stained at all [20], and rather coloring the glass background containing cells [21]. This approach authorizes the scrutinization of the configuration or contour of the organism as a clear bright object against a definite dark background [18-21]. By doing so, a more exact measurement of the size of microorganism or cell being analyzed is made possible [22]. Furthermore, in negative staining, heat fixation that may shrink the cell or organism being observed, or in other word can be change the dimension and integrity of the cell, is not employable [23]. The purpose of heat fixation is to bind the specimen to the glass surface of the slide and prevent significant loss during washing before the application of the dye [24]. Killing the cells or microorganism using heat fixation also improves their permeability to the dyes used in staining, as proven through study conducted by Chedore et al [25] on *Mycobacterium tuberculosis* smear. but unfortunately, heat might change the size and the form of the cell or microorganism being analyzed [23-25].

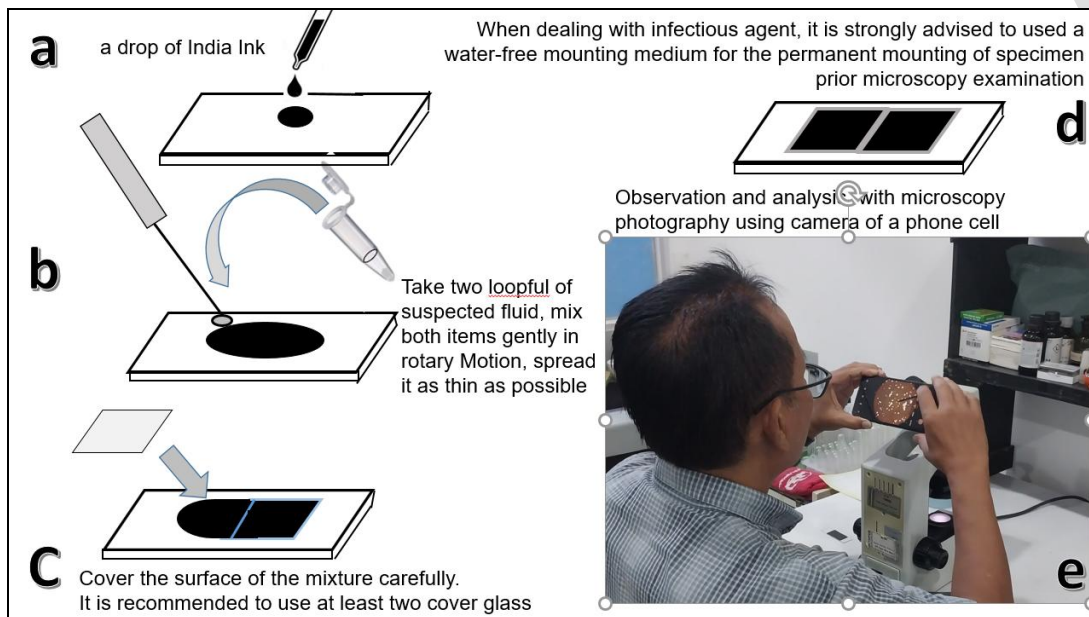


Fig. 1. India ink staining procedure of *C. neoformans*. (a) put a drop of India ink in clean surface of glass slide, (b) take 2 portion of the fluid being analyzed, mixed them both as gently as possible, spread it in rotary motion as thin as possible, (c) cover the surface of the mixture with cover glass, (d) cover and mount the cover glass with permanent mounting, (e) analyze under the microscope and make microscopy photography

Negative stain also offers some benefit, e.g., It is feasible to spot microorganisms that usually are strenuous to stain such as the spirilli [26]. Negative staining requires the use of acid stain such as the Indian ink or nigrosine [19,20,22]. The acid stain with its electronegative charged chromogenic dye cannot stain the cells due to its inability to penetrate the same electronegative charge cell wall on the whole exterior facet of the bacteria [19]. This indicates that the stain rapidly releases a proton ion and that the dye's chromophore acquires an electronegative charge.

The basic procedure involves the mixture of fluid being examined and transfer it as much as at least two loopfuls onto upper surface a grease free slide and then followed by the addition of a loopful of nigrosin dye. This is then followed by mixing both substance carefully in rotary motion, and the film is gently spread out as thin as possible toward both of the edges of the slide, However, keep in mind that there must be a small free area left, especially at the edge of the glass surface, to avoid the mixture spilling out over the edge of the glass object. After the desired area of mixture is achieved, the next step is to let the mixture to air dry slowly. The next step is to analyzed the target object under oil immersion objective lens of the microscope [27].

In case of India ink, it is actually a colloidal suspension of carbon black particles dispersed in a medium such as ethylene glycol that being stabilized by gum [28]. and is commonly used in pens for calligraphy writing, drawing, or skin tattooing where the chromogenic pigment of

the dye localized intracellularly in the epidermis and dermis, no matter it is a fresh or old tattoo [19]. India ink also has a long history of academic and clinical use as a histologic [30], gross anatomy [31] and even as marker for surgery [32] and radiotherapy [33]. Inadvertently, some of the India ink formulations contain carbon black particles which consists of stable radical species at sufficient concentrations that are sensitive to the presence of oxygen [34] and with their presence can affect (damaged or degradation) the composition of protein ingredients of subject being analyzed [35]. Despite the advantages for clinical applications, India ink has some limitations, including a tendency to diffuse [36] and only low to moderate sensitivity, which according to India ink's sensitivity is only 42% when the CSF Cryptococcus CFU value is <1,000 per ml of CSF [37]. As an effort to improve sensitivity rate, pre-examination centrifugation of suspected CSF in low speed for several minutes can likely make the sensitivity of microscopy examination become better [38].

### 3. APPROACH TO MAKING CORRECT DIAGNOSIS

Fluids based clinical sample actually can easily be processed directly prior the microscopy observation by directly mixing the pellet obtained by centrifugation fluids based clinical sample (CSF, pleural fluid, or Broncho alveolar lavage), with a drop of India ink [39].

The India ink stain is important in screening CSF samples of individuals which clinical symptoms under suspicion CM. When the test performed, positivity rate can reach up to 83% among positive patients (HIV infected individuals with clinically and laboratorally confirmed CM [18]. Unfortunately, false-positive results can occur, in other words whereas Indian ink stain is useful as a screening test [1-4,13,14, 18,21,38-42]. Luma et al [43] revealed that the confirmatory diagnosis of CM was only made when *C. neoformans* was identified in CSF by Indian ink stain. Perhaps this is the reason why it has a low confirmatory test value for CM in patients with HIV [42] and may lead to over-diagnosis of CM [41,42]. culture of a CSF sample is required to confirm the diagnosis [1-4,13,14, 18,21,38-43]. Sufficient amount of CSF (at least 12 mL) should be obtained [44] for conducting culture on at least three separated occasions (if possible) [45]. The aim is to increase the chance of isolating the yeast [40].

Direct microscopy of the CSF with the addition of a drop of India ink is the most rapid method for diagnosing CM [1-4,13,14, 18,21,38-42]. Positive result revealed a characteristics yeast with capsule that appeared as halo surrounding globular encapsulated yeast cell ranging from 4-6  $\mu\text{m}$ , with or without budding, and the thickness of its capsule varied, it can reach up to 30  $\mu\text{m}$  [1]. The sensitivity of India ink microscopy is 80% in HIV-positive patients but is reduced to only 30-50% in HIV negative patients [46].

Theoretically, the dye must always be diluted 1:3 with physiological saline solution for the Cryptococcus's cell observation. Put first India ink on the slide to prevent contamination of it by CSF. Cryptococcus is best detected in centrifugation sediment.

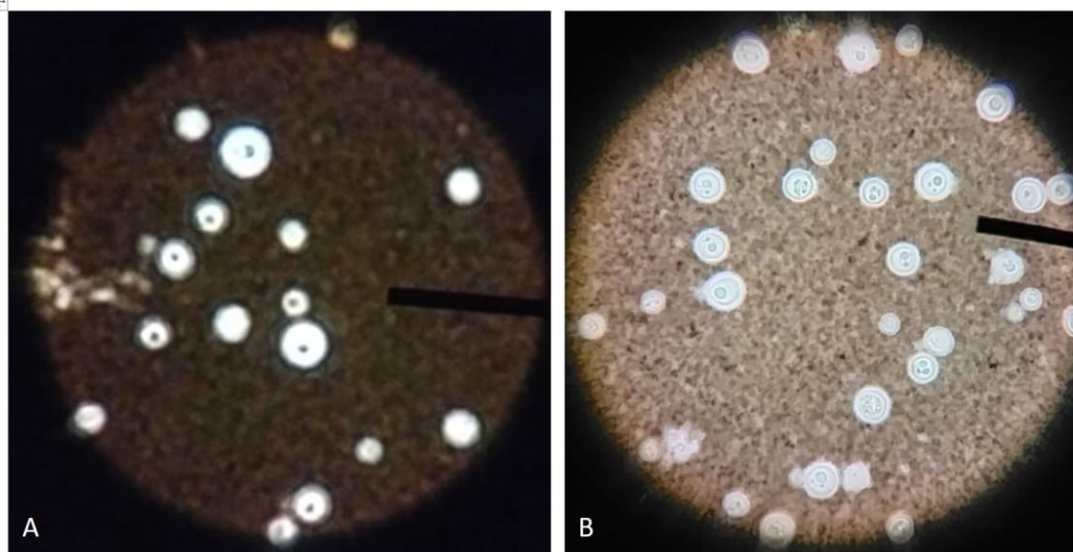


Fig 1. Encapsulated yeast of *C. neoformans* (45x objective magnification, light microscope Olympus CX 21) from environmental sample which has been preserved with glycerol 10% in  $-20^{\circ}\text{C}$ . (A) ratio of mixture India ink : glycerol = 1:2, (B) ratio of mixture India ink :

glyceryn = 1:5. (All sample and tools are courtesy of dept. of Parasitology, faculty of Medicine, Universitas Kristen Indonesia, Jakarta-Indonesia.)

### **3.1 MODIFICATION**

A novel modified India ink technique for the diagnosis of *C. neoformans* in cerebrospinal fluid specimens is described elsewhere [47]. This modification uses addition of 2% chromium mercury to the main dye India ink. According to Zerpa et al [47], three layers from the outer capsule that have previously been discerned only by electron microscopy are distinguished. This novel preparation mimics a polychromatic preparation, even though no color stains were used during the procedure. This seemingly polychromatic presentation [48] of *C. neoformans* allowed the distinction of microscopic air bubbles that sometimes are mistaken for *C. neoformans* when the conventional India ink preparation method is use.

Other modification conducted by Ibembe and Wiggin [49] in Uganda where getting India ink in rural part of Uganda is strenuous and extravagant. In order to accommodate the need to stain suspected clinical sample of CM, an alternative stain method was sought to assist in mycology diagnoses of CM in immunosuppressed individuals. Mascara, a cosmetic dye for coloring eyelashes, e.g., darkening and thickening, proved to be an excellent and cheap alternative for India ink, in the context of microscopic identification of Cryptococcus in CSF [49]. Continuous search and modification efforts to provide better negative staining that are effective, efficient and more reliable are still being carried out considering that CM cases continue to increase in the community and detection as early as possible is one of the efforts so that this problem can be controlled.

### **3.2 CHALLENGE IN MAKING CORRECT DIAGNOSIS WITH INDIA INK STAINING**

India ink microscopy has historically been a quick, low-resource method to detect Cryptococcus in the CSF [50]. it can be used for examining the structure of a wide range of living micro-organisms, e.g., yeast [1-4,13,14, 18,21,38-43] or bacteria [51]. To be effective for this purpose, an ink should have very nanoscopic size [52], must always be consistent in sized particles entirely [53], should spread evenly and should not coagulate too readily. Though it does coagulate to some extent in acidic suspensions. The ink properties itself can become a challenge in making correct diagnosis of CM.

Such as efforts to diagnose other diseases based on a combination of the results of anamnesis, physical examination and supporting examinations; making correct diagnosis of CM among HIV (+) individuals using India ink also give some obstacle, such as (1) too little number of yeast in the clinical sample, (2) unable to determine viability and (3) still consider infectious.

Previous report revealed that India ink have a lower sensitivity rate compared to Gram stain and demands greater levels of expertise than the Gram stain [18]. Other marking dye also compared with Indian ink [54]. More in depth study must be conducted in order to achieve better staining technique.

## **4. CONCLUSION**

The India ink stain is still considered important in screening CSF samples of patients with suspected CM. It is easy, effective, efficient and reliable, with sensitivity can still be improved with centrifugation of the CSF. Modification of techniques might also improve the sensitivity.

### **CONSENT (WHERE EVER APPLICABLE)**

Not needed

### **ETHICAL APPROVAL (WHERE EVER APPLICABLE)**

Not needed

## **REFERENCES**

1. Ruschel MAP, Thapa B. Cryptococcus Meningitis. [Updated 2023 Aug 8]. In: StatPearls [Internet]. Treasure Island (FL): StatPearls Publishing; 2024 Jan-. Available from: <https://www.ncbi.nlm.nih.gov/books/NBK525986/>

2. Okurut S, Boulware DR, Olobo J, Meya DB. Landmark clinical observations and immunopathogenesis pathways linked to HIV and Cryptococcus fatal central nervous system co-infection. *Mycoses*. 2020 Aug;63(8):840-853. <https://doi.org/10.1111/myc.13122>.
3. Tu A, Byard RW. Cryptococcosis and unexpected death. *Forensic Sci Med Pathol*. 2021 Dec;17(4):742-745. <https://doi.org/10.1007/s12024-021-00400-1>.
4. McHale TC, Boulware DR, Kasibante J, Ssebambulidde K, Skipper CP, Abassi M. 2023. Diagnosis and management of cryptococcal meningitis in HIV-infected adults. *Clin Microbiol Rev* 36:e00156-22. <https://doi.org/10.1128/cmr.00156-22>
5. Cafarchia C, Romito D, Iatta R, Camarda A, Montagna MT, Otranto D. Role of birds of prey as carriers and spreaders of *Cryptococcus neoformans* and other zoonotic yeasts. *Med Mycol*. 2006 Sep;44(6):485-92. <https://doi.org/10.1080/13693780600735452>.
6. Randhawa HS, Mussa AY, Khan ZU. Decaying wood in tree trunk hollows as a natural substrate for *Cryptococcus neoformans* and other yeast-like fungi of clinical interest. *Mycopathologia*. 2001;151(2):63-9. <https://doi.org/10.1023/a:1010906220888>.
7. Stempinski PR, Gerbig GR, Greengo SD, Casadevall A. Last but not yeast-The many forms of *Cryptococcus neoformans*. *PLoS Pathog*. 2023 Jan 5;19(1):e1011048. <https://doi.org/10.1371/journal.ppat.1011048>.
8. Denham ST, Brown JCS. Mechanisms of Pulmonary Escape and Dissemination by *Cryptococcus neoformans*. *J Fungi (Basel)*. 2018 Feb 17;4(1):25. <https://doi.org/10.3390/jof4010025>.
9. Wang Y, Pawar S, Dutta O, Wang K, Rivera A, Xue C. Macrophage Mediated Immunomodulation During *Cryptococcus* Pulmonary Infection. *Front Cell Infect Microbiol*. 2022 Mar 24;12:859049. <https://doi.org/10.3389/fcimb.2022.859049>.
10. de Castro RJA, Marina CL, Sturny-Leclère A, Hoffmann C, Bürgel PH, Wong SSW, et al. Kicking sleepers out of bed: Macrophages promote reactivation of dormant *Cryptococcus neoformans* by extracellular vesicle release and non-lytic exocytosis. *PLoS Pathog*. 2023 Nov 30;19(11):e1011841. <https://doi.org/10.1371/journal.ppat.1011841>.
11. Alanio A. Dormancy in *Cryptococcus neoformans*: 60 years of accumulating evidence. *J Clin Invest*. 2020 Jul 1;130(7):3353-3360. <https://doi.org/10.1172/JCI136223>.
12. Yang C, Huang Y, Zhou Y, Zang X, Deng H, Liu Y, Shen D, Xue X. *Cryptococcus* escapes host immunity: What do we know? *Front Cell Infect Microbiol*. 2022 Oct 13;12:1041036. <https://doi.org/10.3389/fcimb.2022.1041036>.
13. Benedict K, Gold JAW, Dietz S, Anjum S, Williamson PR, Jackson BR. Testing for Cryptococcosis at a Major Commercial Laboratory-United States, 2019-2021. *Open Forum Infect Dis*. 2022 May 16;9(7):ofac253. <https://doi.org/10.1093/ofid/ofac253>.
14. Pfennig CL, Brown B. Cerebrospinal Fluid Examination—India Ink Preparation for *Cryptococcus Neoformans*. In: Knoop KJ, Stack LB, Storrow AB, Thurman R. eds. *The Atlas of Emergency Medicine*, 5e. McGraw-Hill; 2021. <https://accessmergencymedicine.mhmedical.com/content.aspx?bookid=2969&sectionid=250464413>
15. AL-Zubaidy IMK, Shabaa RAH. Evaluation the efficacy of some culture media in melanin production by *Cryptococcus neoformans*. *Materials Today: Proceedings*, 2023; 80 (3):3167-3170, ISSN 2214-7853. <https://doi.org/10.1016/j.matpr.2021.07.184>.
16. Vidal JE, Boulware DR. Lateral Flow Assay for *Cryptococcus* Antigen: an Important Advance To Improve The Continuum of HIV Care and Reduce *Cryptococcus* Meningitis-Related Mortality. *Rev Inst Med Trop Sao Paulo*. 2015 Sep;57 Suppl 19(Suppl 19):38-45. <https://doi.org/10.1590/S0036-46652015000700008>.
17. Holgate JH, Webb J. MICROSCOPY | Transmission Electron Microscopy. Ed(s): Caballero B. *Encyclopedia of Food Sciences and Nutrition (Second Edition)*. Academic Press, 2003,Pp 3928-3934, ISBN 9780122270550. <https://doi.org/10.1016/B0-12-227055-X/00780-X>.
18. Coovadia YMC, Mahomed S, Dorasamy A, Chang C. A comparative evaluation of the Gram stain and India ink stain for the rapid diagnosis of cryptococcal meningitis in HIV infected patients in Durban, Southern African. *Journal of Infectious Diseases*, 2015; 30:2, 61-63, <https://doi.org/10.1080/23120053.2015.1054199>
19. Suryowati T. Biochemical aspects of cell staining. *Asian Journal of Research in Biochemistry*. 2024; 14 (3): 61-71, <https://doi.org/10.9734/AJRB/2024/v14i3288>
20. Moyes RB, Reynolds J, Breakwell DP. Preliminary staining of bacteria: negative stain. *Curr Protoc Microbiol*. 2009 Nov;Appendix 3:Appendix 3F. <https://doi.org/10.1002/9780471729259.mca03fs15>.
21. Hughes RB, Smith AC. Capsule Stain Protocols. American Society for Microbiology. 29 September 2007. <https://asm.org/ASM/media/Protocol-Images/Capsule-Stain-Protocols.pdf?ext=.pdf>
22. Droste MS, Biel SS, Terstegen L, Wittern KP, Wenck H, Wepf R. Noninvasive measurement of cell volume changes by negative staining. *J Biomed Opt*. 2005 Nov-Dec;10(6):064017. <https://doi.org/10.1117/1.2138011>.

23. Zhu L, Rajendram M, Huang KC. Effects of fixation on bacterial cellular dimensions and integrity. *iScience*. 2021 Mar 22;24(4):102348. <https://doi.org/10.1016/j.isci.2021.102348>.
24. Tripathi N, Sapra A. Gram Staining. [Updated 2023 Aug 14]. In: StatPearls [Internet]. Treasure Island (FL): StatPearls Publishing; 2024 Jan-. Available from: <https://www.ncbi.nlm.nih.gov/books/NBK562156/>
25. Chedore P, Th'ng C, Nolan DH, Churchwell GM, Sieffert DE, Hale YM, Jamieson F. Method for inactivating and fixing unstained smear preparations of mycobacterium tuberculosis for improved laboratory safety. *J Clin Microbiol*. 2002 Nov;40(11):4077-80. <https://doi.org/10.1128/JCM.40.11.4077-4080.2002>.
26. Petersen J, McLaughlin S. *Laboratory Exercises in Microbiology: Discovering the Unseen World Through Hands-On Investigation*. City University of New York (CUNY)- CUNY Academic Works. CUNY Queensborough Community College. 2016. [https://academicworks.cuny.edu/cgi/viewcontent.cgi?article=1015&context=qb\\_oers](https://academicworks.cuny.edu/cgi/viewcontent.cgi?article=1015&context=qb_oers)
27. Ogodo AC, Narayana MSSV, Vardhan PS, Gupta RK, Gautam AK, Egbuna C, Kushwaha PP, Singh AK, Kumar S. Chapter 9 - Principles of applied microbiology and biotechnology: Technique for the screening of antimicrobial herbs. Ed(s): Egbuna C, Mishra AP, Goyal MR. *Preparation of Phytopharmaceuticals for the Management of Disorders*. Academic Press. 2021. pp 185-214. ISBN 9780128202845. <https://doi.org/10.1016/B978-0-12-820284-5.00001-0>.
28. Schramm LL. *Emulsions, Foams, and Suspensions: Fundamentals and Applications*. Wiley VCH-Verlag- GmbH & Co KgaA. 2005. Weinheim. <http://repository.ottimmo.ac.id/41/1/Emulsions%2C%20Foams%2C%20and%20Suspensions%20-%20Fundamentals%20and%20Applications.pdf>
29. Kröger M, Schleusener J, Lademann J, Meinke MC, Jung S, Darvin ME. Tattoo Pigments Are Localized Intracellularly in the Epidermis and Dermis of Fresh and Old Tattoos: In vivo Study Using Two-Photon Excited Fluorescence Lifetime Imaging. *Dermatology*. 2023;239(3):478-493. <https://doi.org/10.1159/000529577>.
30. Boezaart A, Sala-Blanch X, Monzo E, Reina MA. India ink: a time-tested histological marker. *Reg Anesth Pain Med*. 2019 Apr 16;rapm-2019-100553. <https://doi.org/10.1136/rapm-2019-100553>.
31. Kizhakkottu S, Jayaraj G, Herald J S, Don KR, Santhanam A. Inking of gross specimens: a systematic review. *Russian Journal of Archive of Pathology*. 2021;83(1):49- 52. (In Russ., In Engl.) <https://doi.org/10.17116/patol20218301149>
32. Patil A, Anand R, Mahajan PG. Comparative Study of Acrylic Color and India Ink for Their Use as a Surgical Margin Inks in Oral Squamous Cell Carcinoma. *World Journal of Dentistry*, 2015;6: 26-30.
33. Rathod S, Munshi A, Agarwal J. Skin markings methods and guidelines: A reality in image guidance radiotherapy era. *South Asian J Cancer*. 2012 Jul;1(1):27-9. <https://doi.org/10.4103/2278-330X.96502>.
34. Khan N, Hou H, Swartz H, Kuppusamy P. Direct and Repeated Measurement of Heart and Brain Oxygenation Using In Vivo EPR Oximetry. Qin PZ, Warncke K (eds). book: *Electron Paramagnetic Resonance Investigations of Biological Systems by Using Spin Labels, Spin Probes, and Intrinsic Metal Ions, Part B*. Academic Press. 2015. <https://doi.org/10.1016/bs.mie.2015.06.023>.
35. Davies KJ. Protein damage and degradation by oxygen radicals. I. general aspects. *J Biol Chem*. 1987 Jul 15;262(20):9895-901.
36. Shahin A, Bachir W, El-daher MS. Optical properties in the visible range of two different India ink used as biological phantoms. *The European Physical Journal Applied Physics*. 2020; 93(1): 10502. <https://doi.org/10.1051/epjap/2020200234>
37. Boulware DR, Rolfes MA, Rajasingham R, von Hohenberg M, Qin Z, Taseera K, Schutz C, Kwizera R, Butler EK, Meintjes G, Muzoora C, Bischof JC, Meya DB. 2014. Multisite validation of cryptococcal antigen lateral flow assay and quantification by laser thermal contrast. *Emerg Infect Dis* 20:45–53. <https://doi.org/10.3201/eid2001.130906>.
38. McHugh KE, Gersey M, Rhoads DD, Procop GW, Zhang Y, Booth CN, Sturgis CD. Sensitivity of Cerebrospinal Fluid Cytology for the Diagnosis of Cryptococcus Infections: A 21-Year Single-Institution Retrospective Review, *American Journal of Clinical Pathology*, 2019; 151(2):198–204, <https://doi.org/10.1093/ajcp/aqy133>
39. Chammard TB, Lanternier F, Lortholary O. 89 – Cryptococcosis. Ed(s): Ryan ET, Hill DR, Solomon S, Aronson NE, Endy TP. *Hunter's Tropical Medicine and Emerging Infectious Diseases (Tenth Edition)*. Elsevier. 2020. pp 678-681. ISBN 9780323555128. <https://doi.org/10.1016/B978-0-323-55512-8.00089-2>.
40. Yogev R. CHAPTER 43 - Chronic Meningitis. Ed(s): Sarah S. Long. *Principles and Practice of Pediatric Infectious Disease (Third Edition)*. W.B. Saunders. 2008. pp 291-299, ISBN 9780702034688. <https://doi.org/10.1016/B978-0-7020-3468-8.50049-3>.
41. Soni ZJ, Reubenson G, De Maayer T, Coovadia A, Lazarus EM. Neonatal Cryptococcosis: Beware of False-positive Results, *Journal of the Pediatric Infectious Diseases Society*. 2012; 1(3):250–253, <https://doi.org/10.1093/jpids/pis037>

42. Gomerepa SS, Isaa SE, Obasekib DO, Badung BP. Badung Accuracy of Indian ink staining in diagnosis of cryptococcal meningitis in HIV infection in Jos, Nigeria. The Royal Society of Chemistry. Downloaded from [https://www.google.com/search?q=Accuracy+of+Indian+ink+staining+in+diagnosis+of+cryptococcal&og=Accuracy+of+Indian+ink+staining+in+diagnosis+of+cryptococcal&gs\\_lcrp=EgZjaHJvbWUyBggAEEUYOTIHCAEQIRigATI HCAIQIRigAdIBBzk1NWowajeoAgCwAgA&sourceid=chrome&ie=UTF-8](https://www.google.com/search?q=Accuracy+of+Indian+ink+staining+in+diagnosis+of+cryptococcal&og=Accuracy+of+Indian+ink+staining+in+diagnosis+of+cryptococcal&gs_lcrp=EgZjaHJvbWUyBggAEEUYOTIHCAEQIRigATI HCAIQIRigAdIBBzk1NWowajeoAgCwAgA&sourceid=chrome&ie=UTF-8)
43. Luma HN, Temfack E, Halle MP, Tchaleu BC, Mapoure YN, Koulla-Shiro S. Cryptococcus meningoencephalitis in human immunodeficiency virus/acquired immunodeficiency syndrome in douala, cameroon: a cross sectional study. *N Am J Med Sci*. 2013 Aug;5(8):486-91. <https://doi.org/10.4103/1947-2714.117318>.
44. Teunissen CE, Petzold A, Bennett JL, Berven FS, Brundin L, Comabella M, et al. A consensus protocol for the standardization of cerebrospinal fluid collection and biobanking. *Neurology*. 2009 Dec 1;73(22):1914-22. <https://doi.org/10.1212/WNL.0b013e3181c47cc2>.
45. Gangadharan SS, Raveendranath S. Cryptococcosis in oncology patients: a case series in a tertiary care cancer centre. *Iran J Microbiol*. 2023 Dec;15(6):821-825. <https://doi.org/10.18502/ijm.v15i6.14163>.
46. Le T. 45 - Systemic Mycoses, Ed(s): Farrar J, Garcia P, Hotez P, Junghanss T, Kang G, Laloo D, White N. *Manson's Tropical Diseases (Twenty-Fourth Edition)*. Elsevier. 2024. pp 495-509. ISBN 9780702079597. <https://doi.org/10.1016/B978-0-7020-7959-7.00045-2>.
47. Zepa R, Huicho L, Guillén A. Modified India Ink Preparation for Cryptococcus neoformans in Cerebrospinal Fluid Specimens. *J Clin Microbiol*. 1996 Sep;34(9):2290-1. <https://doi.org/10.1128/JCM.34.9.2290-2291.1996>
48. Morikawa S, Sato A, Ezaki T. A simple, one-step polychromatic staining method for epoxy-embedded semithin tissue sections. *Microscopy*. 2018; 67 (6): 331–344, <https://doi.org/10.1093/jmicro/dfy037>
49. Ibembe IN, Wiggin TR. An Alternative To India Ink Stain. *Trop Doct*. 2015 JUL;45(3):206-7. <https://doi.org/10.1177/0049475515587821>
50. Kambugu A, Meya DB, Rhein J, O'Brien M, Janoff EN, Ronald AR, et al. Outcomes of cryptococcal meningitis in Uganda before and after the availability of highly active antiretroviral therapy. *Clin Infect Dis*, 2008; 46:1694–1701. <https://doi.org/10.1086/587667>.
51. Melly MA, McGee ZA, Horn RG, Morris F, Glick AD. An electron microscopic India ink technique for demonstrating capsules on microorganisms: studies with *Streptococcus pneumoniae*, *Staphylococcus aureus*, and *Neisseria gonorrhoeae*. *J Infect Dis*. 1979 Oct;140(4):605-9. <https://doi.org/10.1093/infdis/140.4.605>.
52. Yoshikawa M, Noguchi K, Toda T. Effect of particle sizes in India ink on its use in evaluation of apical seal. *J Osaka Dent Univ*. 1997 Dec;31(1-2):67-70.
53. Mizutani H, Akeda T, Yamanaka K, Isoda K, Gabazza EC. Single step modified ink staining for Tzanck test: quick detection of herpetic giant cells in Tzanck smear. *J Dermatol*. 2012 Feb;39(2):138-40. <https://doi.org/10.1111/j.1346-8138.2011.01335.x>.
54. Kosemehmetoglu K, Guner G, Ates D. Indian ink vs tissue marking dye: a quantitative comparison of two widely used macroscopical staining tool. *Virchows Arch*. 2010 Jul;457(1):21-5. <https://doi.org/10.1007/s00428-010-0941-5>.