

Ileocecal intussusception caused by appendiceal mucinous neoplasm

ABSTRACT.

Aims: To present an unusual case and our therapeutic approach about a clinical case of ileocecal intussusception caused by appendiceal mucinous neoplasm.

Presentation of Case: A 54-year-old female patient came to the emergency department with abdominal pain. Complementary diagnostic exams showed an image of ileocolic invagination due to an appendicular mass, confirmed intraoperatively. A right hemicolectomy was performed for oncological purposes. The anatomopathological study revealed a low-grade appendicular mucinous neoplasm.

Discussion and Conclusion: Ileocecal intussusception is a rare diagnosis in adults, 80-92% of cases are secondary to an underlying pathology, usually identified intraoperatively. The treatment is surgical, due to the high incidence of a malignant etiology. In this particular case, there was already a preoperative suspicion of an appendicular neoplasm, which justified proposing a right hemicolectomy. There is no general consensus on the post-operative monitoring of Low-Grade Appendiceal Mucinous Neoplasm (LAMN). In this case, the follow up was an analytical study with tumor markers, computed tomography and colonoscopy. After 5 years, the patient was asymptomatic, with no signs of recurrence.

Keywords: Ileocecal intussusception; Ileocecal appendix; Mucinous neoplasm

Introduction

Mucinous appendiceal neoplasm occurs in less than 1% of appendicectomies. Majority of what is known in the literature is about pseudomyxoma peritonei, which exists as its disseminated form. Pictorial imagery of its pre-disseminated form is rarely observed [7]. A contrast enhanced computed tomography scan of the abdomen revealed an ileo-colic intussusception. He underwent a laparoscopic quarter colectomy with ileo-colic anastomosis followed by an uneventful post-operative recovery [8]. The aim of this work is to present an unusual case and our therapeutic approach about a clinical case of ileocecal intussusception caused by appendiceal mucinous neoplasm.

1. PRESENTATION OF CASE:

A 54-year-old female patient came to the emergency department with abdominal distension and diffuse pain, more intense in the right lower quadrant, constant, progressively worsening for 4 days, without spreading, worsening or relieving factors. She denied any other symptoms. Objectively, the patient was tall and thin, had a painful mass on both superficial and deep palpation in the right lower quadrant, with a hard-elastic consistency and no signs of peritoneal irritation.

The analytical study revealed no alterations. The abdominopelvic ultrasound showed: 'an anomalous expansive process, mostly liquid, heterogeneous, roughly oval, measuring 3x3x7.5 cm, within several intestinal loops, mostly small, which are paretic. The structure described may correspond to a long inflamed caecal appendix'. Computed Tomography (CT) describes: "an image suggestive of ileocolic intestinal invagination, with a 3.5 cm hypodense nodular morphology at the end of the intussusceptum and parietal calcification (appendicular mucocele? carcinoid?). There was also marked distension of the ileal loops (figure 1).

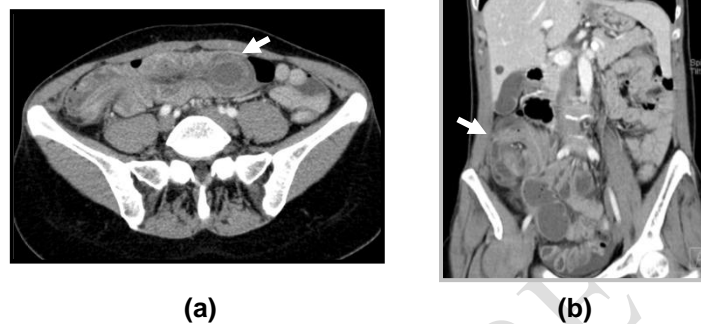


Figure 1 – Ileocecal intussusception - **(a)** axial and **(b)** coronal sections

Exploratory laparotomy was proposed, which the patient accepted. Intraoperatively, ileocolic invagination with a possible appendicular tumor was confirmed (figure 2). Formal right hemicolectomy was performed, with oncological intent (figure 3).

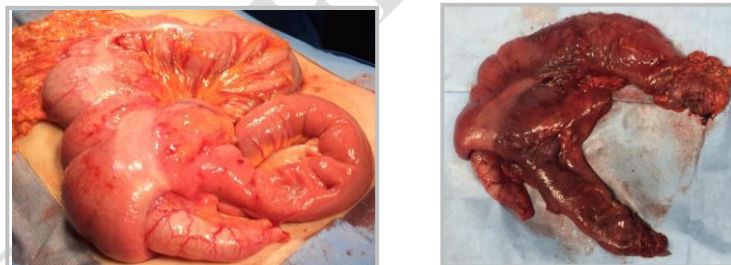

Figure 2: Ileocolic intussusception **Figure 3:** Operative specimen

The anatomopathological study revealed: low-grade appendicular mucinous neoplasm (LAMN) pTisN0R0 (8th AJCC edition) with no signs of wall rupture and no lymphatic, venous or perineural vascular invasion. The distance to proximal end 12cm and to distal 19cm. The 16 isolated lymph nodes were negative to malignant disease.

The patient had a favorable evolution and was discharged at 5th postoperative day.

The clinical case was presented at a multidisciplinary meeting and it was decided to maintain clinical surveillance.

During the 5 years follow-up, the patient was always asymptomatic, with no signs of recurrence. She did physical examination and tumor markers (CEA, CA 19.9 and CA 72.4) testing every 6 months, chest, abdominal and pelvic computed tomography (CT) scan each year and colonoscopy 1 and 5 years after surgery.

2. DISCUSSION AND CONCLUSION:

Both intussusception and LAMN present with non-specific symptoms and require a high level of suspicion. The high sensitivity and specificity of imaging tests have contributed to increase the preoperative diagnosis. The CT is the *gold standard*¹.

Even so, the diagnosis of intussusception is often intraoperative and LAMN appears only in the anatomopathological study. The average age at diagnosis is around 50-53 years, and both entities predominate in females.

The presence of LAMN in an intact ileocecal appendix, with no other risk factors, is considered benign, with a very low risk of progression to pseudomyxoma peritonei. When pathology shows negative margins and if there are negative tumor markers (CEA, CA-19.9 and CA-125), patients have a 95.2% recurrence free survival at five years and 100% overall survival^{2,3,4,5}.

The treatment of intussusception in adults is surgical, mostly because of the high risk of underlying malignancy¹.

In this particular case, a right hemicolectomy was performed in order to assure free tumor margins, due to the preoperative suspicion of a neoplastic process. Given the emergency context, tumor markers were not ordered.

There is no general consensus on the postoperative surveillance of LAMN, due to the lack of standardized methods based on diagnostic criteria⁶.

In this case, the follow up was physical examination and tumor markers (CEA, CA 19.9 and CA 72.4) testing every 6 months, chest, abdominal and pelvic computed tomography (CT) scan each year and colonoscopy 1 and 5 years after surgery. After 5 years, the patient was asymptomatic, with no signs of recurrence.

In conclusion, despite the sensitivity and specificity of the most recent imaging tests, a preoperative diagnosis of certainty is not always possible. The hypothesis of malignant etiology should always be considered in cases of intussusception, tailoring the procedure to this suspicion, with safe resection margins and lymphadenectomy.

REFERENCES

1. Gupta RK, Agrawal CS, Yadav R, Bajracharya A, Sah PL. Intussusception in adults: institutional review. *Int J Surg*. 2011;9(1):91-95.
2. Legué LM, Creemers GJ, de Hingh IHJT, Lemmens VEPP, Huysentruyt CJ. Review: Pathology and Its Clinical Relevance of Mucinous Appendiceal Neoplasms and Pseudomyxoma Peritonei. *Clin Colorectal Cancer*. 2019;18(1):1-7
3. Fournier K, Rafeeq S, Taggart M, et al. Low-grade Appendiceal Mucinous Neoplasm of Uncertain Malignant Potential (LAMN-UMP): Prognostic Factors and Implications for Treatment and Follow-up. *Ann Surg Oncol*. 2017;24(1):187-193.
4. Fournier K, Rafeeq S, Taggart M, et al. Low-grade Appendiceal Mucinous Neoplasm of Uncertain Malignant Potential (LAMN-UMP): Prognostic Factors and Implications for Treatment and Follow-up. *Ann Surg Oncol*. 2017;24(1):187-193.
5. Xiao J, Li P, Liu W. Analysis of Clinical Characteristics of Low-Grade Appendiceal Mucinous Neoplasm (LAMN): A Retrospective Cohort Study of 51 LAMN Patients [published online ahead of print, 2020 Jan 6]. *J Invest Surg*. 2020;1-7.
6. Koç C, Akbulut S, Akatlı AN, Türkmen Şamdancı E, Tuncer A, Yılmaz S. Nomenclature of appendiceal mucinous lesions according to the 2019 WHO Classification of Tumors of the Digestive System. *Turk J Gastroenterol*. 2020 Sep;31(9):649-657.
7. Chua TC, Gill P, Gill AJ, Samra JS. Ileocecal intussusception caused by an appendiceal neoplasm. *Journal of Gastrointestinal Surgery*. 2016 Apr;20:867-8.

8. Harvitkar RU, Joshi A. A Rare Case of Low-grade Appendicular Mucinous Neoplasm Presenting as Ileocolic Intussusception. Indian Journal of Surgery. 2022 Apr;84(2):395-7.

UNDER PEER REVIEW