

# REVIEW OF THE LITERATURE ON PAIN IN HORSES DURING COLIC: Understanding visceral abdominal pain for the right therapeutic choice

---

## ABSTRACT

**Aims:** Pain is one of the most dreaded signs of colic in horses. The aim of this work is to facilitate understanding of the pathophysiology of this pain in order to improve therapeutic choices in equine clinics.

**Methodology:** The study was a retrospective survey in the Dakar and Thiès regions, involving direct interviews with 540 horse owners and users between February 2023 and October 2023.

**Results:** Knowledge of the pathophysiology and consequences of pain allows us to better understand the mechanisms by which it occurs and its classification according to severity. In this way, the management of a horse suffering from colic will be easier and more appropriate, by anticipating the deterioration in the animal's general condition and avoiding the side effects of the molecules to be used.

**Conclusion:** Knowledge of the anatomy, physiology and innervation of the digestive tract will enable you to deal more effectively with algology during colic: understanding the pathophysiology, management of visceral pain during equine colic and well-being of horses.

*Keywords: Retrospective- survey - traditional -gesture - practices – horse - colic – Senegal*

## 1. INTRODUCTION

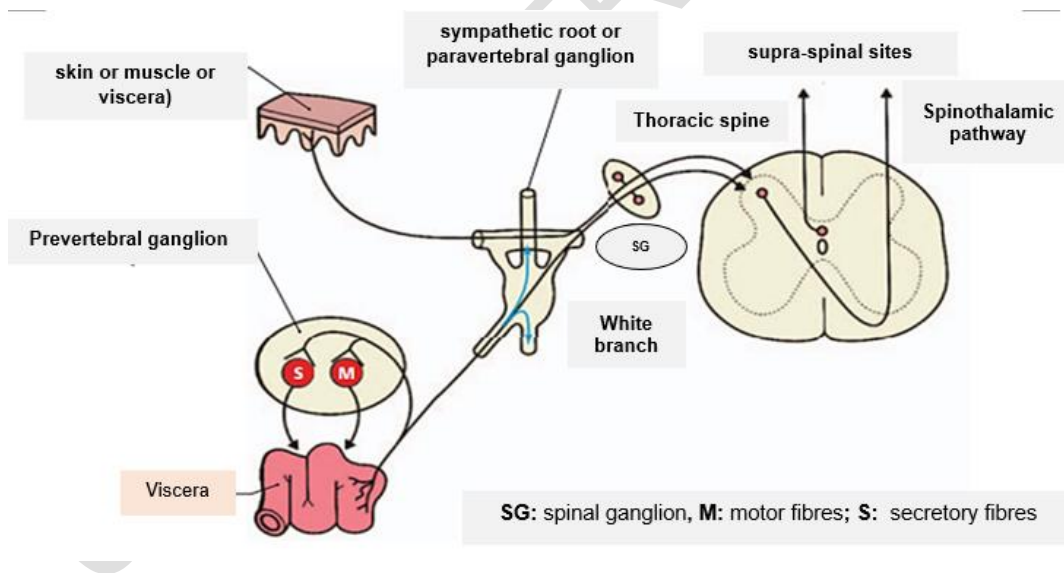
In horses, colic is a painful attack of the abdomen, manifested by stereotyped symptoms also known as "acute abdominal pain" (EL MESSAOUDI et al. 2006). Acute abdominal pain covers a range of symptoms, but refers specifically to pain of abdominal origin, the causes of which are multiple and most frequently of digestive origin (CIRIER, 2010; CHABCHOUB, 2007). They are recognised as the leading cause of mortality in horses (JULLIAND and GENAIN, 2011) and one of the most frequent reasons for consultation in equine clinics (MAIR et al. 1997).

The harmful clinical consequences and the impact of pain on the well-being of a sick horse mean that appropriate and rapid treatment is required (GUEZENNEC, 2006). The aim of treatment in the field is to eliminate this pain, or at least to reduce it (WHITE, 1990). Nociceptive stimulation during colic and its consequences makes analgesia the key stage in the treatment of colicky horses, and requires an understanding of visceral motricity and pain in order to make the best therapeutic choices (DRENDEL, 2009).

## 2. ABDOMINAL VISCERAL PAIN: ORIGIN (ANATOMIC AND PHYSIOLOGY), CONSEQUENCE AND LEVELS

- *Anatomic: Visceral sensory innervation (BIELEFELDT and GEBHART, 2006)*

A particular feature of visceral pain is the dual innervation provided by the parasympathetic system (vagus nerve in particular, but also pelvic nerves for the lower part of the body) and by spinal afferent fibres which pass through the sympathetic system. The innervation of the transverse colon, for example, includes vagal afferent fibres (from a local ganglion to the nucleus of the solitary fasciculus) and splanchnic nerves (or viscerosensory axons) from the T5 to L2 medullary roots. These fibres are polymodal, meaning that they are chemo-, thermo- and mechano-sensitive. A sensitisation phenomenon may develop after an injury; in addition, some nociceptors are "silent", i.e. they are insensitive to stimuli in physiological situations. Nociceptive afferent fibres terminate in layers I, II, V and X of the medulla, with visceral afferents accounting for around 10% of all nerve fibres at this level (Figure 1). The central ascending pathways are via the spinothalamic, spinohypothalamic, spinosolitary and spinoreticular bundles and, unlike the somatic pathway, via the posterior cords of the spinal cord. Pain receptors are unevenly distributed throughout the body. They are numerous in areas exposed to tissue damage, such as the skin, muscles, tendons and joints. They are also abundant in the digestive tract. Substance P (an 11 amino acid protein) is the main neuromodulator involved in the transmission of the nociceptive stimulus. There are two classes of visceral nociceptors: those with a low activation threshold (70%) found in the stomach, colon and bladder, and those with a high activation threshold (30%) found in the ureter, kidneys, lungs and heart (BIELEFELDT and GEBHART, 2006).



**Figure 1: Study area map**

- *Physiology of abdominal visceral pain*

Abdominal pain is caused by the stimulation of intra-abdominal nociceptive receptors or nociceptors, which create a nociceptive message that travels up the pain pathway to the brain via the spinal cord. These receptors are found in the wall (lamina propria and muscularis) of hollow organs, in the serosa (peritoneum and capsule of parenchymal organs) and in the

mesentery. They respond to a mechanical stimulus such as (i) significant gastrointestinal distension, (ii) contraction of the muscular portion of the intestinal wall (the pain will be even more intense if the muscles cannot shorten, as in the case of obstruction), (iii) traction or compression of the blood vessels and mesentery, (iv) torsion and stretching causing sudden anoxia of the visceral muscles (e.g. during volvulus), and (v) gastric, intestinal or peritoneal inflammation (MONTRÉAL, 2018). They are also stimulated by inflammatory substances such as bradykinins, substance P, serotonin, histamine and prostaglandins. The density of these receptors is much lower, for example, than in the skin. This explains why the response to localised stimuli, such as an incision, a pinch or a localised burn is weak, and why visceral pain is perceived as dull, diffuse and difficult to localise (ROBERTSON and SANCHEZ, 2010). These particularities help to explain the severe pain caused by gaseous distension of the colon, for example, and the animals' tolerance to transrectal palpation or laparoscopic surgery on a standing horse.

- *Consequences of visceral pain in horses*

Although it has not been fully studied or demonstrated in horses, it is accepted that pain causes an organic stress reaction with neuroendocrine and immunological consequences that have a harmful impact on healing, the occurrence of complications, the duration of treatment and, particularly for the digestive tract, the resumption of transit (ANDREWS et al., 2005; ARNAULD DES LIONS, 2002). Pain inhibits digestive transit by activating a spinal reflex which induces orthosympathetic hyperactivity (SELLON, 2007). Furthermore, if visceral pain is treated inadequately, too late or for too short a period, it is feared that hypersensitivity of the pain pathways may develop, leading to a chronic hyperalgesic state, with potentially disastrous consequences for the animal's well-being and therefore its quality of life, temperament and performance (TOUZOT-JOURDE, 2012).

The harmful clinical consequences of pain mean that it is considered to be a pathological process that warrants treatment. Nociceptive stimulation of the nervous portion of the hypothalamus leads to orthosympathetic stimulation and parasympathetic depression, resulting in reduced tissue perfusion, increased afterload, reduced intestinal motricity and tachypnoea. If left unchecked, pain can lead to shock, which, when well established, often has a very poor prognosis. Analgesia is therefore the key stage in the treatment of colicky horses; it must always be adapted to the intensity of the animal's pain (GLUNTZ and GOGNY, 2007; BATAIL, 2005; CIRRIER, 2004; MAIR et al., 2002; WHITE, 1999).

- *Classification of colic according to pain intensity*

The course of colic can take different forms, with different clinical signs depending on the type of condition involved (**Table I**).

**Table I:** Levels of pain according to the intensity of abdominal pain, symptoms and types of condition involved (modified from GLUNTZ, 2009)

Levels		SYMPTOMS OF COLIC	TYPE OF AFFECTION
Stade 1	No pain	-No - Inappetence - Scrapes floor occasionally	

<b>Stade 2</b>	<b>Light pain</b>	<ul style="list-style-type: none"> <li>- Stares at side</li> <li>- Camps up as if to urinate</li> <li>- Lies down longer than normal</li> <li>- Leans against wall</li> <li>- Curls up upper lip</li> <li>- Plays with water without drinking</li> </ul>	Ileus, ischaemia, poor tissue perfusion (dehydration), distension of muscle fibres (around an obstruction)
<b>Stade 3</b>	<b>Moderate pain</b>	<ul style="list-style-type: none"> <li>- Restless, won't stay put</li> <li>- Gathers as if to lie down</li> <li>- Hits abdomen with hind leg</li> <li>- Lies flat on the ground</li> <li>- Rolls over</li> <li>- Adopts a "sitting dog" position</li> <li>- Growls</li> </ul>	Inflammation, fluid retention with distension following occlusion, reperfusion following occlusion, poor tissue perfusion (in the event of obstruction), distension of muscle fibres
<b>Stade 4</b>	<b>Severed pain</b>	<ul style="list-style-type: none"> <li>- Sweats</li> <li>- Rolls violently</li> <li>- Drops to the floor</li> <li>-Any other previously described symptom expressed violently</li> </ul>	Inflammation, distension of the cecum, distension of the folded colon
<b>Stade 5</b>	<b>DEPRESSION</b>	<ul style="list-style-type: none"> <li>- Depression state</li> </ul>	

### 3. PATHOPHYSIOLOGY OF VISCERAL ABDOMINAL PAIN

This is a pathophysiological description based on the enteric nervous system and extrinsic nerves, neuromodulators and certain abnormalities in visceral sensitivity.

- *Enteric nervous system and extrinsic nerves*

The brain-gut axis is organised into two peripheral levels: the enteric nervous system or myenteric plexus, also known as "intrinsic innervation", located in the digestive wall, and the "extrinsic nerves" which link the myenteric plexus to the spinal cord and the central nervous system (CNS). The ENS is connected to the CNS by the following pathways: sympathetic pathways, vagal pathways and lumbosacral (pelvic) pathways (Table III).

In the wall of the digestive tract, the myenteric plexus is organised as a network that forms the "intestinal brain". It contains as many neurons as the spinal cord, most of which are afferent, i.e. sensory, neurons. In this network, interneurons establish connections between afferent and efferent neurons, as well as between neurons at different levels. The myenteric plexus is therefore the first level of integration of digestive sensations, recognising the size, speed and direction of movement of food particles (DELVAUX, 2005). The Enteric Nervous System (ENS) is an integrative nervous system located throughout the digestive tract, making it the second most neuron-rich organ after the brain. It is organised into distinct plexi formed by ganglionic structures connected to each other by inter-ganglionic fibres (NEUNLIST and ROLLINDERKINDEREN, 2012). The main plexuses include the myenteric plexus (Table II), located between the circular and longitudinal muscle layers, and the submucosal plexus, located between the circular muscle layer and the mucosa (WEDEL et al., 1999). Intrinsic innervation is linked to the CNS via three pathways (Table III).

**Table II:** Different histological layers of the digestive tract and associated plexi (FURNESS et al., 2012)

Layers of the digestive tract	Plexi
Mucosa	Submucosal plexus
Submucosa	
Circular muscularis	

<b>Longitudinal muscularis Serosa or adventitia</b>	Myenteric plexus
---	------------------

**Table III:** Pathways linking the ENS to the CNS (FURNESS et al., 2012).

<b>Central Nervous System (CNS)</b>	<b>Vagal pathway</b>	<b>Enteric Nervous System (ENS) or Intrinsic Innervation</b>
	Sympathetic pathway	
	Pelvic or lumbosacral route	

The enteric nervous system (ENS) is made up of neurons and enteric glial cells (GULBRANSEN and SHARKEY, 2012). The ability of the ENS to generate reflexes, independently of any control by the CNS, is due to the presence of three functionally and neurochemically distinct types of intrinsic sensory neurons, interneurons and motor neurons (NEUNLIST and ROLLI-DERKINDEREN, 2012). Neurons regulating the motor functions of the digestive tract are located in the myenteric plexus, while those involved in the control of mucosal functions are located in the submucosal plexus (GRUNDY et al., 2006). The peristaltic activity of the digestive tract, triggered by chemical or mechanical stimuli, results from contraction upstream of the alimentary bolus and simultaneous relaxation downstream. The coordinated repetition of this activity, over a segment, leads to the propagation of the alimentary bolus in an anterior-posterior direction (HUIZINGA and LAMMERS, 2009). One of the central and triggering elements of the peristaltic reflex is the enterochromaffin cell (NEUNLIST and ROLLI-DERKINDEREN, 2012). The brain-gut axis includes so-called descending antinociceptive nerve pathways which travel at the same time as the efferent pathways, from the hypothalamic nuclei. They are distributed to the myenteric plexus and modulate the activity of afferent pathways, particularly the nociceptor neurons which are responsible for painful sensations. From a functional point of view, it is therefore logical to divide the complex nerve pathways linking the brain and the digestive tract into efferent pathways carrying information from the CNS to the periphery, and afferent pathways carrying information received at peripheral level to the higher integration centres (NEUNLIST and ROLLI-DERKINDEREN, 2012).

- *Neurotransmitters*

Neuromodulators can be classified according to their biochemical structure into amines (acetylcholine and noradrenaline), serotonin, peptides (substance P, cholecystokinin, vasoactive intestinal peptide, enkephalins, etc.), purines (adenosine triphosphate, adenosine diphosphate, adenosine) and nitric oxide (NO). In response to chemical or mechanical stimuli, digestive epithelial cells release various neurotransmitters (serotonin, adenosine triphosphate or ATP) near the terminals of enteric sensory neurons. Serotonin activates intrinsic sensory neurons via 5HTP<sub>1p</sub> receptors. These neurons then lead, after activation of interneurons, to the activation of two phenotypically distinct categories of neurons that innervate the circular muscle. Thus, neurons whose axons project in the upward direction synthesise acetylcholine (Ach) and substance P (SP) and are excitatory motor neurons. Neurons, whose axons project in the descending (anal) direction, synthesise nitric oxide (NO), vasoactive intestinal peptide (VIP), and Adenosine Triphosphate (ATP) and are inhibitory motor neurons that induce relaxation downstream of the stimulus (FURNESS et al., 2012). Following activation of these neurons, there is a delayed activation of excitatory neurons, and a contraction allowing the restoration of basic muscle tone.

#### **4. THERAPEUTIC CHOICE**

Knowledge of the pathophysiology and consequences of pain allows a better understanding of the mechanisms by which it occurs and its classification according to severity. In this way, the management of a colicky horse will be easier and more appropriate by anticipating the deterioration in the animal's general condition and avoiding the side effects of the molecules to be used (Tables IV, V and VI).

For example, the efficacy of non-steroidal anti-inflammatory drugs (NSAIDs) is limited to mild to moderate pain (Table IV). In the case of severe level III pain, the action of NSAIDs must be supplemented by another pharmacological class, such as alpha-2 agonists or morphine (Table V). overexploit horses. In addition, improving horse feed is a priority for all those involved in equine activities.

**Table IV:** Main (undesirable) side effects of NSAIDs (GUEZENNEC, 2006)

SYSTEMS	ADVERSE EFFECTS	COMMENTS
<b>DIGESTIVE</b>	Erosions and ulcerations of the gastric glandular mucosa and the mucosa of the large colon	Administer mucous membrane protectors to subjects at risk: foals, ponies or horses treated long-term.
<b>RENAL</b>	Renal hypoperfusion leading to renal papillary necrosis	Low risk in animals with normal volemia. Increased risk in subjects in shock.
<b>CARDIOVASCULAR</b>	Thrombophlebitis and anticoagulant effect.	Long-lasting anticoagulant action of acetylsalicylic acid (11-14 days). Not recommended in cases of coagulation deficiency. Beneficial effect in preventing DIC (laminitis, endotoxemia, etc.).

**Table V:** Main adverse effects of alpha-2 agonists (PERRIN, 1999)

SYSTEMS	ADVERSE EFFECTS	COMMENTS
<b>DIGESTIVE</b>	Significant reduction in motor function for at least 2 hours	Do not allow the horse to eat for 2 hours after sedation
<b>CARDIOVASCULAR</b>	Hypotension and bradycardia. Arrhythmic effect (blocks)	Reserve these molecules for horses with a suitable cardiovascular status.

**Table VI:** Criteria for the indicative choice of analgesic treatment for colic, depending on the treatment objective and the pain observed (GLUNTZ and GOGNY, 2007)

Treatment objective, probable type of pain and desired duration of action	Light pain	Moderate pain	Severe pain
-Mechanical origin, desired effect for 2 to 3 hours	Dipyrone	Dipyrone + alpha-2	Dipyrone + alpha-2 agonists (increase the dose)

-Uncertain diagnosis, temporary relief or -Transport to a clinic, short journey		agonists (low dose)	
-Main mechanical origin, desired effect for 6 to 8 hours -Diagnosis established, lasting relief -Transport to a clinic, long journey	Flunixin or Ketoprofen	Flunixin or Ketoprofen Butorphanol or low-dose morphine (re-administration probably necessary*)	
Main inflammatory origin, desired effect for 8 to 12 hours	Meloxicam or Flunixin or Phenylbutazone	Meloxicam or Flunixin + Butorphanol	Meloxicam or Flunixin + morphine (increase dose) (re-administration 130 Low-dose morphine (re-administration imperative*) imperative*)

### Conclusion

When it comes to abdominal pain in horses, it is important to have knowledge of the anatomy, physiology and innervation of the digestive tract, which will help you to manage algology during colic: understanding the pathophysiology and management of visceral pain during equine colic. Pain is the main factor underlying the symptoms observed during digestive colic in horses. The more intense the pain, the greater and more varied the clinical consequences. Consequently, early and appropriate management of a horse suffering from digestive colic is vital in order to avoid a crescendo of adverse consequences, including reduced performance, reduced well-being and, above all, the death of the horse affected. The management of digestive colic in horses depends on a number of factors, including the causes and severity of the consequences of the pain, and the therapeutic arsenal available.

## REFERENCES

1. ANDREWS F.M.; BUCHANAN B.R.; ELLIOT S.B.; CLARIDAY N.A. ET EDWARDS L.H., 2005. Gastric ulcers in horses. - J. Anim. Sci., 83:18-21.
2. ARNAULD DES LIONS J.; BATTAIL G.A.; GLUNTZ X.; MAURIZI L. ET FONTAINE G., 2002. L'accrochement néphrosplénique chez le cheval adulte : revue bibliographique et actualités thérapeutiques. - Pratique vétérinaire équine, 34 (134) :11-18.
3. BATTAIL G.A., 2005. Premiers gestes au chevet du cheval en coliques (471-473). In : Journées nationales des GTV, Nantes, 25-26-27 Mai 2005.-562p.
4. BIELEFELDT K, GEBHART GF., 2006. Visceral pain: basic mechanisms. Dans Textbook of Pain. Editors: McMahon SB, Koltzenburg M. Elsevier, 5e édition: 2006. p. 721-736.
5. CIRIER PIERRE, 2010. Connaître les causes pour mieux les traiter. <https://www.doc-developpement-durable.org/file/Elevages/cheval/maladies/coliquesDuCheval.pdf>
6. CIRIER PIERRE., 2010. Les coliques digestives du cheval. Paris : Maloine. 114p. <https://www.amazon.fr/coliques-digestives-du-cheval/dp/2224028091>
7. CHABCHOUB A, KANE Y, LANDOLSI F & GHORBEL, 2007. A Ulcères de l'estomac chez le cheval. El Baytary 2007.n°45-46 Juillet 24-25.
8. DELVAUX MICHEL. 2005 : Les douleurs abdominales en question : Rôle physiologique de la sensibilité viscérale. ISBN 2-287-21435-6. Springer-Verlag France 2005.
9. EL MESSAOUDI, F. LANDOSLI et A. CHABCHOUB. 2006. Coliques du cheval : diagnostic et thérapeutique. El Baytary N°41 – 42 du Décembre 2006. Pathologie médicale Equidés et Carnivores. ENMV Sidi Thabet Tunisie 2020.
- 10.FURNESS, J.B. 2012.The enteric nervous system and neuro-gastroenterology. Nature reviews. 9(5) :286–29. <https://pubmed.ncbi.nlm.nih.gov/22392290/>
- 11.JULLIAND Véronique et GENAIN Jean-Luc.03/01/2011. Origines des coliques chez le cheval. <https://equipedia.ifce.fr/sante-et-bien-etre-animal/maladies/systeme-digestif-et-parasitisme/origines-des-coliques#auteurs>
- 12.GOGNY M., 2003. Anti-inflammatoires non stéroïdiens et douleur aiguë chez le cheval. Bulletin des Groupements Techniques Vétérinaires (GTV), 22 : 275-280.
- 13.GRUNDY D., AL-CHAER E.D, AZIZ A., COLLINS S.M., KE M., TACHE Y., WOOD J.D., 2006. Fundamentals of neuro-gastroenterology : basic science. Gastroenterology 130(5): 1391 -1411.
- 14.GUEZENNEC AURELIE MARIE CATHERINE, 2006. Gestion pratique de la douleur chez le cheval. <https://oatao.univ-toulouse.fr/1649/1/Guezenneca.pdf>
- 15.GWENOLA TOUZOT-JOURDE, 2012: Gestion de la douleur viscérale d'origine abdominale chez le cheval La Semaine Vétérinaire n° 176 du 01/10/2012.

16. GLUNTZ X., 2005. Examen clinique du cheval en coliques. - *Pratique Vétérinaire Equine*, 37 (145):73
17. GLUNTZ X. et GOGNY M., 2007. Les coliques du cheval. -Rueil-Malmaison : Les Editions du Point Vétérinaire. - 256p.- (Collection Atlas).
18. HILLYER M.H., TAYLOR F.G.R., ET FRENCH N.P., 2001 a cross-sectional study of colic in horses on thoroughbred training premises in the British Isles in 1997. *Equine Veterinary Journal*, 33, (4): 38-385. <https://doi.org/10.2746/042516401776249499>
19. HILLYER M.H., TAYLOR F.G.R., PROUDMAN C.J., DEWARDS G.B., SMITH J.E., ET FRENCH N.P., 2002. Risk factors for simple colonic obstruction and distension colic in horses. In: *Proceedings of the 7th Equine Colic research Symposium*. *Equine Veterinary Journal*, 34, (5):455-463.
20. MAIR T.; DIVERS T. et DUCHARME N., 2002. *Manual of equine gastroenterology*. - Philadelphia: WB Saunders Co.-540p. <https://www.elsevier.com/books/manual-of-equine-gastroenterology/9780702024863>
21. NEUNLIST, M., VAN LANDEGHEM, L., MAHE, M.M., DERKINDEREN, P., BRULEY DES VARANNES, S.B., ROLLI-DERKINDEREN, M. 2012. The digestive neuronal-glia-epithelial unit: a new actor in gut health and disease. *2013 Nature reviews* 10(2) : 90–100
22. ROBERTSON ET SANCHEZ, 2010 : Robertson, SA et Sanchez, LC (2010). Traitement des douleurs viscérales chez les chevaux. *Cliniques vétérinaires d'Amérique du Nord : Equine Practice*, 26(3), 603–617.
23. PERRIN R., 1999. La douleur en pathologie digestive. - *Pratique vétérinaire équine*, 31 (numéro spécial coliques du cheval): 25-36.
24. SELLON DC, 2007 : *Gestion du cheval en colique*. *Prat. Vet. Equine*. 2007. 158 : 25-33.
25. SERTEYN D., CAUDRON I., SZOKE M., FONTAINE G., STACQUEZ S., CHEVE D., 1994. Diagnostic et pronostic des pathologies intestinales aiguës chirurgicales du cheval. *Prat. Vet. Equine*, 1994, 26, 135-145.
26. THILO WEDEL, UWE ROBLICK, JOACHIM GLEISS, THOMAS SCHIEDECK, HANS-PETER BRUCH, WOLFGANG KÜHNEL, HEINZ-JÜRGEN KRAMMER. 1999. Organization of the enteric nervous system in the human colon demonstrated by whole mount immunohistochemistry with special reference to the sub mucous plexus. *Ann. Anat.* 181 (4):327 – 337. [https://doi.org/10.1016/S0940-9602\(99\)80122-8](https://doi.org/10.1016/S0940-9602(99)80122-8)
27. UNIVERSITE DE MONTREAL, 2018 : Département d'anesthésiologie et de médecine de la douleur. <https://anesthesiologie.umontreal.ca/wp-content/uploads/sites/33/Chap-1-Les-Voies-de-la-Douleur.pdf>
28. WEDEL, T., ROBLICK, U., GLEISS, J., SCHIEDECK, T., BRUCH, H.P., KUHNEL, W., KRAMMER, H.J. 1999. Organization of the enteric nervous system in the human colon

demonstrated by wholemout immunohistochemistry with special reference to the submucous plexus. *AnnAnat.*181(4):327–337

29. WHITE N.A., 1990. The Equine acute abdomen (369-374). -Philadelphia: Lea & Febiger. -434p.<https://www.wiley.com/en-us/The+Equine+Acute+Abdomen,+3rd+Edition-p-9781119063216>

30. WHITE N.A., 1999. Handbook of equine colic. - Oxford: Butterworth & Heinemann. - 146p. <https://lib.ugent.be/catalog/rug01:000659907>

UNDER PEER REVIEW