

Post Traumatic Diaphragmatic Hernia diagnosed after 2 years by a complication of intestinal strangulation within the chest

ABSTRACT

Diaphragmatic rupture is a rare pathology that reported in less than 0.5% of all trauma cases, with signs and symptoms that can easily be misdiagnosed. Clinicians must maintain a high index of suspicion to correctly manage this pathology. We present a case of diaphragmatic hernia that was misdiagnosed until it became strangulated. The time between trauma and occlusive syndrome was 2 years. The patient had symptoms of intestinal obstruction. The CT scan showed colonic left diaphragmatic hernia with a large bowel obstruction. The surgery confirmed the complication of intestinal strangulation within the chest.

KEYWORDS

Post traumatic diaphragmatic hernia, intestinal strangulation

1. INTRODUCTION

Traumatic diaphragmatic hernias are uncommon, but life-threatening, and remain a diagnostic and therapeutic challenge with an overall mortality rate of up to 31% in recent series. [15-17] Early diagnosis of traumatic diaphragmatic hernia is most difficult when herniation is delayed. The early recognition and prompt surgical treatment is needed for better outcome.

2. CASE PRESENTATION

Patient was 26-year-old man. He had as medical history a stab wound measuring 1 cm located at left lateral chest from sixth to seventh intercostal spaces 2 years ago. The wound was sutured without medical investigation.

He was referred to our emergency, he had symptoms of intestinal obstruction : he couldn't have a bowel movement or pass gas, he noticed stomach pain and a swollen belly.

On examination, he was afebrile, with normal respiratory rate and normal resting heart rate. On physical exam, the patient's abdomen was distended, tympanic on percussion. Digital rectal exam was normal.

Abdominal CT scan showed colonic distention affecting the right and transverse colon. The left colic angle was ascended into the thorax via a left diaphragmatic orifice with hydroaeric level at this level. CT scan noted an infiltration of the omental fat also herniated with liquid effusion blade. In conclusion, it was a colonic left diaphragmatic hernia with a large bowel obstruction.

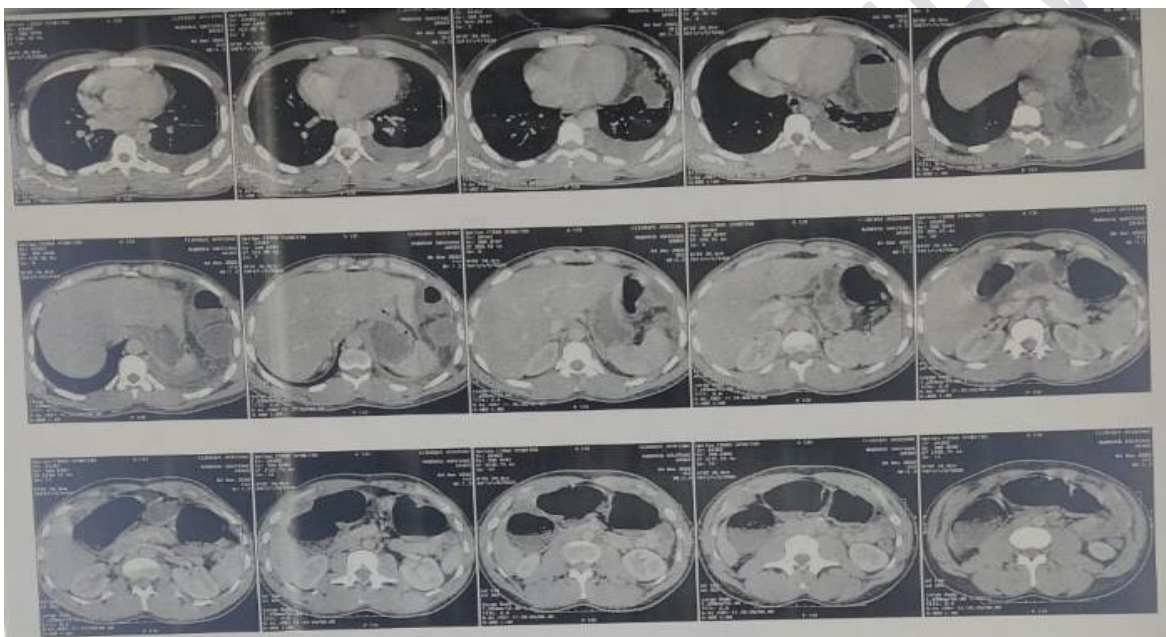


Figure 1 : colonic left diaphragmatic hernia with a large bowel obstruction.

On the same admission day, the patient was transferred to the operating room. The patient and his family gave their approval to do surgery. During laparotomy under general anesthesia, the exploration showed a left diaphragmatic hernia whose collar measures 2 cm, and with left colic angle content (which was ascended in the thorax), and which was responsible for a distension of the right colon and a necrosis of the omentum and the left transverse colon. We proceeded to reduction of the herniated organs. During the intervention, the patient presented hemodynamic instability, so the decision was the resection

of the omentum and the transverse colon taking away the area of necrosis with double barrel colostomy, then the cure of the hernia by raffia. The chest tube drainage of the pleural space was done by thoracic surgeons.

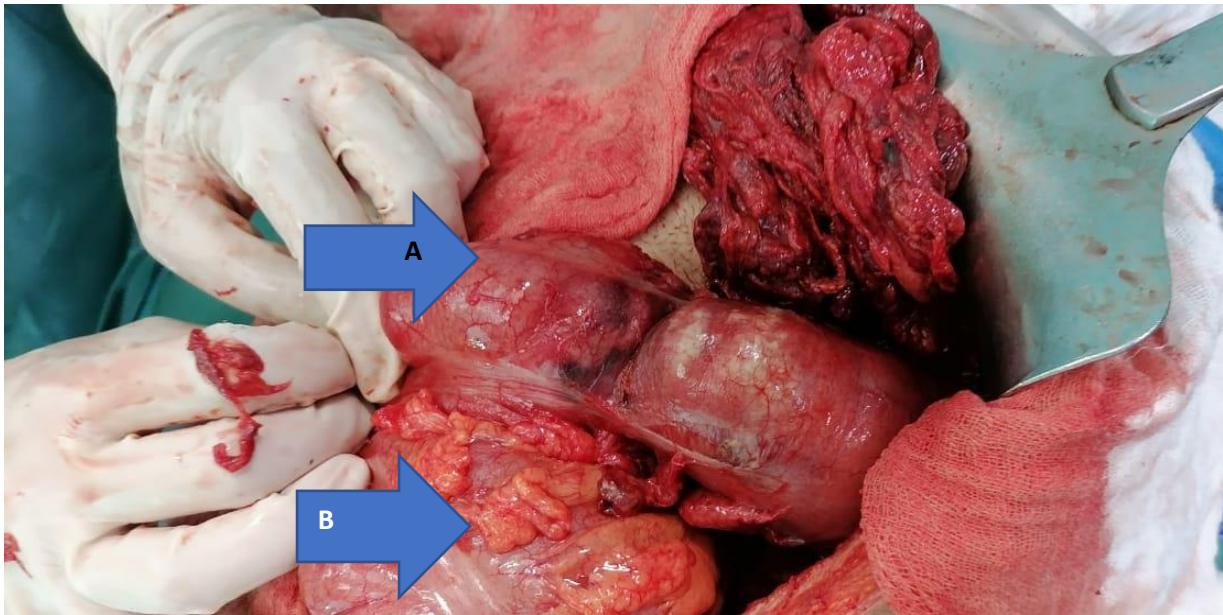


Figure 2 : A-necrosis of the omentum B-necrosis of the left transverse colon.

The post-operative care was simple, the patient was transferred to the thoracic surgery department on postoperative day 2 for additional care. He was discharged from hospital on postoperative day 7, then seen again in consultation without incident. Restoration of colonic continuity is planned for the next few days after completing the necessary investigations.

3. DISCUSSION

“Post traumatic diaphragmatic hernia is the result of a muscle breach of diaphragmatic cupola, that can be complicated with an intra thoracic of the abdominal viscera. It represent specific lesions in trauma and often reflect the severity of the injury” (1). “The etiologies are represented by multiple trauma and thoraco-abdominal wounds as in the case in our patient. In 70% - 90% of the cases, the hernia interests the left diaphragmatic hernia, given the protective role of the right liver. The hernia content is variable, the most frequent compounds are: gastric (31.8%), colon (27.2%), omentum (15.9%), the small intestine (13.6%), spleen (6.8%) and liver (4.5%)” (2). “There can be a

variety between a complete lack of symptoms, mild symptoms like nausea, difficulty in breathing, abdominal, thoracic or shoulder tip pain and acute symptoms due to visceral obstruction, strangulation or perforation, culminating in multiorgan failure” (3). “However, late presentation of diaphragmatic hernia is also seen when the defect of the diaphragm is small and without significant injury to other intra-abdominal or intra-thoracic organs resulting unnoticed initial presentation for a long time until symptoms and signs of herniation of intra abdominal viscera” (4). Like our case, the post Traumatic diaphragmatic hernia was asymptomatic during 2 years, until having a complication of intestinal strangulation within the chest.

“Careful examination of the chest radiograph or CT is important but is diagnostic in only 40% to 80% of cases, depending on the type of CT performed” (5). “Surgical approach in management depends on the time of presentation, location of associated lesions, and surgeons experience” (6). “Both thoracotomy and laparotomy approaches can be used in the repair of diaphragmatic hernias” (6). “In acute settings, in patients with combined thoracic and abdominal viscera injury, a combined thoracic and abdominal cavity exploration is done” (7). “In diaphragmatic hernia repair, with accompanied abdominal cavity, viscera injury laparotomy is the gold standard approach” (8–11).

“However, in delayed presentation cases, long-standing herniated bowels tend to form adhesions with intrathoracic viscera” (12). In these cases, thoracotomy is the best approach (8,11,13,14), as release of adhesions of intra-abdominal viscera in the thoracic cavity is difficult in laparotomy.

“However, some surgeons still advocate for the abdominal approach in long standing cases with adhesions, and thoracic approach in acute cases as long as intra-abdominal viscera injury has been ruled out” (12). “Some surgeons would prefer the abdominal approach in delayed presentation cases as resection, and primary anastomosis of gangrenous incarcerated bowels is easier from the abdominal cavity” (7). “There is no consensus on agreed approach for both acute and long-standing diaphragmatic hernias” (12). The choice of approach differs from authors and might be influenced by surgeons’ preferences or center the procedure is being performed.

4. CONCLUSION

Herniation of abdominal contents into the chest cavity can occur weeks, months or even years after the traumatic injury to diaphragm.

This is why it is necessary to be vigilant in the face of any asymptomatic thoraco-abdominal trauma which can hide a diaphragmatic hernia.

Consent

As per international standards or university standards, patient(s) written consent has been collected and preserved by the author(s).

References

1. Slim K. [Ruptures and injuries to the diaphragm]. *J Chir (Paris)*. juin 1999;136(2):67- 75.
2. Jarry J, Razafindratsira T, Lepront D, Pallas G, Eggenspieler P, Dastes FD. Une complication rare des hernies diaphragmatiques traumatiques : la pleurésie stercorale. *Annales de Chirurgie*. janv 2006;131(1):48- 50.
3. Pantelis D, Burger C, Hirner A, Wolff M. Indirekte traumatische Zwerchfellruptur: Unfallmechanismus und Diagnostik. *Chirurg*. avr 2006;77(4):360- 6.
4. Gaine FA, Lone GN, Chowdhary MA, Lone H. The Etiology, Associated Injuries and Clinical Presentation of Post Traumatic Diaphragmatic Hernia. *Bull Emerg Trauma*. avr 2013;1(2):76- 80.
5. Adams DH. Sleisenger and Fordtran's Gastrointestinal and Liver Disease. *Gut*. 1 août 2007;56(8):1175- 1175.
6. Makar AB, McMartin KE, Palese M, Tephly TR. Formate assay in body fluids: application in methanol poisoning. *Biochem Med*. juin 1975;13(2):117- 26.
7. Gu P, Lu Y, Li X, Lin X. Acute and chronic traumatic diaphragmatic hernia: 10 years' experience. *Maerz LL, éditeur. PLoS ONE*. 12 déc 2019;14(12):e0226364.
8. Dwari AK, Mandal A, Das SK, Sarkar S. Delayed Presentation of Traumatic Diaphragmatic Rupture with Herniation of the Left Kidney and Bowel Loops. *Case Reports in Pulmonology*. 2013;2013:1- 4.

9. Chughtai T, Ali S, Sharkey P, Lins M, Rizoli S. Update on managing diaphragmatic rupture in blunt trauma: a review of 208 consecutive cases. *Can J Surg.* juin 2009;52(3):177- 81.
10. Mahmoud AF, Eldin Raeia MM, Abo Elmakarem MA. Rupture diaphragm: Early diagnosis and management. *Journal of the Egyptian Society of Cardio-Thoracic Surgery.* juin 2017;25(2):163- 70.
11. Okan I, Bas G, Ziyade S, Alimoglu O, Eryilmaz R, Guzey D, et al. Delayed presentation of posttraumatic diaphragmatic hernia. *Ulus Travma Acil Cerrahi Derg.* 2011;17(5):435- 9.
12. Silva GP, Cataneo DC, Cataneo AJM. Thoracotomy compared to laparotomy in the traumatic diaphragmatic hernia. Systematic review and proportional methanalysis. *Acta Cir Bras.* janv 2018;33(1):49- 66.
13. Kahwa AA. Blunt Diaphragmatic Rupture a Case Report and Literature Review. *Emerg Med (Los Angel) [Internet].* 2016 [cité 10 févr 2023];6(4). Disponible sur: <https://www.omicsgroup.org/journals/blunt-diaphragmatic-rupture-a-case-report-and-literature-review-2165-7548-1000335.php?aid=77699>
14. Peer SM, Devaraddeppa PM, Buggi S. Traumatic diaphragmatic hernia-our experience. *International Journal of Surgery.* 2009;7(6):547- 9.
15. Shabhay A, Horumpende P, Shabhay Z, Van Baal SG, Lazaro E, Chilonga K. Surgical approach in management of posttraumatic diaphragmatic hernia: thoracotomy versus laparotomy. *Case Reports in Surgery.* 2020 Dec 5;2020.
16. Lu J, Wang B, Che X, Li X, Qiu G, He S, Fan L. Delayed traumatic diaphragmatic hernia: A case-series report and literature review. *Medicine.* 2016 Aug;95(32).
17. Morgan BS, Watcyn-Jones T, Garner JP. Traumatic diaphragmatic injury. *BMJ Military Health.* 2010 Sep 1;156(3):139.