

Case study

Post Traumatic Diaphragmatic Hernia diagnosed after 2 years by a complication of intestinal strangulation within the chest

ABSTRACT

Diaphragmatic rupture is a rare pathology that is reported in less than 0.5% of all trauma cases, with signs and symptoms that can easily be misdiagnosed. Clinicians must maintain a high index of suspicion to correctly diagnose and manage this pathology.

We present a case of a diaphragmatic hernia that was misdiagnosed until it became strangulated.

The time between trauma and occlusive syndrome was 2 years.

The patient presented symptoms of intestinal obstruction.

The CT scan showed a colonic left diaphragmatic hernia with a large bowel obstruction.

The surgery confirmed the complication of intestinal strangulation within the chest.

KEYWORDS

Post-Post-traumatic diaphragmatic hernia, intestinal strangulation

1. INTRODUCTION

Early diagnosis of traumatic diaphragmatic hernia is most difficult when herniation is delayed.

The eEarly recognition and prompt surgical treatment is needed for better outcome.

2. CASE PRESENTATION

~~Patient~~ The patient was a 26-year-old man.

He had as medical history a stab wound ~~measuring-measuring~~ 1 cm located at the left lateral chest from the sixth to seventh intercostal spaces 2 years ago.

The wound was sutured without medical investigation.

He was referred to our emergency, he had symptoms of intestinal obstruction: he couldn't have a bowel movement or pass gas, he noticed stomach pain, and a swollen belly.

On examination, he was afebrile, with normal respiratory rate and normal resting heart rate.

On physical exam, the patient's abdomen was distended, tympanic on percussion.

~~Digital~~ The digital rectal exam was normal.

Abdominal CT ~~scan~~ showed colonic distention affecting the right and transverse colon.

The left colic angle was ascended into the thorax via a left diaphragmatic orifice with a hydroaeric level at this level.

CT ~~scan~~ noted an infiltration of the omental fat also herniated with a liquid effusion blade.

In conclusion, it was a colonic left diaphragmatic hernia with a large bowel obstruction.

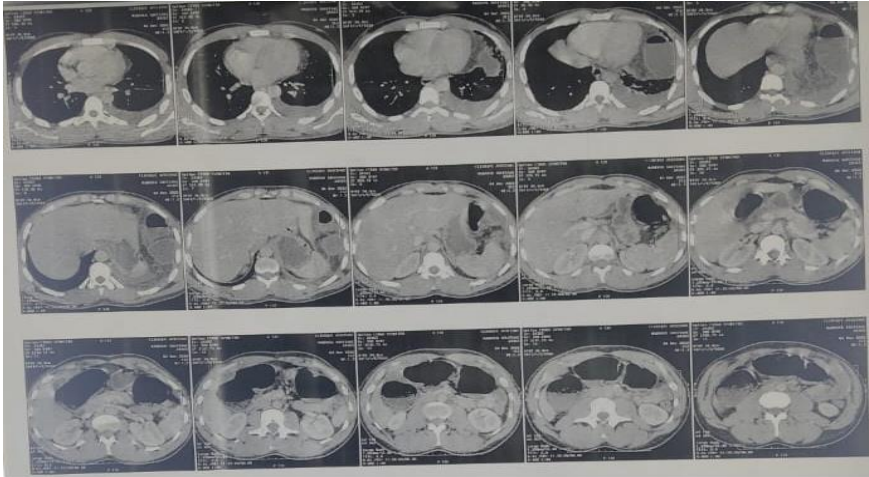
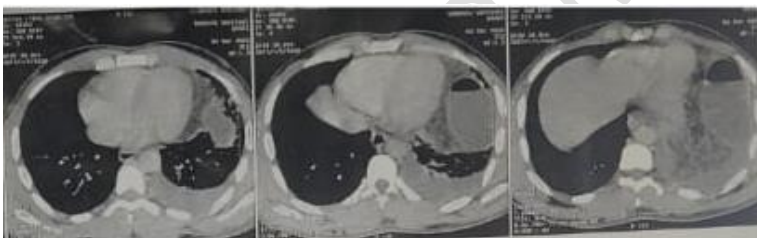

Figure 1 : colonic left diaphragmatic hernia with a large bowel obstruction.

Commented [SZ1]: Better to choose 2 pictures only & Make it bigger ,Below is my suggested Figure.



On the same admission day, the patient was transferred to the operating room.

The patient and his family gave their approval to do surgery.

During laparotomy under general anesthesia, the exploration showed a left diaphragmatic hernia whose collar measures 2 cm, and with left colic angle content (which was ascended in the thorax), and which was responsible for a distension of the right colon and a necrosis of the omentum and the left transverse colon.

We proceeded to a reduction of the herniated organs.

During the intervention, the patient presented hemodynamic instability, so the decision was the resection of the omentum and the transverse colon taking away the area of necrosis with double barrel colostomy, then the cure of the hernia by raffia.

The chest tube drainage of the pleural space was done by thoracic surgeons.

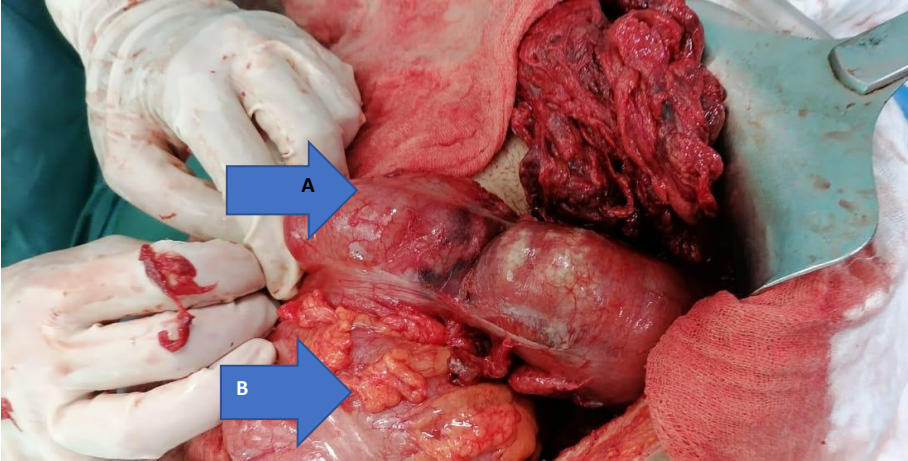


Figure 2 : A-necrosis of the omentum B-necrosis of the left transverse colon.

The post-operative care was simple, the patient was transferred to the thoracic surgery department on postoperative day 2 for additional care.

He was discharged from [the](#) hospital on postoperative day 7, [and](#) then seen again in consultation without incident.

Restoration of colonic continuity is planned for the next few days after completing the necessary investigations.

3. DISCUSSION

Post-traumatic diaphragmatic hernia is the result of a muscle breach of [the](#) diaphragmatic cupola, [that-which](#) can be complicated [with-by](#) an intrathoracic of the abdominal viscera. It represents [specific](#) lesions in trauma and often reflects [the](#) severity of the injury (1).

The etiologies are represented by multiple trauma and thoraco-abdominal wounds as in the case in our patient.

In 70% - 90% of the cases, the hernia interests the left diaphragmatic hernia, given the protective role of the right liver. The hernia content is variable, the

most frequent compounds are gastric (31.8%), colon (27.2%), omentum (15.9%), the small intestine (13.6%), spleen (6.8%), and liver (4.5%) (2).

There can be a variety between a complete lack of symptoms, mild symptoms like nausea, difficulty in breathing, abdominal, thoracic, or shoulder tip pain, and acute symptoms due to visceral obstruction, strangulation, or perforation, culminating in multiorgan failure (3).

However, late presentation of diaphragmatic hernia is also seen when the defect of the diaphragm is small and without significant injury to other intra-abdominal or intra-thoracic organs resulting in unnoticed initial presentation for a long time until symptoms and signs of herniation of intra abdominal viscera (4).

Like our case, the post-traumatic diaphragmatic hernia was asymptomatic during for 2 years, until having a complication of intestinal strangulation within the chest.

Careful examination of the chest radiograph or CT is important but is diagnostic in only 40% to 80% of cases, depending on the type of CT performed (5).

Surgical approach in management depends on the time of presentation, location of associated lesions, and surgeons experience (6).

Both thoracotomy and laparotomy approaches can be used in the repair of diaphragmatic hernias (6).

In acute settings, in patients with combined thoracic and abdominal viscera injury, a combined thoracic and abdominal cavity exploration is done (7).

In diaphragmatic hernia repair, with accompanied abdominal cavity, viscera injury laparotomy is the gold standard approach (8–11).

However, in delayed presentation cases, long-standing herniated bowels tend to form adhesions with intrathoracic viscera (12). In these cases, thoracotomy is the best approach (8,11,13,14), as a release of adhesions of intra-abdominal viscera in the thoracic cavity is difficult in laparotomy.

However, some surgeons still advocate for the abdominal approach in long long-standing cases with adhesions, and the thoracic approach in acute cases as long as intra-abdominal viscera injury has been ruled out (12). Some surgeons would prefer the abdominal approach in delayed presentation cases as resection, and primary anastomosis of gangrenous incarcerated bowels is

easier from the abdominal cavity (7). There is no consensus on [an](#) agreed approach for both acute and long-standing diaphragmatic hernias (12). The choice of approach differs from [the](#) authors and might be influenced by surgeons' preferences or [the](#) center the procedure is being performed.

4. CONCLUSION

Herniation of abdominal contents into the chest cavity can occur weeks, months, or even years after the traumatic injury to [the](#) diaphragm.

This is why it is necessary to be vigilant in the face of any asymptomatic thoraco-abdominal trauma [which-that](#) can hide a diaphragmatic hernia.

References

1. Slim K. [Ruptures and injuries to the diaphragm]. J Chir (Paris). [juin](#) 1999;136(2):67- 75.
2. Jarry J, Razafindratsira T, Lepront D, Pallas G, Eggenspieler P, Dastes FD. Une complication rare des hernies diaphragmatiques traumatiques : la pleurésie stercorale. [\[Tension faecopneumothorax as the rare presenting feature of a traumatic diaphragmatic hernia\]](#). Annales de Chirurgie. janv 2006;131(1):48- 50.
3. Pantelis D, Burger C, Hirner A, Wolff M. Indirekte traumatische Zwerchfellruptur: Unfallmechanismus und Diagnostik. [\[Trauma mechanism and diagnosis of blunt diaphragmatic rupture\]](#) Chirurg. avr 2006;77(4):360-6.
4. Gaine FA, Lone GN, Chowdhary MA, Lone H. The Etiology, Associated Injuries and Clinical Presentation of Post Traumatic Diaphragmatic Hernia. Bull Emerg Trauma. avr 2013;1(2):76-80.
5. Adams DH. Sleisenger and Fordtran's Gastrointestinal and Liver Disease. Gut. 1 août 2007;56(8):1175-1175.
6. Makar AB, McMartin KE, Palese M, Tephly TR. Formate assay in body fluids: application in methanol poisoning. Biochem Med. [juin](#) 1975;13(2):117-26.

7. Gu P, Lu Y, Li X, Lin X. Acute and chronic traumatic diaphragmatic hernia: 10 years' experience. Maerz LL, éditeur. PLoS ONE. [12 déc 2019](#);14(12):e0226364.
8. Dwari AK, Mandal A, Das SK, Sarkar S. Delayed Presentation of Traumatic Diaphragmatic Rupture with Herniation of the Left Kidney and Bowel Loops. Case Reports in Pulmonology. [2013;2013:1-4](#). [2013;2013:814632](#).
9. Chughtai T, Ali S, Sharkey P, Lins M, Rizoli S. Update on managing diaphragmatic rupture in blunt trauma: a review of 208 consecutive cases. Can J Surg. juin 2009;52(3):177-81.
10. Mahmoud AF, Eldin Raeia MM, Abo Elmakarem MA. Rupture diaphragm: Early diagnosis and management. Journal of the Egyptian Society of Cardio-Thoracic Surgery. juin 2017;25(2):163-70.
11. Okan I, Bas G, Ziyade S, Alimoglu O, Eryilmaz R, Guzey D, et al. Delayed presentation of posttraumatic diaphragmatic hernia. Ulus Travma Acil Cerrahi Derg. 2011;17(5):435-9.
12. Silva GP, Cataneo DC, Cataneo AJM. Thoracotomy compared to laparotomy in the traumatic diaphragmatic hernia. Systematic review and proportional methanalysis. Acta Cir Bras. janv 2018;33(1):49-66.
13. Kahwa AA. Blunt Diaphragmatic Rupture a Case Report and Literature Review. Emerg Med (Los Angel) [Internet]. 2016 [cité 10 févr 2023];6(4). Disponible sur: <https://www.omicsgroup.org/journals/blunt-diaphragmatic-rupture-a-case-report-and-literature-review-2165-7548-1000335.php?aid=77699>
[Al-Kahwa A .Blunt Diaphragmatic Rupture a Case Report and Literature Review. Emerg Med \(Los Angel\).2016 ; 6: 335. doi: 10.4172/21657548.1000335](#)
14. Peer SM, Devaraddeppa PM, Buggi S. Traumatic diaphragmatic hernia-our experience. International Journal of Surgery. 2009;7(6):547-9.