

Original Research Article

ANTI-HYPERGLYCEMIC EFFECTS AND HISTOLOGICAL CHANGES IN STREPTOZOTOCIN-INDUCED DIABETIC RATS FED WITH HIGH CONCENTRATION OF *COLOCASIA ESCULENTA* FLOUR.

ABSTRACT

Background: Diabetes mellitus (DM) affects 536.6 million people globally, with an estimated 12.2% growth by 2045. DM management is extremely expensive, hence alternative treatments combining the use of therapeutic plant foods are being investigated. Because *Colocasia Esculenta* (CYN) is one of these plants, the primary goal of this research was to investigate the effects of CYN high concentration (CHC) extracts on biochemical and histological levels in streptozotocin-induced diabetic rats. **Methodology:** Locally sourced CYN was ground into a fine powder, moulded into pellets, dried in an oven at 600°C, and stored. Forty-two male albino rats weighing 134 and 247 grams were prepared. Insulin resistance was induced with a low-dose fructose diet. Streptozotocin (STZ) was used to induce type-2 diabetes mellitus (T2DM). The experimental formulation was administered for 28 days, after which the animals were sacrificed and their organs and blood samples were taken for various biochemical and histological analyses. The rats' body and organ weights were also measured. **Results & Discussion:** The active biological substances in the cocoyam flour included phenolics, D-stilbene, phthalate, and artemisinin, along with more antioxidant minerals than those found in rat meals that are sold commercially. The formulation exhibited CAT activity of 7.9 units/min and DPPH of 53.2%. Poor glycemic control was suggested by the persistently elevated random blood glucose readings observed along the time trend. Both the usual control group and the cocoyam-fed group have identical histological features in their liver and pancreas. **Conclusion:** Although having a poor glycemic control, a high concentration of cocoyam flour in SDRs demonstrated comparable histological effects to the anti-diabetic drug, metformin, suggesting that it could be used as an additional treatment for patients with type 2 diabetes.

Keywords: Cocoyam flour, Histology, diabetic rats

1. INTRODUCTION

Diabetes mellitus (DM) is an endocrine and metabolic disease that affects 536.6 million people worldwide (10.5%) and is predicted to impact 783.2 million people by 2045 [1] due to an increase in the incidence of 12.2% among adults aged 20 to 79. Ketoacidosis, heart failure, renal failure, and blindness are among the health effects of hyperglycemia brought on by pancreatic cell malfunction or inadequate insulin synthesis [2]. Cases of diabetes mellitus are rising faster in low-income countries—like Nigeria—than in high-income ones, with higher incidence, prevalence, and daily adjusted life years (DALYs) [3]. There are many

challenges associated with managing diabetes, including those related to finances, labour, the infrastructure of healthcare, and handling complications.

[4]. This affects those affected people's quality of life, life expectancy, and productivity [5]. A major problem for nations with unstable healthcare systems and limited resources is managing the high costs and complexity of diabetic complications [6]. Thus, there is a critical need for research on practical ways to reduce the frequency, intensity, and complications of the illness while making the best use of available resources, particularly in developing countries. Included as supplemental management techniques, lifestyle modifications such as increasing physical activity and adhering to recommended eating habits have been shown to significantly reduce risk factors, which in turn reduces the frequency of new cases, the severity of the disease, and associated problems.

[7]. Diabetic Medical Diet Therapy comprises developing customized evidence-based dietary plans that take into account a variety of factors, including insulin adjustments based on lifestyle [8]. Dietary therapy has been demonstrated to help with Diabetes Mellitus [9]. Plants and plant-based meals are recognized for their involvement in diabetes management, with the World Health Organisation recommending medicinal plants for disease prevention and management [10]. Some medicinal plants include bioactive compounds with antioxidant and anti-inflammatory properties. Roots and tubers high in carbohydrates with a low glycemic index, such as cocoyam, have been associated with immunomodulatory and antihyperglycemic actions in both vivo and in vitro [11,12]. Food contains bioactive components such as peptides, amino acids, flavonoids, and polyphenols. These substances contain phytochemicals such as diterpenoids, alkaloids, flavonoids, phenolics, and peptides, which stimulate pancreatic β -cells and hepatic enzymes to regulate blood glucose levels (13). Many studies have demonstrated that the phytochemicals in cocoyam have hypoglycemic and antioxidant properties [14, 15]. Eleazu and colleagues (16) observed that the mechanism behind this antidiabetic activity was associated with the suppression of acute pancreatitis and the delay or regulation of the starch-to-glucose conversion process. Many

medicinal plants have been demonstrated to provide anti-diabetic properties. Examples include extracts from the bulb of *Allium sativum* L., the leaf extract of *Aloe vera*, and the seed kernel of *Mangifera indica*.

This study aimed to evaluate the biochemical and antihyperglycemic effects of a plant-based diet containing cocoyam flour in diabetic rats.

2. MATERIAL AND METHODS

Collection and Preparation of the Plant Food Material

The roots of a *Colocasia Esculenta* variety known locally as edeefe in South East Nigeria were purchased from a popular local market, identified by a plant taxonomist using its accessions number NCe 005, and the sample was processed by adequately washing, peeling, and soaking in water for 10 minutes before being rinsed, boiled, and oven dried at 600C until a constant weight was obtained. The dry weight was then processed into fine flour pellets and oven-dried at 600°C until a consistent weight was achieved. The pelletized meal was then stored in a clean, airtight container until used to feed the rats.

Experimental Animals

For the study, forty-two (42) male albino rats weighing between 134 and 249 grams were procured from a reliable source. The rats were weighed once a week, and their weights were meticulously recorded before they were split into four groups, A, B, C, and D. Each group consisted of ten rats, which were identified by placing a permanent marker with the numbers 1 through 10 on the tail. For a week, water and food were provided at no cost to each group. Every week, the rats were weighed, and

their weights were meticulously recorded. Every lab animal was treated following established procedures [18].

Induction of Insulin Resistance Using Low Fructose Diet

Male albino rats that had been acclimated were given a diet low in fructose (10%) to develop insulin resistance. This diet was carefully planned, involving the dissolution of 30 grams of fructose in 300 milliliters of water. After a one-week acclimatization period, the rats were given 25 millilitres of fructose water as a drinking source ad libitum for two weeks. Rat food was also offered to every rodent at will.

Induction of Type 2 Diabetes Mellitus using STZ

The rats fasted overnight on the sixth day of the reduced fructose diet, and their blood glucose levels were measured. Next, rats suffering from normoglycemia were given intraperitoneal injections of Streptozotocin (STZ) at a concentration of 1 g. This was dissolved in 50 mL of freshly made buffer solution (sodium citrate buffer, 0.1M, pH 4.5). The volume of injection was determined by applying the formula for giving extracts to experimental animal subjects [19, 20]. Before beginning the experimental feeding procedures, blood samples were taken from the treated rats' tail veins at 72 hours and day 12 after STZ exposure. These samples were used to measure blood glucose levels using a blood glucose meter (Acu-check activeR). After receiving STZ medication, three deaths were recorded.

The normal control group consisted of nine rats, while the other ten rats with STZ-induced diabetes were randomly assigned to the standard control, negative control, and intervention groups. Following the work of Nnadi and colleagues [21], all the groups received treatment for 28 days. Groups A and B received commercial rat feed

using 4.48 kg (20 g x 8 rats x 28 days), Group C received metformin at 200 mg/kg, as 0.002 ml per Kg body weight orally daily using an oral dispenser, and Group D received a 50% blend of *Colocasia esculenta* flour with commercial rat feed. The groups were as follows:

Group A: Standard Control

Group B: Normal Control

Group C: Negative Control

Group D: STZ-induced diabetic rats administered with *Colocasia Esculenta* (Cocoyam) flourintervention feed

a. Estimation of blood glucose

The rats were given an overnight fast after 28 days, and a weighing machine was used to determine their final body weights. The Acu-check activeR glucometer was used to measure the blood glucose levels.

b. Estimation of Antioxidant Mineral Analysis

Antioxidant minerals like zinc, copper, magnesium, and manganese were studied using the Atomic Absorption Spectrophotometer (AAS) (Analyst 200, Perkin Elmer, Wallham, MA, USA).

c. Determination of antioxidant activities (DPPH)

The 2, 2-Diphenyl 1-picrylhydrazyl (DPPH) Free Radical Scavenging Activity was determined by spectrophotometric analysis. We followed the protocol that was described by Oulai and colleagues [22]. The antioxidant was computed using the sample extract's potential for free radicals.

Histological studies of Pancreas and Liver

The pancreas and liver were taken by dissection from the diethyl ether-anesthetized and slaughtered animals. They were then fixed in 10% buffered formalin and dried using a series of alcohol gradations. These tissues were embedded using paraffin wax. Sections of 4-5 μm were cut serially using an American Optical Model 82 microtome. After the slices were cut and mounted on glass slides, hematoxylin and eosin (HE) staining was done. The samples stained with HE were examined under a microscope.

Statistical Analysis

The data were analyzed using the Statistical Package for Social Sciences (SPSS Inc., Chicago, IL) version 20.0. The results were obtained and expressed as the standard error of the mean (SEM) of triplicate for each group of eight rats. To ascertain if the mean difference was statistically significant at $P < 0.05$, Tukey's post-hoc test was employed. An analysis of variance (ANOVA) conducted in one direction was used to compare the means.

3. RESULTS AND DISCUSSION

1.0 Antioxidant Mineral Composition & Antioxidant Activities

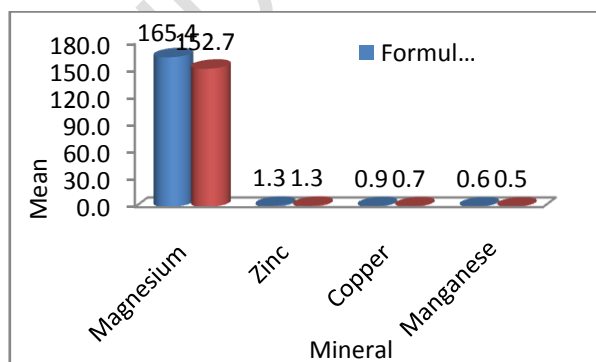


Figure 1: Antioxidant Mineral Compositions of the Cocoyam Flour

Figure 1 revealed that in comparison with commercial rat feed, the magnesium, copper, and manganese concentrations in the cocoyam flour formulation were

greater.

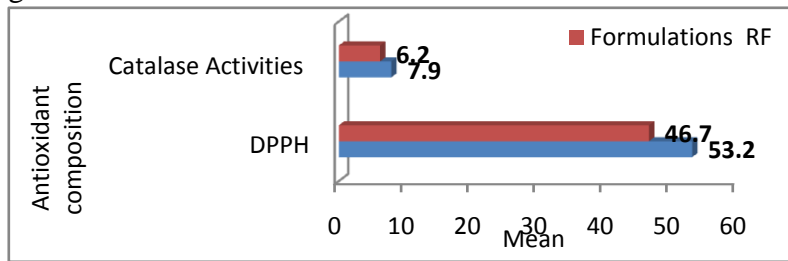


Figure 2: Antioxidant Activities of the Cocoyam Flour

DPPH and CAT activities were greater in the cocoyam flour formulation than in the standard rat diet.

2.0: Effect on Blood Glucose

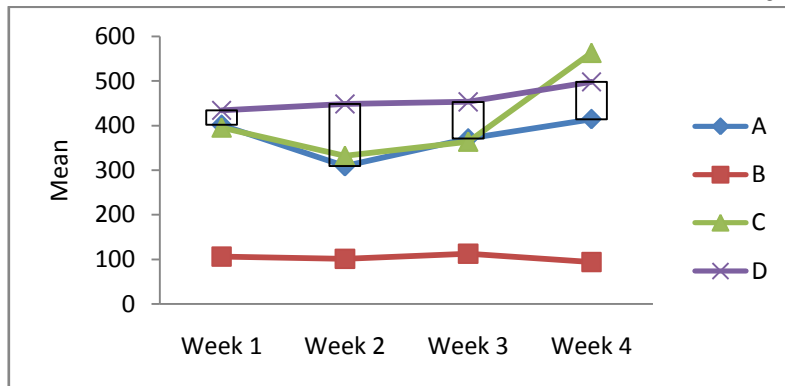


Figure 3: Effect on Blood Glucose over time

Figure 3 demonstrates that the rat group fed cocoyam flour (Group D) exhibited poorer random blood glucose control than the usual control (Group A) all over time.

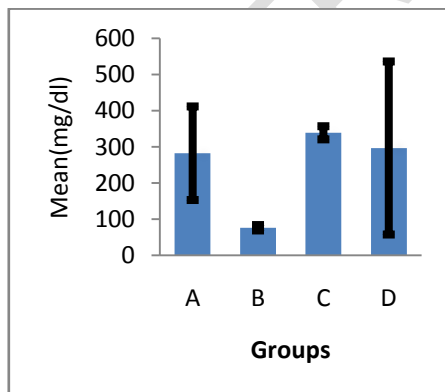
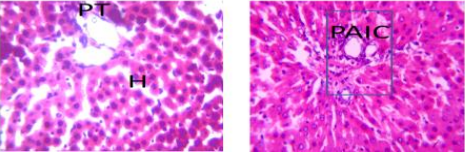
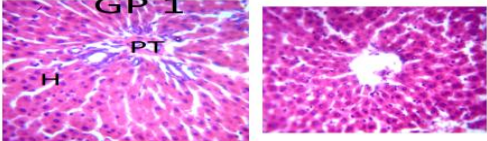
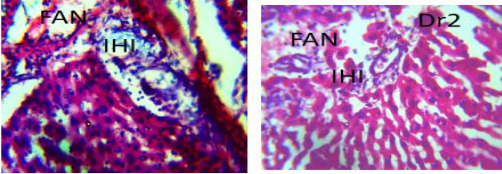
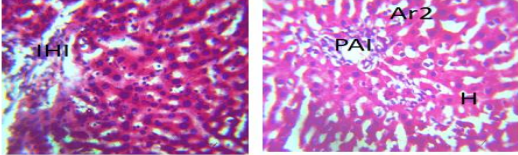


Figure 4: Fasting Blood Glucose Level on the Day of Sacrifice

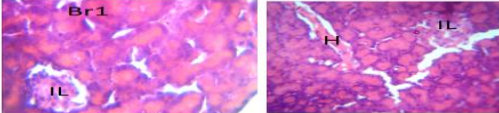
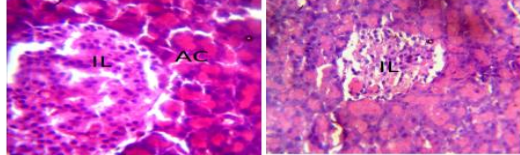
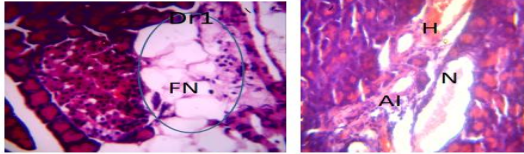
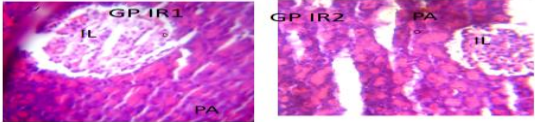
Figure 4 shows that during the fourth week of intervention, Group D rats fed cocoyam flour had similar fasting blood glucose values to rats given regular therapy (Group A).

2. Organ Histology

2.1 Liver Histology

 <p>Plate 1: Photomicrograph of Group A Section of liver (x400) (H/E) shows mild aggregate of inflammatory cell (PAIC) otherwise normal with active hepatocyte</p>	
 <p>Plate 2: Photomicrograph of group B Section of liver (x400) (H/E) shows hepatic tissue with portal triad (PT) and active hepatocyte (H) and central vein (CV)</p>	
 <p>Plate 3: Photomicrograph of Group C Section of liver induced and treated (x400) (H/E) shows severe degeneration with a focal area of necrosis (N) and severe intrahepatic inflammation (IHI)</p>	
 <p>Plate 4: Photomicrograph of Group D Section of liver induced and treated (x400) (H/E) shows mild regeneration with moderate intrahepatic inflammation (IHI) and portal aggregate of inflammation (PAI)</p>	

4.2 Pancreas Histology

 <p>Plate 5: Photomicrograph of Group A Section of the pancreas (x400) (H/E) shows moderate regeneration with mild areas of haemorrhage (H) with non-distinct pancreatic cell and the islet of Langerhans (IL)</p>	
 <p>Plate 6: Photomicrograph of Group B Section of the pancreas (x400) (H/E) shows normal pancreatic tissue with the active islet of Langerhans (IL) and acini cells (AC)</p>	
 <p>Plate 7: Photomicrograph of Group C Section of pancreas (x400) (H/E) shows severe degeneration with severe focal area of fatty necrosis (FN) around the islet of langerhan (IL) and severe necrotic (N) area with aggregate of inflammation (AI) and haemorrhage (H)</p>	
 <p>Plate 8: Photomicrograph of Group D Section of pancreas (x400) (H/E) shows moderate regeneration with mild pyknotic acini (PA) and moderate distinct islet of langerhan (IL)</p>	

Plates 1-4 showed histological characteristics in liver tissues. Histological traits were comparable between the group and the standard control. Similarly, Plates 5-8 analyzed the histological features of the pancreas of the various groups, highlighting the similarities between Groups A and D rats.

DISCUSSION

1.0 Antioxidant Compositions & Activities

The cocoyam formulation contained the active ingredients Dibutyl phthalate, Phenol, 2,6-dimethoxy, E)-Stilbene, 2-Methoxy-4-vinylphenol, Benzofuran, 2,3-dihydro-,

and Dihydroartemisinin, 10-O-(t-butyloxy)-. The current study's findings were consistent with previous research on these botanical food extracts, which revealed the presence of polyphenolic compounds, alkaloids, tannin, and flavonoids [15, 23], as well as fatty acid derivatives like hexanoic acid, bis (2-ethylhexyl) ester, octadecanoic acid, and 3-5-di-t-butyl phenol [16]. These compounds are antioxidant and hypoglycemic [15, 23]. Zinc, copper, manganese, and magnesium are among the antioxidant minerals found in cocoyam flour.

In this study, the average levels of zinc (1.285 mg/100 g and 1.30 mg/100 g), copper (0.69 mg/100 mg and 0.86 mg/100 mg), manganese (0.48 mg/100 mg and 0.61 / 100 mg), and magnesium (152.71 mg/100 mg and 165.36 mg/100 mg) were found in commercial rat feed, RF formulations, and cocoyam formulations, respectively (Figure 1). These data reveal statistically significant differences between the cocoyam formulation and commercial rat food, with the cocoyam formulation containing more of all four (100%) antioxidant minerals (Figure 1). Previous research revealed variances in mineral concentrations in various cocoyam cultivars, including Zn, Cu, Mn, and Mg [24].

For instance, Wada and colleagues [24] observed that the concentrations of Zn, Cu, Mn, and Mg in green cocoyam were 3.06 mg/100g, 1.04 mg/100g, 2.48 mg/100g, and 78.77 mg/100g, respectively (Figure 1). According to previous investigations, Mg, Cu, and Mn levels in cocoyam corm flour were reported by Coronell-Tovar and colleagues [25] to be 0.72 mg/g, 6.90µg/g, and 4.42 µg/g, respectively. The presence of antioxidant minerals and bioactive ingredients in cocoyam's composition helps it

scavenge free radicals. The DPPH activity of the cocoyam formulation employed in this study was 53.21%, significantly greater than the 46.02% recorded in the rat meal that was sold commercially (Figure 2).

It has been demonstrated by Aini and Maritsa [26], Kurniawan and colleagues [27], and Amrulloh and colleagues [28] that plant extracts from cocoyam can neutralize free radicals. They determined their antioxidant efficacy by scavenging free radicals with DPPH. The efficacy of these extracts has been linked to several polyphenols, such as rutin, myricetin, quercetin, kaempferol, mangiferin, and naringin [16, 27]. One study [16] found a DPPH free radical scavenging activity of $65.73 \pm 11.94\%$. The DPPH method is a quick and simple way to evaluate the antioxidant capacity of plant extracts. The antioxidant capability of the flour mixture was evaluated in the current study using complementary assays including catalase activity and antioxidant mineral determination.

The CAT activity of the flour formulations was 7.07 and 6.15 units/min for the cocoyam and commercial rat feed, respectively, showing that the cocoyam flour had a 15% higher CAT activity than the commercial feed (Figure 2). Catalase is a necessary antioxidant enzyme to counteract oxidative damage caused by high levels of reactive oxygen species. Nutritional treatment recommends the consumption of bioactive ingredients such as ellagic acid and flavonoids, as they have been found to boost catalase activity *in vitro*. Enzymatic processes catalase or glutathione peroxidase convert the highly reactive superoxide anion into O_2 , which is subsequently transformed into the less reactive species H_2O_2 . Superoxide dismutase (SOD) aids in this process.

2.0 Effect on Blood Glucose

The average random blood glucose (RBG) levels between the groups were discovered to differ significantly ($F= 13.963$, $p<0.001$), and these disparities varied steadily from the first to the fourth week (Figures 3 and 4). It was shown that the consistency from week one to week four was substantially parallel ($F=79.106$, $p<0.01$). This suggests that the trend was positive. The RBG values of the group that consumed the formulation based on cocoyam exhibited a steady rising trend over time (Figure 3). A comparison of the two groups (Figure 3) demonstrates that during the intervention period, the RBG levels of the intervention group were consistently higher than those of the normal, standard, and diabetic controls.

The results indicate that the intervention with flour formulations at such concentration did not improve RBG control in diabetic rats fed traditional rat diets or the antidiabetic medication metformin. These findings are at odds with those of past research [15, 16] that looked at the hypoglycemic effects of smaller dosages of cocoyam flour. The pro-oxidant qualities of antioxidants at higher concentrations may be the reason for the hyperglycemic effects observed, despite the formulations containing bioactive substances with antidiabetic properties, such as phenolics and artemisinin [29, 30]. Eleazu and colleagues' earlier studies demonstrated that giving lesser dosages of cocoyam flour to diabetic rats induced with streptozotocin (STZ) for three to four weeks decreased blood glucose levels by 38% to 58.75% [16].

Effects on Organ Histology

The investigation's negative control cohort of rats' liver specimens showed notable degeneration, focal necrotic regions, and significant intrahepatic inflammation

compared to the control group (Plate 3). These results demonstrated the harmful effects on the liver of streptozotocin (STZ) and hyperglycemia. This result was in line with another study that looked at the liver on day 10 in diabetic mice who were given STZ, and that discovered hepatocyte lipid accumulation, deformed sinusoids, inflammatory changes, and necrotic features [31]. The diabetic rats in the intervention group displayed minor intrahepatic inflammation, portal inflammatory aggregation, and a moderate level of liver regeneration when they were given the cocoyam intervention formulation (Plate 4).

These results imply that the formulation successfully prevented the organ damage brought on by STZ and encouraged the healthy regeneration of the harmed hepatic cells. In a similar vein, the pancreas studied in this study showed that, in comparison to the control group (Plate 6), the diabetic control group had severe degradation of pancreatic cells, focal necrotic regions, and considerable intrahepatic inflammation, demonstrating unmitigated injury from STZ and hyperglycemia. The histological characteristics of the group that received regular anti-diabetic medication, including mild pyknotic acini, moderate regeneration, and relatively well-defined Islets of Langerhans (Plate 6), were comparable to those of the group that consumed cocoyam flour (Plate 8). Benzofuran, 2,3-dihydro-, Dihydroartemisinin, 10-O-(t-butyloxy)-, Phenol, 2,6-dimethoxy, E)-Stilbene, 2-Methoxy-4-vinylphenol, and Dibutyl phthalate were all present in cocoyam flour. The biological functions of these polyphenols, stilbene, and artemisinin, include protecting pancreatic and hepatic cells. Some polyphenols, like quercetin, resveratrol, and tea extracts, have been demonstrated to upregulate the antioxidant defence system, which also protects tissues [34], and to have protective effects against cellular oxidative damage [32, 33].

Stilbene reduces fat accumulation and inhibits adipogenesis [35], reduces inflammation brought on by obesity in adipocytes [36], and increases the activity of PGC1 α , a receptor that activates peroxisome proliferator-activated receptor-gamma coactivator 1 alpha (PGC1 α), which is involved in gluconeogenesis and free fatty acid oxidation, and activates SIRT-1, a silent mating type information regulator that is involved in lipolysis and fat loss in addition to mitochondrial biogenesis [37].

Additionally, stilbene decreases the expression of cyclic Amp-dependent activating transcription factor-4 (AFT-4) and pseudokinase Tribbles homolog 3 (TRIB3), which improves insulin sensitivity (IR) and lowers endoplasmic reticulum stress (ERS) [38]. It increases heme-oxygenase-1 (HO-1), an activity that leads to the upregulation of enzymatic antioxidants like catalase (CAT), superoxide dismutase (SOD), and glutathione peroxidase (GPX) [39]. It downregulates protein kinase-like ER kinase (PERK) and eukaryotic initiation factor 2 alpha (eIF2 alpha), implicated in ERS and IR [38]. The hepatic and pancreatic cell damage seen in this study, which was produced by STZ and stimulated by hyperglycemia, may be repaired by these stilbene bioactivities.

4. CONCLUSION

Administration of cocoyam flour in significant quantities does not appear to be effective in controlling blood glucose levels in diabetic rats induced by streptozotocin (STZ). That said, it functions similarly to popular diabetes drugs like metformin in terms of how it affects the kidney, liver, and pancreas. Based on the possible benefits of cocoyam in lowering the risk of diabetic hepato-renal issues, the results suggest that patients with diabetes should be encouraged to take this food.

Cocoyam's benefits for the pancreas and liver suggest that it may be a good dietary supplement or adjunctive treatment for persons with diabetes, even though large concentrations of the fruit may not be the best strategy to lower blood sugar.

As usual, before beginning any significant dietary or drug modifications, diabetics should consult with physicians. It is suggested that you carry out additional research to determine the effect of cocoyam on issues related to diabetes and any possible interactions with other anti-diabetic drugs.

ETHICAL APPROVAL (WHEREEVER APPLICABLE)

Ethical Approval was obtained from the Faculty of Basic Medical Sciences Ethical Committee

REFERENCES

- [1] Sun, H., Saeedi, P., Karuranga, S., Pinkepank, M., Ogurtsova, K., Duncan, B.B., Stein, C., Basit, A., Chan, J.C.N., Mbanya, J.C., Pavkov, M.E., Ramachandaran, A., Wild, S.H., James, S., Herman, W.H., Zhang, P., Bommer, C., Kuo, S., Boyko, E.J., Maqliano, D. J., (2022). IDF Diabetes Atlas: Global, Regional, and Country-level diabetes prevalence estimates for 2021 and projections for 2045. *Diabetes Research and Clinical Practice*, 183, 109119. <https://doi.org/10.1016/j.diabres.2021.109119>
- [2] Van Belle, T.L., Coppieters, K.T. and Von Herrath, M.G. (2011). Type 1 diabetes: aetiology, immunology, and therapeutic strategies. *Physiological Reviews*, 91:1.
- [3] Lin, X., Xu, Y., Pan, X., *et al.*, (2020) Global, regional, and national burden and trend of diabetes in 195 countries and territories: an analysis from 1990 to 2025. *Sci Rep*, 10, 14790
- [4] Kirigia JM, Sambo HB, Sambo LG and Barry SP. (2009). Economic burden of diabetes mellitus in the WHO African region. *BMC International Health and Human Rights*, 9:6.
- [5] Ashcroft, F.M. and S.J.H. Ashcroft, (1992). *Insulin, Molecular Biology to Pathology*. Oxford University Press. pp 266-284.
- [6] Sobngwi E, Mauvais-Jarvis F, Vexiau P, Mbanya JC and Gautier JF. (2001). Diabetes in Africans. Epidemiology and clinical specificities. *Diabetes Metab.*, 27(6):628-634.
- [7] Piero MN. (2006) Hypoglycemic effects of some Kenyan plants traditionally used in the management of diabetes mellitus in the eastern province, MSc thesis, Kenyatta University

- [8] Wylie-Rosett, J and Delahanty, L.M (2017) Nutrition in the Prevention and Treatment of Disease (Fourth Edition) Pp 691-707. <https://doi.org/10.1016/B978-0-12-802928-2.00031-X>
- [9] Forouhi, G.N., Misra, A., Mohan, V., Taylor, R., Yancy, W (2018) Dietary and nutritional approaches for prevention and management of type 2 Diabetes, Science and Politics of Nutrition, BMJ 361 Doi:<https://doi.org/10.1136/bmj.k2234>
- [10] Piero MN, Njagi JM, Kibiti CM, Ngeranwa JJN, Njagi ENM and Miriti PM. (2012). The Role of Vitamins and Mineral Elements in Management of Type 2 Diabetes Mellitus: A Review South As. J. Biol.Sci., 2(Supp. 1):107 –115.
- [11] Merida L.A., Mattos E.B., Correa A.C., Pereira P.R., Paschoalin V.M., Pinho M.F., Vericimo M.A (2018). Tarin stimulates granulocyte growth in bone marrow cell cultures and minimizes immunosuppression by cyclophosphamide in mice. *PLoS ONE*. 13:e0206240. doi: 10.1371/journal.pone.0206240
- [12] Chukwuma C.I., Islam M.S., Amonsou E.O. (2018) A comparative study on the physicochemical, anti-oxidative, anti-hyperglycemic and anti-lipidemic properties of amadumbe (*Colocasia esculenta*) and okra (*Abelmoschus esculentus*) mucilage. *J. Food Biochem.* 42:e12601. doi: 10.1111/jfbc.12601
- [13] Prabhakar, P.K., and Doble, M (2008) A Target Based Therapeutic Approach Towards Diabetes Mellitus Using Medicinal Plants. Current Diabetes Reviews, 291-308. Bentham Science Publishers Ltd.
- [14] Kumawat, N.S., Chaudhari, S.P., Wani, N.S., Deshmukh, T.A., & Patil, V.R. (2010). Antidiabetic activity of ethanol extract of *Colocasia esculenta* leaves in alloxan-induced diabetic rats. *International Journal of Pharmaceutical Technique Research*, 2,1246–1249.
- [15] Eleazu CO, Iroaganachi M & Eleazu KC (2013). Ameliorative potentials of cocoyam (*Colocasia esculenta* L.) and unripe plantain (*Musa paradisiaca* L.) on the relative tissue weights of streptozotocin-induced diabetic rats. *J Diabetes Res.* 1–8 <https://doi.org/10.1155/2013/160964>
- [16] Eleazu CO, Eleazu KC & Iroaganachi MA (2016). Effect of cocoyam (*Colocasia esculenta*), unripe plantain (*Musa paradisiaca*) or their combination on glycated haemoglobin, lipogenic enzymes, and lipid metabolism of streptozotocin-induced diabetic rats, *Pharmaceutical Biology*, 54(1), 91-97, DOI: [10.3109/13880209.2015.1016181](https://doi.org/10.3109/13880209.2015.1016181)
- [17] Shakya, A.K. (2016) Medicinal plants: Future source of new drugs *International Journal of Herbal Medicine*, 4(4): 59-64
- [18] NRC (National Research Council) (1985) Guide for the care and use of laboratory Animals. Bethesda (MD): *National Institute of Health*, 8523
- [19] Nair AB, Jacob S. (2016) A simple practice guide for dose conversion between animals and humans. *J Basic Clinical Pharmacology*, 7(2):27-31. doi: 10.4103/0976-0105.177703.
- [20] Pneu-Dart (2023) Dosage Calculation. <https://www.pneudart.com>. Accessed 14th April 2024

- [21] Nnadi, N.N., Ezekwesili, C.N., Ezeigwe, O.C (2022) Effects of Formulated Unripe Plantain and Millet Dietary Feeds in Alloxan-Induced Diabetic Albino Rats. *International Journal of Innovative Research and Advanced Studies (IJIRAS)*, 9 (6)
- [22] Oulai, A.C., Dje, K.M., Eba, K.P., Adima, A.A., Kouadio, E.J.P (2018) Chemical composition, antioxidant and antimicrobial activities of capsicum annum var. annum concentrated extract obtained by reverse osmosis. *GSC Biological and Pharmaceutical Sciences*, 05(02): 116-125
- [23] Kurniawan Y.S, Priyanga, K.T.A; Krisbiantoro, P.A., Imawan, A.C (2021) Green chemistry influences in organic synthesis: A review. *Journal of Multidisciplinary Applied Natural Science*, 1:1-12
- [24] Wada, E., Feyissa, T., Tesfaye, K (2019) Proximate, Mineral and Antinutrient Contents of Cocoyam (*Xanthosoma sagittifolium* (L.) Schott) from Ethiopia. *International Journal of Food Science*, Vol. 2019. Article ID 8965476
- [25] Coronell-Tovar, D.C., Chavez-Jauregui, R.N., Bosques-Vega, A., Lopez-Moreno, M.L (2019) Characterization of cocoyam (*Xanthosoma* spp.) corn flour from the Nazareno cultivar. *Food Science and Technology, Campinas*, 39(2): 349-357.
- [26] Aini F., Maritsa, H., Riany, H (2019) Antioxidant activity of niphendophytic fungi (*Nyphafruiticans* Wurmb) from Tanjung Jabung Timur Jambi. *Jurnal Biota*, 5: 104-109.
- [27] Kurniawan Y.S, Priyanga, K.T.A; Krisbiantoro, P.A., Imawan, A.C (2021) Green chemistry influences in organic synthesis: A review. *Journal of Multidisciplinary Applied Natural Science*, 1:1-12
- [28] Amrulloh, H., Fatiqin, A., Simanjuntak, W., Afriyani, H., Annissa, A. (2021) Bioactivities of nanoscale magnesium oxide prepared using aqueous extract of *Moringaoleifera* leaves as a green agent. *Advances in Natural Sciences: Nanoscience and Nanotechnology*, 12:015006
- [29] Jiang, Y., Shui, J., Zhang, B., Chin, J., Yue, R. (2020) The potential roles of artemisinin and its derivatives in the treatment of type 2 diabetes mellitus. *Frontiers in Pharmacology*, 11: 585487
- [30] Farrag, E.A.E; Hammad, M.O., Safwat, S.M., Hamed, S and Hellal, D (2023) Artemisinin attenuates type 2 diabetic cardiomyopathy of AGE-RAGE/HMGB-1 Signaling pathway. *Scientific Reports*, 13. Article 11043.
- [31] Teoh SL, Latiff AA, Das S. (2009) A histological study of the structural changes in the liver of streptozotocin-induced diabetic rats treated with or without *Momordica charantia* (bitter gourd). *Clin Ter.*, 160 (4):283-286.
- [32] Johnson, M.K., & Loo, G. (2000). Effects of epigallocatechin gallate and quercetin on oxidative damage to cellular DNA. *Mutation Research*, 459, 211-218.
- [33] Alia, M., Mateos R., Ramos S., Lecumberri E., Bravo L., Goya L. (2006) Influence of quercetin and rutin on growth and antioxidant defence system of a

- human hepatoma cell line (HepG2) *European. Journal of Nutrition*. 2006; 45, 19–28. doi, 10.1007/s00394-005-0558-7.
- [34] Cotelle, N. (2001) Role of flavonoids in oxidative stress. *Curr. Top. Med. Chem.* 1,569–590. doi, 10.2174/1568026013394750.
- [35] Kwon, Y.I., Apostolidis, E., & Shetty, K. (2007). Evaluation of pepper (*Capsicum annuum*) for management of diabetes and hypertension. *Journal Food Biochemistry*, 31,370–385.
- [36] Yang, Z., Wang, M., Zhang, Y., Cai, F., Jiang, B., Zha, W., Yu, W. (2020). Metformin ameliorates diabetic cardiomyopathy by activating the PK2/PKR pathway. *Frontiers in Physiology*, 11:425.
- [37] Ungvari, Z., Sonntag, W.E., de Cabo, R., Baur, J.A., and Csiszar, A (2011) Mitochondrial Protection by Resveratrol. *Exercise Sport Science Review*, 39(3): 128 – 132. Doi: 10.1097/JES.ob013e3182141f80.
- [38] Zhao, H., Zhang, Y., Shu, L., Song, G., and Ma, H (2019) Resveratrol reduces liver endoplasmic reticulum stress and improves insulin sensitivity in vivo and in vitro. *Drug Design, Development and Therapy*, 1473-1485, Doi: 10.2147/DDDT.S203833.
- [39] Bellaver B., Bobermin, L.D., Souza, D.G., Rodrigues, M.D.N., de Assis, A.M., Wajner, M., Goncalves, C., Souza, D.O., Quincozes-Santos, A (2016) Signaling mechanisms underlying glioprotective effects of resveratrol against mitochondrial dysfunction. *Biochimica et Biophysica Acta (BBA) – Molecular Basis of Disease*, 1862 (9): 1827-1838