

# Case report on diaphragmatic hernia with renal ectopia as a cause of low back pain and dyspnea

## ABSTRACT

**Aims:**In this case report, we evaluate a case of a diaphragmatic hernia with renal ectopia.

**Presentation of Case:** We present the case of an adult, male patient with low back discomfort and dyspnea, imaging techniques revealed a mediastinal mass and a large left diaphragmatic defect with renal ectopia.

**Discussion:**This case emphasizes the importance to rule out renal ectopia in individuals with atypical symptoms. Renal ectopia is a rare condition, becoming more frequent in adulthood because of the increased use of image acquisitions. A left diaphragmatic defect and an extension of the superior renal pole into the thorax were seen on our patient's imaging, which is consistent with intrathoracic renal ectopia. While many people with good renal function have no symptoms, issues including reflux and kidney stones can arise. In these circumstances, individualized, multidisciplinary care is required, and in more severe cases, surgery may be necessary.

**Conclusion:**Even though intrathoracic renal ectopia is uncommon, this case emphasizes the value of doing a thorough assessment, considering congenital defects such renal ectopia, in individuals presenting with atypical symptoms.

Keywords: Diaphragmatic hernia, renal ectopia, intrathoracic kidney, lumbalgia.

## 1. INTRODUCTION

Rarely, congenital diaphragmatic hernia might manifest as renal ectopia. In live newborns, congenital diaphragmatic hernias affect 1 in 2000, with the left posterolateral (Bochdalek) hernia being more prevalent (1). An intrathoracic kidney is related with a 0.25% incidence of Bochdalek hernias (2). In postmortem examinations, isolated renal ectopia has been found to occur 1 in 500 individuals, while intrathoracic renal ectopia is the least common type, accounting for 0.01% of cases (3). Therefore, it has a reported incidence of less than 5 per million births (4).

There is a hypothesis that suggests the connection between delayed mesonephric involution or delayed closure of the pleuroperitoneal membranes and faster ascent in intrathoracic renal ectopia (5). The kidneys are originally found in the pelvis during embryogenesis; when the caudal portion of the embryo grows in respect to the cranial portion, they subsequently ascend in the abdominal cavity. When the kidneys reach the adrenal glands, the ascent ends. The liver and the superiorly positioned adrenal glands physically block both kidneys from physically rising higher. Consequently, the ascending growing kidney can infrequently "overstep" and ascend to a higher-than-normal site under situations that alter the development of the liver and adrenal glands, leading to thoracic ectopia (6).

10% of cases are bilateral, and it is more prevalent in men and the left hemithorax (7). Of all occurrences of congenital diaphragmatic hernia, 2% are familial cases, which are

exceedingly rare (8). Has a neonatal death rate of up to 30%, primarily from pulmonary hypoplasia.

Four categories apply to intrathoracic kidneys: 1.- diaphragmatic rupture, 2.- diaphragmatic eventration, 3.- congenital or acquired diaphragmatic hernia, and 4.- intact diaphragm. (9) The renal arteries and ureter normally emerge from the thorax through the foramen of Bochdalek, and the kidneys are always found in the thoracic cavity rather than the pleural space (10).

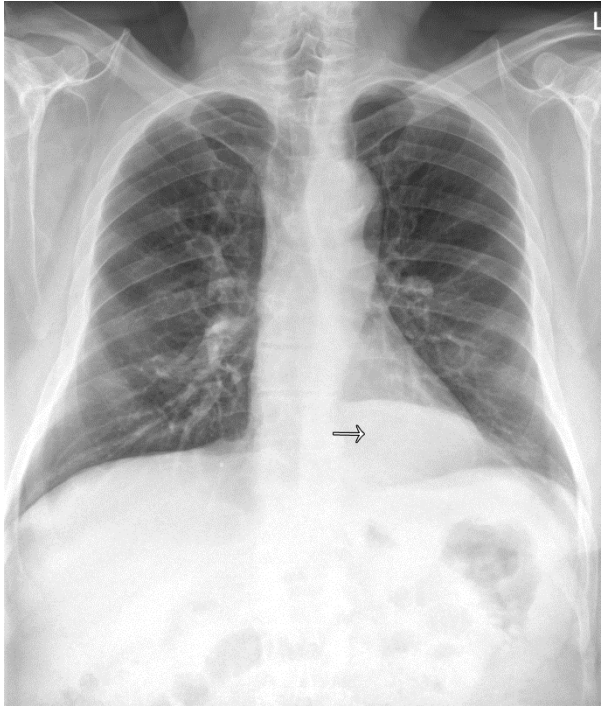
An elongated ureter, a high vascular origin, an anomalous rotation, and a medial deviation of the lower pole are among the associated anomalies of intrathoracic kidneys, which are typically discovered incidentally while the patient has normal renal function (3). There is evidence of a higher propensity for lithogenesis and vesicoureteral reflux. Treatment is not usually required for intrathoracic renal ectopia unless it is accompanied by other anomalies like vesicoureteral reflux or obstruction. Most adult patients with intrathoracic kidneys have benign clinical outcomes and no symptoms (11).

Since computed tomography was first used, there have only been nine cases of malignancy in an ectopic kidney reported (8, 12, 14, 15).

Large defects that occur in the neonatal stage are urgent emergencies that need to be reduced. Open thoracotomy or minimally invasive thoracoscopic repair are two possible treatment options (5, 6).

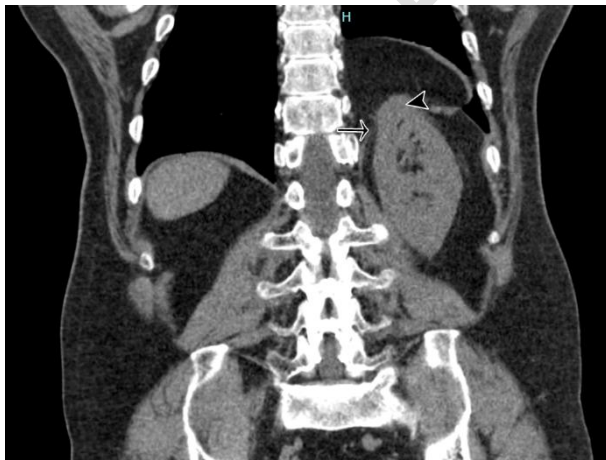## 2. PRESENTATION OF CASE

In the outpatient clinic, a 62-year-old male patient with no notable medical history complained of moderate exertion breathing difficulties and 4 months of left lumbar pain. A chest X-ray was ordered for this reason (figure 1), which showed a soft tissue mass in the mediastinal region. A simple chest tomography was then performed to characterize the findings.



**Figure 1:**A soft tissue mass in the left mediastinal region (→) is visible on the chest X-ray.

Chest tomography revealed a left diaphragmatic defect through which the omental contents protruded, and part of the superior renal pole was contained (figure 2). Compared to the ipsilateral kidney, the left adrenal gland was seen to be situated lower and medially (figure 3).



**Figure 2:**Coronal chest tomography displaying a left diaphragmatic defect (→) with the superior renal pole protruding through it (▶). There was no dilatation or evidence of stones.

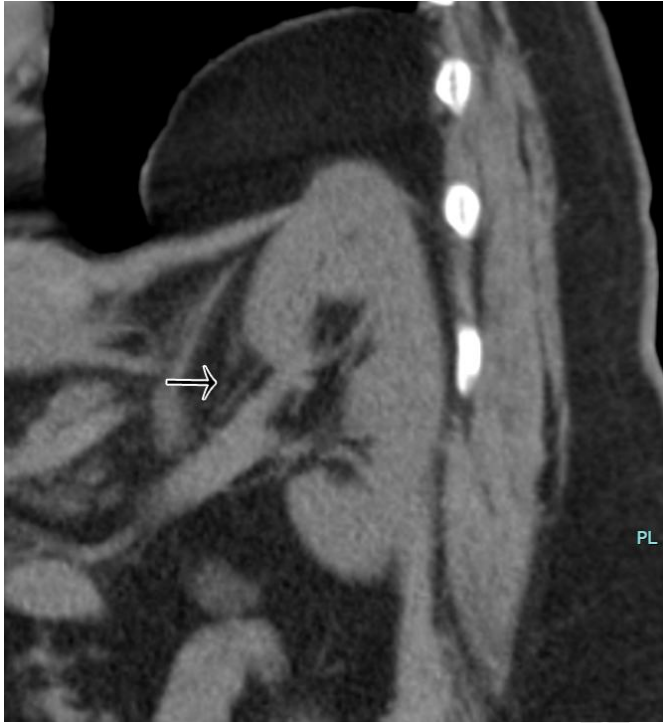

Figure 3. Oblique chest tomography reconstruction showing the left adrenal gland in a medial and inferior displacement relative to its anatomical position(→) while renal vessels are normal.

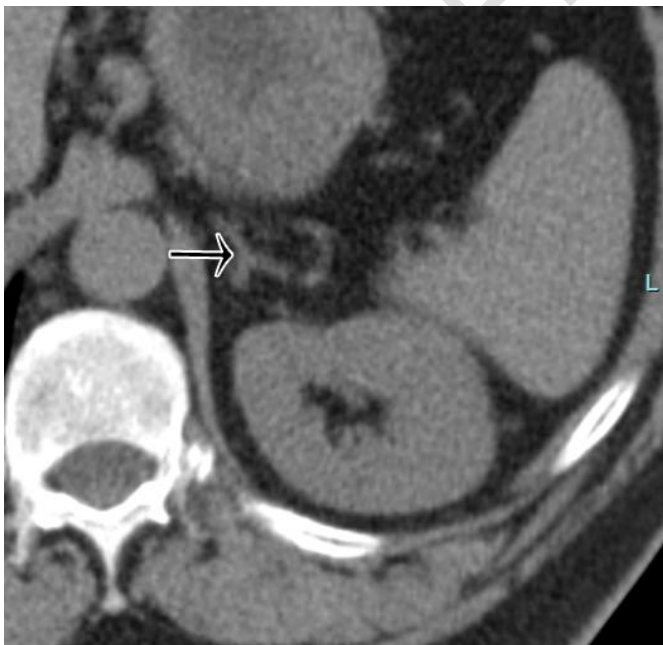

Figure 4. Abdominal CT showing the left adrenal gland in a medial and displaced position towards the interpolar region (→)

### **3. RESULTS AND DISCUSSION**

The case study emphasizes the significance of ruling out renal ectopia in patients exhibiting unusual symptoms like mediastinal masses and lumbar pain. Despite being a rare congenital anomaly, renal ectopia is becoming more often discovered in adults because of the increasing use and availability of imaging techniques.

The imaging results for our patient, which show a left diaphragmatic defect and the superior renal pole protruding through it, are in line with existing medical literature regarding intrathoracic renal ectopia. This kind of renal ectopia is linked to an abnormal ascent of the kidney during embryogenesis, which may lead to an intrathoracic location. The left adrenal gland's atypical location is another defining feature in these instances while the renal vessels maintain their normal relative position through the kidney.

Notably, despite the anatomical anomaly, many people with intrathoracic renal ectopia have normal renal function and no symptoms. On the other hand, there have been documented instances of problems such kidney stones and vesicoureteral reflux. Individualized, multidisciplinary care is necessary for these patients, and surgical procedures are considered in the case of complications or severe symptoms.

In this case, the patient expressed concerns about renal function prognosis and the likelihood of their children inheriting the condition. Our team explained based on available literature the low probability of inheriting the condition and, if inherited, the low likelihood of complications.

After evaluating the case and not finding any related complications, a conservative treatment was initiated with analgesics. The patient was scheduled for an outpatient appointment 7 days later, where dyspnea and lumbar pain subsided. The patient was discharged with a request for laboratory tests focusing on renal function assessment. Subsequent follow-up appointments at 6 and 12 months did not reveal any abnormalities.

### **4. CONCLUSION**

Even though intrathoracic renal ectopia is uncommon, this case emphasizes the value of doing a thorough assessment, considering congenital defects such renal ectopia, in individuals presenting with atypical symptoms.

### **CONSENT**

All authors declare that 'written informed consent was obtained from the patient for publication of this case report and accompanying images.

### **REFERENCES**

1. Donat SM, Donat PE. Intrathoracic kidney: a case report with a review of the world literature. *J Urol* 1988;140(01):131–133.
2. Sesia SB, Haecker F-M. Late-presenting diaphragmatic hernia associated with intrathoracic kidney: tachypnea as a unique clinical sign. *BMJ Case Rep* 2012;2012:x.

3. Karaoglanoglu N, Turkyilmaz A, Eroglu A, Alici HA. Right-sided Bochdalek hernia with intrathoracic kidney. *PediatrSurgInt* 2006;22(12):1029–1031.
4. Chong SL, Chao SM. An unusual cause of mediastinal mass: a case report and literature-review of intrathoracic kidney. *ProcSingaporeHealthcare*2012;2:144–150.
5. Kayıran PG, Gumus T, Kayıran SM, Bilge I, Gurakan B. Ectopic intrathoracic kidney with right-sided congenital diaphragmatic hernia. *J Pediatr* 2013;163(04):1226–1226.e1.
6. Fiaschetti V, Velari L, Gaspari E, Simonetti G. Adult intrathoracic kidney: a case report of Bochdalek hernia. *Case RepMed* 2010;2010. doi: 10.1155/2010/975168. Epub 2010 Aug 30.
7. Chow JS, Benson CB, Lebowitz RL. The clinical significance of an empty renal fossa on prenatal sonography. *J UltrasoundMed* 2005;24(08):1049–1054, quiz 1055–1057.
8. Grotas AB, Phillips JL. Renal mass in solitary, crossed, ectopic pelvic kidney. *Urology* 2009;73(06):1223–1224.
9. Lee CH, Tsai LM, Lin LJ, Chen PS. Intrathoracic kidney and liver secondary to congenital diaphragmatic hernia recognized by transthoracic echocardiography. *Int J Cardiol*2006;113:E73e5.
10. Coşkun F, Cetinkaya M, Cengiz O, Adsan O, Kulaçoğlu S, Eroğlu A. Metastatic carcinoma of the gallbladder due to renal cell carcinoma in the ectopic kidney. *ActaChirBelg* 1995;95(01):56–58.
11. <sup>18</sup> b. Fadaei A, Rezaian S, Tojari F. Intrathoracic kidney presented with chest pain. *Iran J Kidney Dis* 2008;2:160e2.
12. Basoglu T, Canbaz F, Bernay I, Sahin M. Technetium-99m-DTPA images of a renal cell carcinoma arising in a crossed-ectopic fused kidney. *J Nucl Med* 1998;39(06):9A, 949.
13. Angulo JC, Lopez JI, Vilanova JR, Flores N. Intrathoracic kidney and vertebral fusion: a model of combined misdevelopment. *J Urol* 1992;147(05):1351–1353.
14. Fadaei A, Rezaian S, Tojari F. Intrathoracic kidney presented with chest pain. *Iran J Kidney Dis* 2008;2:160e2.
15. Mizzi C, Farrugia D, Choudhry MS. Congenital Diaphragmatic Hernia with Intrathoracic Renal Ectopia: Thoracoscopic Approach for a Complete Anatomical Repair. *European J PediatrSurg Rep.* 2020 Jan;8(1):e74-e76. doi: 10.1055/s-0039-3402741. Epub 2020 Oct 21. PMID: 33101834; PMCID: PMC7577787.