

Concomitant Autoimmune Pancreatitis Type 2 and Colitis Ulcerosa in a 10 years-old girl

Abstract

Autoimmune pancreatitis (AIP) has gained significant attention in recent years, with a notable increase in diagnoses due to the diagnostic utility of immunoglobulin G4 (IgG4). Despite the well-known IgG4-related type 1 AIP, a less recognized subtype known as type 2 AIP exists, which is distinct from type 1 AIP and not associated with IgG4. Type 2 AIP presents similar clinical symptoms and imaging findings as type 1 AIP, making its diagnosis challenging without specific serum markers. Tissue confirmation of neutrophilic injury to the pancreatic ducts, known as a granulocytic epithelial lesion, is crucial for diagnosing type 2 AIP. Some cases of type 2 AIP are linked to inflammatory bowel disease, particularly ulcerative colitis, but the exact relationship between the two conditions remains unclear. Questions remain regarding the pathophysiology of type 2 AIP, the possibility of similar granulocytic injuries in other organs, and the characteristics of pediatric cases. In this case report we present a concomitant autoimmune pancreatitis type 2 and colitis ulcerosa in a 10 years-old girl. The patient's follow-up showed amelioration of the clinical symptoms due to the present medication.

Keywords

Autoimmune-child-colitis-pancreatitis-treatment

Introduction

The term "autoimmune pancreatitis" was first coined in 1995 by Yoshida et al. to describe a form of chronic pancreatitis associated with autoimmune processes that could be confirmed through laboratory, histological, and clinical tests (32). However, as early as 1961, Sarles et al. described a connection between autoimmune phenomena and chronic pancreatitis (4,6,9). Autoimmune pancreatitis (AIP), also known as sclerosing pancreatitis, swelling pancreatitis, or non-alcoholic destructive pancreatitis, is a recently defined disease of the pancreas with characteristic clinical, histological, and morphological changes (9,12,17). Most of the literature on this topic comes from Asia and the USA, but there are also increasing descriptions from Europe, indicating a globally prevalent disease. Regarding the incidence and prevalence, there is still insufficient data in Europe. Overall, the prevalence of AIP in the literature ranges from 5-6% of all chronic pancreatitis cases (14,19,21,24,25). AIP is divided into 2 subtypes: Type 1 - lymphoplasmacytic sclerosing pancreatitis (LPSP) and Type 2 - idiopathic duct-centric pancreatitis (IDCP). Type 1 AIP corresponds to the form initially described in Japan, while Type 2 corresponds to the form more commonly described in Europe (1-29). Although both forms are grouped under the term AIP and respond well to steroids, histologically they represent two different entities. In recent literature, Type 1 AIP is also seen as a pancreatic manifestation of a multi-organ disease, IgG4-related disease (2,6,7,9,15,30,31). The histological picture is characterized by lymphoplasmacytic sclerosing pancreatitis, with infiltration of the pancreas by various types of immune cells, such as CD4-positive T cells and IgG4-producing plasma cells (1-32). Furthermore, there is an increase in IgG4 in the serum, and extrapancreatic manifestations often occur in bile ducts, kidneys, or retroperitoneum. On the other hand, Type 2 AIP is characterized by histology resembling non-alcoholic duct-destructive pancreatitis, with massive infiltration of neutrophils, occasionally forming microabscesses. IgG4 is usually not elevated, and extrapancreatic manifestations are typically absent, but there is a frequent association with chronic inflammatory bowel diseases (especially ulcerative colitis). The pathogenesis of this disease is not yet fully understood, but due to the observed infiltration of immune cells into pancreatic tissue and the excellent response to steroids, an autoimmune process is suspected (1,15,23). There is also a variety of circulating autoantibodies belonging to the IgG subclass 1, such as autoantibodies against lactoferrin, carbonic anhydrase, ubiquitin ligase, trypsin, Helicobacter pylori antigen, among others. However, it remains unclear which of these antibodies are responsible for the pathogenesis and which represent an epiphenomenon of AIP. The physiological IgG4 response is induced by prolonged antigen exposure and controlled by type 2 helper T cells, so the IgG4 elevation is likely an epiphenomenon rather than a cause of AIP (4,9,15,21). However, this entire mechanism, including T cells, may play a role in the pathogenesis. Ota et al. also identified a genetic predisposition for carriers of HLA-DRB1*0405-DQB1*0401 of the HLA class II and ABCF1 proximal to C3-2-11, a telomere of HLA-E, in class I. No ethical issues were found.

Case Report

We are reporting on the above-mentioned patient who was in our inpatient care from January 16, 2024, to January 29, 2024. Autoimmune pancreatitis Type II was the initial diagnosis. The classification according to ICDC: EUS + FNP was not performed. MRCP showed a diffuse edematous pancreatitis with a late enhancement and a long-segment ductal component. ANA was positive (other organ involvement). CED and ANCA were negative. Ulcerative colitis was diagnosed in July 2018 and previously classified as IBDU with a moderate activity. Later it was classified as pancolitis ulcerosa (Paris Classification E4 SO). Moreover, vitamin D deficiency, iron deficiency and obesity (BMI 97th percentile) was found. As a therapeutic procedure, Adalimumab was applied subcutaneously since December 2023, continued – ongoing with Prednisone iv/p.o. since January 2024. Ongoing there were following 3 steroid-dependent flares since diagnosis until December 2023. Mesalazine p.o./pr. Was paused since July 2018. For 10 days, there have been frequent stool passages, 6-7 times alone at night, even more during the day. The stool is bloody and has blood streaks. The patient was seen in the gastroenterology outpatient clinic at home. There was a slightly elevated CRP and significantly elevated serum lipase. Currently, the patient is being treated with Mesalazine and Adalimumab (received 3rd dose on 8th January, now Mesalazine has been paused due to elevated lipase). The patient has lost some weight over many weeks. No reported symptoms related to pancreatitis such as upper abdominal pain, nausea, or vomiting. Current medication included Mesalazine 1500 mg 1 - 0 - 1 p.o.. Allergies were not known.

Clinical Findings and Diagnostic Assessment: 10-year-old female patient; general condition good; nutritional status good; no dehydration. Cardiovascular system: regular rhythm; clear heart sounds. Lungs: Eupnea; auscultation findings: vesicular breath sounds. Abdomen: mild tenderness throughout the lower abdomen and epigastric region; normal bowel sounds; liver not palpable; spleen not palpable. Rectal examination: perianal area normal, no fistula, no fissure visible. Genitalia: not examined. Measurements: Weight 51 kg (95th percentile), height 146 cm (64th percentile), BMI 23.9 kg/m² (97th percentile). Vital signs: Blood pressure 111/72 mmHg; respiratory rate 20/min; pulse oximetry measured oxygen saturation 97%; body temperature 36,4 °C. Diagnostics: PUCAI-Indices were 25 points, at discharge on 0 points. Metabolic diagnostics with amino acid profile (EDTA, serum) was unremarkable. Macro-lipase (serum): was unremarkable. Urine for organic acids: unremarkable. Stool diagnostics showed pancreatic elastase in stool of 501 pg/g stool. There was no evidence of Salmonella, Shigella, Yersinia, or Campylobacter. Sweat test revealed Chloride 10 mmol/ in 50 pl sweat. MR abdomen/ MRCP with contrast agent were performed. Previous ultrasound examinations were available for comparison. Historically suspected acute flare-up in known ulcerative colitis ED 07/2018. Clinically, the patient has had bloody stools for 10 days, elevated CRP and lipase levels. Normal shape and size of the liver with homogeneous parenchyma, no focal intrahepatic lesions. No cholestasis. Unremarkable gallbladder, normal common bile duct diameter. Heterogeneous edematous changes in the pancreatic parenchyma, in the head and body of the pancreas with focal edema zones, homogeneous edematous changes in the tail of the pancreas with significant swelling and associated diffusion restriction suggestive of acute pancreatitis. Decreased enhancement of the edema zones compared to healthy parenchyma in the arterial contrast phase with moderate delayed contrast enhancement. It was interpreted as an autoimmune pancreatitis type II in the context of ulcerative colitis. A dilatation of the Wirsung duct with a maximum diameter of 4 mm with irregularities in the body section was seen. The pancreatic duct was not clearly delineated in the head section. Small cystic lesion in the pancreatic head with a diameter of approximately 3.7 x 3.6 mm were recognized, nonspecific. No perifocal inflammatory reaction, no edema of the peripancreatic fat tissue were seen. Normal-sized homogeneous spleen, small accessory spleen at the hilum with a diameter of approximately 1.3 x 1.3 cm was found. Thickening of the descending colon wall with a diameter of approximately 8 mm and increased contrast enhancement suggestive of acute inflammation was seen. Loss of normal haustration of the descending colon with a bicycle tube-like pattern. An elongation of the sigmoid with a tortuous course and wall thickening was described. No free fluid or free air in the scanned abdomen was found. Numerically increased reactive-enlarged lymph nodes in the peripancreatic fat tissue with a diameter of approximately 1,4 x 1,2 cm at the tail of the pancreas were described. Marked swelling and edematous changes in the tail of the pancreas, heterogeneous edematous changes in the head and body of the pancreas with focal edema zones. A mild dilation of the Wirsung duct with caliber irregularities suggestive of autoimmune pancreatitis Type II in the context of known ulcerative colitis was present. No perifocal inflammatory reaction. Mesenteric lymphadenopathy in the peripancreatic fat tissue and in the liver hilum. Longitudinally thickened descending colon with loss of haustration. Small accessory spleen. No free fluid, no free air.

Therapeutic Procedure

The patient was admitted to the hospital on referral from the pediatric gastroenterology outpatient clinic due to a flare-up of Crohn's disease under ongoing therapy with Adalimumab since December (three doses given) and a significant increase in serum lipase levels. Concerning the pancreatitis there was reproducible epigastric tenderness with significantly elevated serum lipase, consistent with the suspected diagnosis. Long-term therapy with Mesalazine had already been paused due to the differential diagnosis of drug-induced toxicity. Due to the known colitis ulcerosa, an MRCP was performed, revealing a typical pattern for autoimmune pancreatitis with a diffuse heterogeneous pancreatic edema with focal inflammation of the entire organ, emphasizing the tail, and showing classic contrast kinetics for AIP, as well as a long segmental ductal component with caliber fluctuations and strictures without significant dilation (<5mm). There were no signs of accompanying cholangitis. Incidentally, criteria for active ulcerative colitis were also found. For a more precise classification of suspected AIP Type II, additional diagnostic criteria according to ICDC were applied in addition to the typical imaging findings for the disease, a positive OOI (other organ involvement) criterion in the context of colitis was present, and IgG4 levels were not elevated. Despite a highly suggestive constellation for the disease and the patient's young age, a histological confirmation through endosonographically guided fine-needle biopsy was not pursued, considering the risks and benefits. The

response to steroids, another diagnostic criterion, was to be evaluated secondarily and was positive. There were no indications of other autoimmune diseases such as SLE, celiac disease, or type 1 diabetes, and a metabolic disorder was ruled out based on normal lipid, amino acid, and organic acid profiles. Extensive infectious diagnostics did not yield any pathogens. Clinically and laboratory-wise, there was no evidence of endocrine or exocrine pancreatic insufficiency, and no signs of significant exudative enteropathy with normal alpha-1 antitrypsin in the stool. Serum macro-lipase levels were normal. The question then arose about the most effective and ideally evidence-based anti-inflammatory therapy with a manageable side effect profile, which had to be carefully considered in the context of the ongoing flare-up of Crohn's disease under Adalimumab therapy. Despite extensive literature and publication research, robust data or experiences for evidence-based therapy selection in similar cases were not found. Intensive exchange in recognized specialist circles cannot be clearly proven. The best recommendation is to identify steroids, azathioprine (which was not desired by the family in the fall of 2023 regarding CED) and the use of TNF-alpha antibody therapies. Concerning CED upon admission, there was a moderate activity. A highly florid pancolitis ulcerosa was found endoscopically, and therapy with Adalimumab was initiated. Currently, a significantly elevated fecal calprotectin was detectable, and sonographically, an active pancolitis was observed. Criteria for toxic megacolon were not present. Mesalazine was paused as mentioned above due to pancreatitis. After considering the STRIDE-II criteria, an final evaluation of the Adalimumab therapy was not possible at the current time. A treatment response can be expected by week 6, and remission development by week 11. The therapeutic strategy was chosen considering both conditions as follows: Adalimumab was continued at 40 mg s.c. every 2 weeks. The currently requested drug monitoring, primarily to exclude ADAs, was unfortunately not available due to an error in sample processing by the laboratory. We also started a systemic intravenous therapy with Prednisolone, which was administered intravenously for 6 days, then switched to oral administration upon discharge and should be tapered according to the schedule below. The prospect of maintaining remission after tapering steroids is generally considered good. Azathioprine was not considered due to family concerns about the side effect profile and the established therapy with the TNF-alpha inhibitor. Clinically, the patient was always in sufficient general condition, with stable vital signs and no fever. Enteral nutrition was not paused due to the clinically mild pancreatitis, and it was well tolerated. Analgesic measures were taken, and temporary intravenous fluid administration was provided, which was no longer necessary once a daily drinking amount of 2l was reached. Clinical symptoms improved under treatment measures for both pancreatitis and CED, with serum lipase levels decreasing significantly. Pneumocystis jirovecii prophylaxis was omitted according to guidelines due to dual immunosuppressive therapy. Finally, on 29.01.2024, discharge to outpatient follow-up care was possible. Mesalazine was gradually reintroduced under laboratory monitoring after complete normalization of serum lipase and favorable clinical course, with the oral target dose established in the low therapeutic range of 50 mg/kg/day. Subsequently, an outpatient appointment was performed for further genetic differential diagnosis of hereditary pancreatitis (PRSS1, CTRC, CFTR, SPINK1, CPA1, CEL, PNLIP, CASR) and CED. Inclusion in the multi-omics study, as VEOIBD is present with onset age < 6 years. A therapy review will take place, and the next steps was planned and discussed with the family of the patient. Medication at discharge were as following: Adalimumab every 2 weeks at 40 mg s.c.; Prednisolone tapering schedule p.o. from discharge; Omeprazole 10 mg once daily orally for the duration of the steroid therapy, then discontinued.

Discussion

The diagnosis of AIP, a rare form of pancreatitis with autoimmune features, is often difficult. AIP-1 and AIP-2, distinct types of AIP classified by ICDC, must be differentiated when AIP is suspected. Due to the nonspecific symptoms of both types and the potential overlap with more serious conditions like pancreatic cancer, research is needed to develop precise tools for differential diagnosis without biopsy. Understanding the etiology of AIP is crucial for developing new treatment targets and improving management. The immune response plays a key role in AIP development. AIP-1 involves both innate and adaptive immunity, with the role of IgG4 in disease progression still unclear. The pathophysiology of AIP-2 is less understood. Steroids are the mainstay of AIP treatment, with high doses of methylprednisolone often leading to remission. Relapse is common, especially in AIP-1, prompting ongoing discussions on steroid treatment duration and the search for alternative therapies. Knowledge of the disease's pathophysiology can help identify potential treatment targets. Steroid-free immunomodulatory medications like azathioprine, 6-mercaptopurine, or mycophenolate may be used to maintain remission. Azathioprine, commonly used in various autoimmune conditions, has shown promise in preventing AIP relapse. However, concerns about its safety in AIP patients have been raised, with reports of AZA-induced acute pancreatitis in some cases. Studies have highlighted the increased risk of acute pancreatitis in AZA users, particularly in certain conditions like Crohn's disease. Caution is advised when using AZA in AIP patients, considering individual medical histories. Immunotherapy, including B-cell depletion therapy with rituximab (RTX), has emerged as an effective approach for AIP management. RTX has shown efficacy in producing and maintaining remission and treating relapse in patients intolerant to corticosteroids. Anti-TNF antibodies and RTX can be used for steroid-resistant AIP-1 variants and relapse. JAK/STAT inhibition has shown promise in reducing cellular proliferation and may be a potential therapeutic direction for AIP treatment, although further research is needed to confirm its effectiveness and safety. Novel biologic drugs for AIP-2 treatment are limited to specific scenarios, warranting further investigations.

Conclusion

Autoimmune pancreatitis is often associated with other autoimmune conditions affecting various organs. Treatment with steroids and Adalimumab is effective, distinguishing it from pancreatic cancer, a potential differential diagnosis. Different treatment options like colchicine were performed successfully in recent years (29). Prompt diagnosis is crucial, particularly when the bile ducts are involved, to prevent or address cholangitis before or after surgery. The association of autoimmune pancreatitis type 2 and colitis ulcerosa was described in literature and this is another rare case of a 10 years-old girl with these concomitant diseases (2,15).

Informed Consent

The parents and the patient gave informed consent

Limitations

Further genetic testing for hereditary pancreatitis (PRSS1, CTSC, CFTR, SPINK1, CPA1, CEL, PNLIP, CASR) and CED was not performed to date of publication and has to be performed till age 6.

References

- (1) de Pretis N, Frulloni L. Autoimmune pancreatitis type 2. *Curr Opin Gastroenterol*. 2020 Sep;36(5):417-420. doi: 10.1097/MOG.0000000000000655. PMID: 32618613.
- (2) Nan N, Wang D. Type 2 autoimmune pancreatitis associated with ulcerative colitis. *Front Immunol*. 2023 Dec;14:1288390. doi: 10.3389/fimmu.2023.1288390. PMID: 38124742; PMCID: PMC10731018.
- (3) Zen Y. Type 2 Autoimmune Pancreatitis: Consensus and Controversies. *Gut Liver*. 2022 May 15;16(3):357-365. doi: 10.5009/gnl210241. PMID: 34670874; PMCID: PMC9099380.
- (4) Li Y, Song H, Meng X, Li R, Leung PSC, Gershwin ME, Zhang S, Sun S, Song J. Autoimmune pancreatitis type 2 (idiopathic duct-centric pancreatitis): A comprehensive review. *J Autoimmun*. 2023 Oct 10;140:103121. doi: 10.1016/j.jaut.2023.103121. Epub ahead of print. PMID: 37826920.
- (5) Nista EC, De Lucia SS, Manilla V, Schepis T, Pellegrino A, Ojetti V, Pignataro G, Zileri Dal Verme L, Franceschi F, Gasbarrini A, Candelli M. Autoimmune Pancreatitis: From Pathogenesis to Treatment. *Int J Mol Sci*. 2022 Oct 21;23(20):12667. doi: 10.3390/ijms232012667. PMID: 36293522; PMCID: PMC9604056.
- (6) Uchida K, Okazaki K. Current status of type 1 (IgG4-related) autoimmune pancreatitis. *J Gastroenterol*. 2022 Oct;57(10):695-708. doi: 10.1007/s00535-022-01891-7. Epub 2022 Aug 2. PMID: 35916965; PMCID: PMC9522839.
- (7) Onweni C, Balagani H, Treece JM, Addo Yobo E, Patel A, Pheemister J, Srinath M, Young MF. Autoimmune Pancreatitis Type 2: Case Report. *J Investig Med High Impact Case Rep*. 2017 Oct 10;5(4):2324709617734245. doi: 10.1177/2324709617734245. PMID: 29051892; PMCID: PMC5637967.
- (8) Gupta R, Neyaz A, Chougule A, Akita M, Zen Y, Forcione D, Castillo CF, Ferrone CR, Deshpande V. Autoimmune Pancreatitis Type 2: Diagnostic Utility of PD-L1 Immunohistochemistry. *Am J Surg Pathol*. 2019 Jul;43(7):898-906. doi: 10.1097/PAS.0000000000001282. PMID: 31135488.
- (9) Okazaki K, Kawa S, Kamisawa T, Ikeura T, Itoi T, Ito T, Inui K, Irisawa A, Uchida K, Ohara H, Kubota K, Kodama Y, Shimizu K, Tonozuka R, Nakazawa T, Nishino T, Notohara K, Fujinaga Y, Masamune A, Yamamoto H, Watanabe T, Nishiyama T, Kawano M, Shiratori K, Shimosegawa T, Takeyama Y; Members of the Research Committee for IgG4-related Disease supported by the Ministry of Health, Labour, Welfare of Japan, Japan Pancreas Society. Amendment of the Japanese consensus guidelines for autoimmune pancreatitis, 2020. *J Gastroenterol*. 2022 Apr;57(4):225-245. doi: 10.1007/s00535-022-01857-9. Epub 2022 Feb 22. PMID: 35192048; PMCID: PMC8938398.
- (10) Ketwaroo GA, Sheth S. Autoimmune pancreatitis. *Gastroenterol Rep (Oxf)*. 2013 Jul;1(1):27-32. doi: 10.1093/gastro/got011. Epub 2013 Apr 4. PMID: 24759664; PMCID: PMC3768278.
- (11) Patel Z, Patel S, Grendell J, Marciano T. Type 2 autoimmune pancreatitis: case report of a 9-year-old female and a review of the literature. *Clin J Gastroenterol*. 2015 Dec;8(6):421-5. doi: 10.1007/s12328-015-0615-6. Epub 2015 Nov 21. PMID: 26590828.
- (12) SenosiainLalstra C, ForunyOlcina JR. Pancreatitis autoimmune [Autoimmune pancreatitis]. *Gastroenterol Hepatol*. 2015 Nov;38(9):549-55. Spanish. doi: 10.1016/j.gastrohep.2015.01.006. Epub 2015 Mar 20. PMID: 25799073.
- (13) Petersen B, Schaffalitzky de Muckadell OB. [Autoimmune pancreatitis]. *UgeskrLaeger*. 2019 Nov 11;181(46):V07190398. Danish. PMID: 31791461.
- (14) Ito T, Ikeura T, Notohara K, Masuda M, Nakamaru K, Nakayama S, Shimatani M, Takaoka M, Okazaki K, Naganuma M. A case of type 2 autoimmune pancreatitis with spontaneous remission. *Clin J Gastroenterol*. 2023 Apr;16(2):297-302. doi: 10.1007/s12328-022-01753-y. Epub 2023 Jan 25. PMID: 36696084.
- (15) Nikolic S, Lanzillotta M, Panic N, Brismar TB, Moro CF, Capurso G, Della Torre E, Löhr JM, Vujasinovic M. Unraveling the relationship between autoimmune pancreatitis type 2 and inflammatory bowel disease: Results from two centers and systematic review of the literature.

- United European Gastroenterol J. 2022 Jun;10(5):496-506. doi: 10.1002/ueg2.12237. Epub 2022 May 8. PMID: 35526270; PMCID: PMC9427095.
- (16) Blaho M, Dítě P, Kunovský L, Kianička B. Autoimmune pancreatitis - An ongoing challenge. *Adv Med Sci.* 2020 Sep;65(2):403-408. doi: 10.1016/j.advms.2020.07.002. Epub 2020 Aug 14. PMID: 32805624.
- (17) Pelaez-Luna M, Soriano-Rios A, Lira-Treviño AC, Uscanga-Domínguez L. Steroid-responsive pancreatitides. *World J Clin Cases.* 2020 Aug 26;8(16):3411-3430. doi: 10.12998/wjcc.v8.i16.3411. PMID: 32913848; PMCID: PMC7457102.
- (18) Ito T, Ikeura T, Notohara K, Masuda M, Nakamaru K, Nakayama S, Shimatani M, Takaoka M, Okazaki K, Naganuma M. A case of type 2 autoimmune pancreatitis with spontaneous remission. *Clin J Gastroenterol.* 2023 Apr;16(2):297-302. doi: 10.1007/s12328-022-01753-y. Epub 2023 Jan 25. PMID: 36696084.
- (19) Ketikoglou I, Moulakakis A. Autoimmune pancreatitis. *Dig Liver Dis.* 2005 Mar;37(3):211-5. doi: 10.1016/j.dld.2004.09.025. Epub 2004 Dec 15. PMID: 15888288.
- (20) Blaho M, Dítě P, Kunovský L, Kianička B. Autoimmune pancreatitis - An ongoing challenge. *Adv Med Sci.* 2020 Sep;65(2):403-408. doi: 10.1016/j.advms.2020.07.002. Epub 2020 Aug 14. PMID: 32805624.
- (21) Ohno E, Hirooka Y. Encyclopedia of autoimmune pancreatitis: this is all we need. *J Med Ultrason* (2001). 2021 Oct;48(4):523-524. doi: 10.1007/s10396-021-01150-x. Epub 2021 Nov 10. PMID: 34755227.
- (22) Toomey DP, Swan N, Torreggiani W, Conlon KC. Autoimmune pancreatitis. *Br J Surg.* 2007 Sep;94(9):1067-74. doi: 10.1002/bjs.5893. PMID: 17701958.
- (23) Estrada P, Pfau P. Diagnosing autoimmune pancreatitis: choosing your weapon. *GastrointestEndosc.* 2020 Feb;91(2):382-384. doi: 10.1016/j.gie.2019.11.037. Epub 2020 Jan 22. PMID: 32036944.
- (24) Yoshikawa T, Watanabe T, Kamata K, Hara A, Minaga K, Kudo M. Intestinal Dysbiosis and Autoimmune Pancreatitis. *Front Immunol.* 2021 Mar 23;12:621532. doi: 10.3389/fimmu.2021.621532. PMID: 33833754; PMCID: PMC8021793.
- (25) de Pretis N, Amodio A, Frulloni L. Updates in the field of autoimmune pancreatitis: a clinical guide. *Expert Rev GastroenterolHepatol.* 2018 Jul;12(7):705-709. doi: 10.1080/17474124.2018.1489230. Epub 2018 Jun 26. PMID: 29923430.
- (26) Fan BG, Andrén-Sandberg A. Autoimmune pancreatitis. *N Am J Med Sci.* 2009 Sep;1(4):148-51. PMID: 22666688; PMCID: PMC3364658.
- (27) Hart PA, Krishna SG, Okazaki K. Diagnosis and Management of Autoimmune Pancreatitis. *CurrTreat Options Gastroenterol.* 2017 Dec;15(4):538-547. doi: 10.1007/s11938-017-0147-x. PMID: 28842855.
- (28) de Pretis N, De Marchi G, Frulloni L. Diagnosis and treatment of autoimmune pancreatitis. *CurrOpinGastroenterol.* 2018 Sep;34(5):362-366. doi: 10.1097/MOG.0000000000000454. PMID: 29901516.
- (29) Chiabrando F, Lanzillotta M, Palumbo D, Pedica F, Caruso M, Capurso G, Della-Torre E. Treating Type 2 Autoimmune Pancreatitis With Colchicine: A Case Series. *Ann Intern Med.* 2021 Dec;174(12):1775-1776. doi: 10.7326/L21-0281. Epub 2021 Oct 12. PMID: 34633831.
- (30) Kutlieva, G. J., Elova, N. A., Turaeva, B. I., Nurmukhamedova, D. K. and Tulaganov, B. S. (2021) "Study of the Influence of Local Strains of Lactobacillus on the Experimental Model of Ulcerative Colitis", *Journal of Pharmaceutical Research International*, 33(16), pp. 1–11. doi: 10.9734/jpri/2021/v33i1631290.
- (31) Magadmi, R. M., Aljahdali, F. H., Alsawy, M., Ali, A. S. and Kamel, F. O. (2020) "Metformin as an Adjuvant Therapy Attenuates Dextran Sulphate Sodium-induced Acute Colitis in Rats", *Journal of Pharmaceutical Research International*, 32(10), pp. 84–96. doi: 10.9734/jpri/2020/v32i1030496.
- (32) Yoshida K, Toki F, Takeuchi T, Watanabe S, Shiratori K, Hayashi N. Chronic pancreatitis caused by an autoimmune abnormality. Proposal of the concept of autoimmune pancreatitis. *Dig Dis Sci.* 1995 Jul;40(7):1561-8. doi: 10.1007/BF02285209. PMID: 7628283.

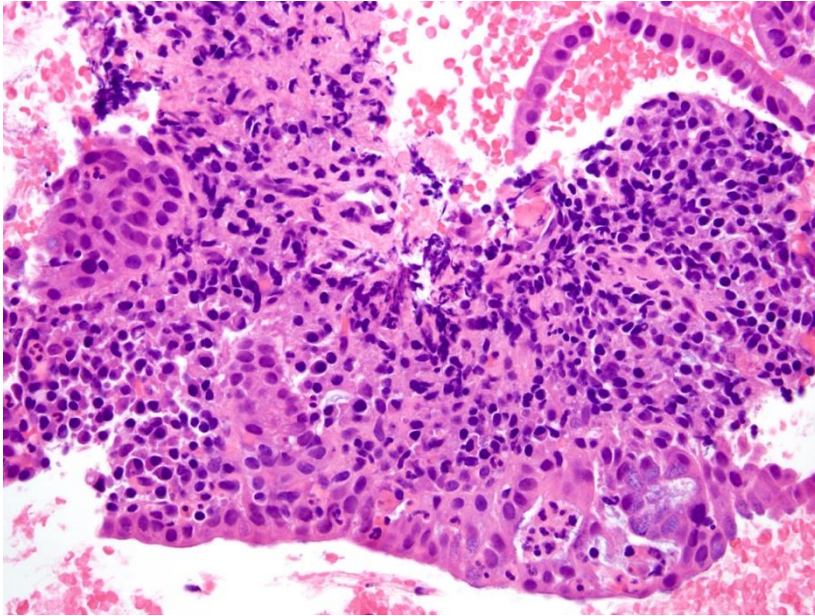


Figure 1: High power view of duct lymphoplasmacytic infiltrate and neutrophils infiltrating the pancreatic duct epithelium in autoimmune pancreatitis type 2

UNDER PEER REVIEW