

Original Research Article

Effect of Ethanolic Leaf Extract of *Piper guineense* (Uziza) on the Kidneys of Paraquat-Induced Adult Male Wistar Rats

Abstract

Background: Paraquat (PQ) is one of the most toxic environmental pollutants.

Objectives: This study was conducted to determine the effect of an ethanolic leaf extract of *piper guineense* on the kidneys of paraquat-induced adult Wistar rats.

Methods: In this study, rats were divided into six groups. The control group (group A) received distilled water, and 20mg/kg of Paraquat was induced in groups B, C, D, E, and F; group C received 200mg/kg, group E received 80mg/kg, and group F received 100mg/kg of ethanolic leaf extract of *Piper guineense*, respectively. The animals were treated for 28 consecutive days. After the urea and serum creatinine collection, kidney histopathology was investigated.

Results: PQ increased relative organ weight, urea, and serum creatinine levels, but it significantly decreased body weight across groups B and D. In the groups treated with *piper guineense*, urea and creatinine decreased compared with the PQ group, and body weight levels increased. Severe intra-renal inflammation and haemorrhage, necrotic debris around the hemorrhagic area, was seen histopathologically. The effects were ameliorated in Groups E and F, which received variable doses of the ethanolic leaf extracts of *P. guineense*.

Conclusion: The obtained findings revealed that *P. guineense* leaf extract, used as a preventive compound, was able to reduce kidney dysfunction and tissue damage caused by PQ toxicity in the kidney.

Keywords: *Piper Guineense*, Paraquat, Kidneys, Histology

INTRODUCTION

Throughout history, nature has served as a valuable source of medicinal remedies and therapeutic relief, with many modern drugs derived and extracted from natural plant sources. These formulations and isolations often stem from the traditional uses of plants in medicine, highlighting the ongoing significance of plant-based traditional medicine systems in healthcare. Approximately 80% of the global population relies primarily on traditional medicines for their primary healthcare needs (Akinloye et al., 2020).

Piper guineense is one such plant with medicinal properties, known as Ashanti pepper, belonging to the *Piperaceae* family and the Piper genus. It is referred to by various local names such as 'Uziza' in Igbo, 'Iyere' in Yoruba, 'Ebe-ahinhiakpoke' in Edo, and 'Etinkene' in Efik (Wasswa et al., 2017). Indigenous to Western and Central Africa's tropics, *P. guineense* is cultivated in Nigeria, particularly Southern Nigeria (Balogun et al., 2016). The leaves of *P. guineense* are commonly used as leafy vegetables in Nigerian cuisine, while the fruits are utilized for flavouring dishes. These leaves are known to contain phytochemicals like alkaloids, flavonoids, saponins, phenols, and tannins, along with essential minerals such as zinc, iron, and potassium (Stephen et al., 2016; Ojinnaka et al., 2016; Dodo et al., 2021).

Studies have highlighted the positive effects of *P. guineense* on various aspects of health, including the liver, kidneys, female reproductive system, diabetes management, ulcer prevention, male libido enhancement, and male reproductive parameters (Wasswa et al., 2017; Imo et al., 2021; Memudu et al., 2014; Amadi et al., 2019; Onwidiwe et al., 2021; Nwosu et al., 2022). This underscores the diverse medicinal properties and potential therapeutic benefits of *Piper guineense* in traditional and modern healthcare practices.

As human populations grow, it has become possible to sustain nourishment by resorting to advanced scientific farming methods. Modern agriculture relies heavily on pesticides, herbicides, and chemical fertilizers to enhance crop yield and quality despite the potential toxicity of these substances to both humans and animals (Okolonkwo et al., 2022; Gotter, 2022; National Center for Biotechnology and Information, 2022).

Paraquat is a chemical compound used in agriculture, also known as methyl viologen. This bipyridyl compound acts as a potent herbicide but poses significant risks to human health upon ingestion or exposure (Awadalla, 2012). Paraquat is particularly toxic to organs such as the lungs, kidneys, brain, and liver (Atashpour et al., 2017). Commonly referred to as gramoxone, Paraquat is notorious for its high toxicity and is considered a dangerous poison (Gotter, 2022).

Exposure to concentrated paraquat solutions can result in skin irritation, nail shedding, cracking, delayed wound healing, and cut healing issues (National Center for Biotechnology and Information, 2022). Additionally, paraquat poisoning leads to alterations in various biochemical parameters, as evidenced by studies highlighting significant changes in biochemical concentrations among both survivors and nonsurvivors of paraquat exposure (Zhou et al., 2016; Hashemi et al., 2017).

The toxicity of Paraquat is attributed to oxidative damage to cells and the generation of free radicals (Okolonkwo et al., 2022). Due to the absence of an effective antidote for paraquat poisoning and its reliance on oxidative stress mechanisms, researchers are now focusing on the role of antioxidants in managing paraquat toxicity (Zhou et al., 2016). Many herbal compounds possess antioxidant properties that protect organs like the liver from harmful agents like

Paraquat. Hence, this study aims to investigate the effects of ethanolic leaf extract of *Piper guineense* (uziza) on the kidneys of paraquat-induced adult male wistar rats.

Materials and Methods

collection of plant samples

The *piper guineense* leaves (Uziza) were purchased from Uburu-eke Aja main market in Ebonyi State.

Plant Extraction Process

The leaves of *Piper guineense* were bought in large quantities, washed using water, and air dried. The air-dried leaves were pulverized using a blender. Two hundred and fifty grams (250g) of the crushed leaves were macerated in a mixture of 1,000 ml of 98% absolute ethanol for 48 hours. The extract was filtered using Whatman no 1 filter paper. The filtrate was concentrated using a water bath at 65°C. The extract was stored at -4°C in the refrigerator until required. The percentage yield of the extract was determined.

Animal purchase and handling

Thirty (30) male adult albino Wistar rats weighing 160g – 200g were obtained from Amaka Animal Farm in David Umahi University of Health Sciences, Uburu, Ebonyi State. The rats were housed in Wire gauze cages and allowed to acclimatize in the animal house of the Department of Anatomy, David Umahi University of Health Sciences, Uburu, Ebonyi State, for one week before exposure. The rats were fed with rat chow and provided water *ad libitum* throughout the experiment.

Experimental design

The thirty (30) adult male Wistar rats were weighed and allocated into six (A-F) groups of five animals each. All treatments were administered orally as follows:

Group A (The control group) distilled water for 28 days.

Group B: (20mg/kg of Paraquat group) only, which serves as negative control

Group C: 200mg/kg of ethanolic leaf extract of *Piper guineense* once daily for 28 days

Group D: 20mg/kg of Paraquat for 14 days, after which Paraquat were withdrawn, and rats feed with water and standard feed *ad libitum* till day 28

Group E: 20mg/kg of Paraquat for 14 days, after which the Paraquat was removed, and rats were fed 80mg/kg of ethanolic leaf extract of *Piper guineense* once daily until day 28.

Group F: 20mg/kg of Paraquat + 100mg/kg of *Piper guineense*

All extracts were administered once daily throughout the experiment, while Paraquat was administered twice a week for four weeks.

Sample Collection

Blood was obtained from the animals via ocular puncture, and it was used for hormonal assay of the kidneys; immediately, the animals were sacrificed, and the kidney weight was measured immediately and fixed in a 10% formalin for the histology studies.

Determination of renal dysfunction-specific markers

Blood samples from the rats were collected and then centrifuged for serum. Serum urea and creatinine were determined using commercially available kits according to the manufacturer's recommended protocol.

Histological studies

Kidney tissues from the experimental animals were fixed in 10% formalin and were processed for paraffin sectioning. The paraffin-embedded kidney was cut into serial sections (5 μ m). Sections were stained with haematoxylin and eosin to evaluate under a light microscope.

Statistical Analysis

The data obtained from the study were analyzed using SPSS 21.0 for descriptive and inferential statistics and ANOVA (analysis of variance). All results obtained were expressed as Mean value \pm SEM (Standard error of the mean) in each group. Differences between means were regarded as significant at $P < 0.05$

Results

Effect of Ethanolic Extract of Piper guineense and Paraquat on Body Weight of adult male Wistar rats.

Table 1 shows the analysis of the body weight. An increase in body weight was seen at the end of the experiment. There is a significant decrease in weight difference between Group B and Group D compared with Group A. However, a statistically significant difference was seen in group D when compared with group A (Fig. 1)

Table 1: Mean values of Body Weights obtained at the end of the experiment

Group	Initial Body Weight (g)	Final Body Weight (g)	T-test
	Mean \pm SEM	Mean \pm SEM	p-value

Group A	161.50 ± 16.68	216.50 ± 09.61	0.057	-12.00
Group B	168.34 ± 13.43	146.67 ± 10.65	0.127	0.664
Group C	166.67 ± 1.89	228.61 ± 13.43	0.056	-3.000
Group D	167.33 ± 6.64	155.12 ± 14.13	0.043*	3.619
Group E	166.67 ± 1.89	207.33 ± 13.73	0.075	-2.413
Group F	184.00 ± 12.23	224.00 ± 24.00	0.056	-3.000

*p < 0.05 when compared with group A (control)

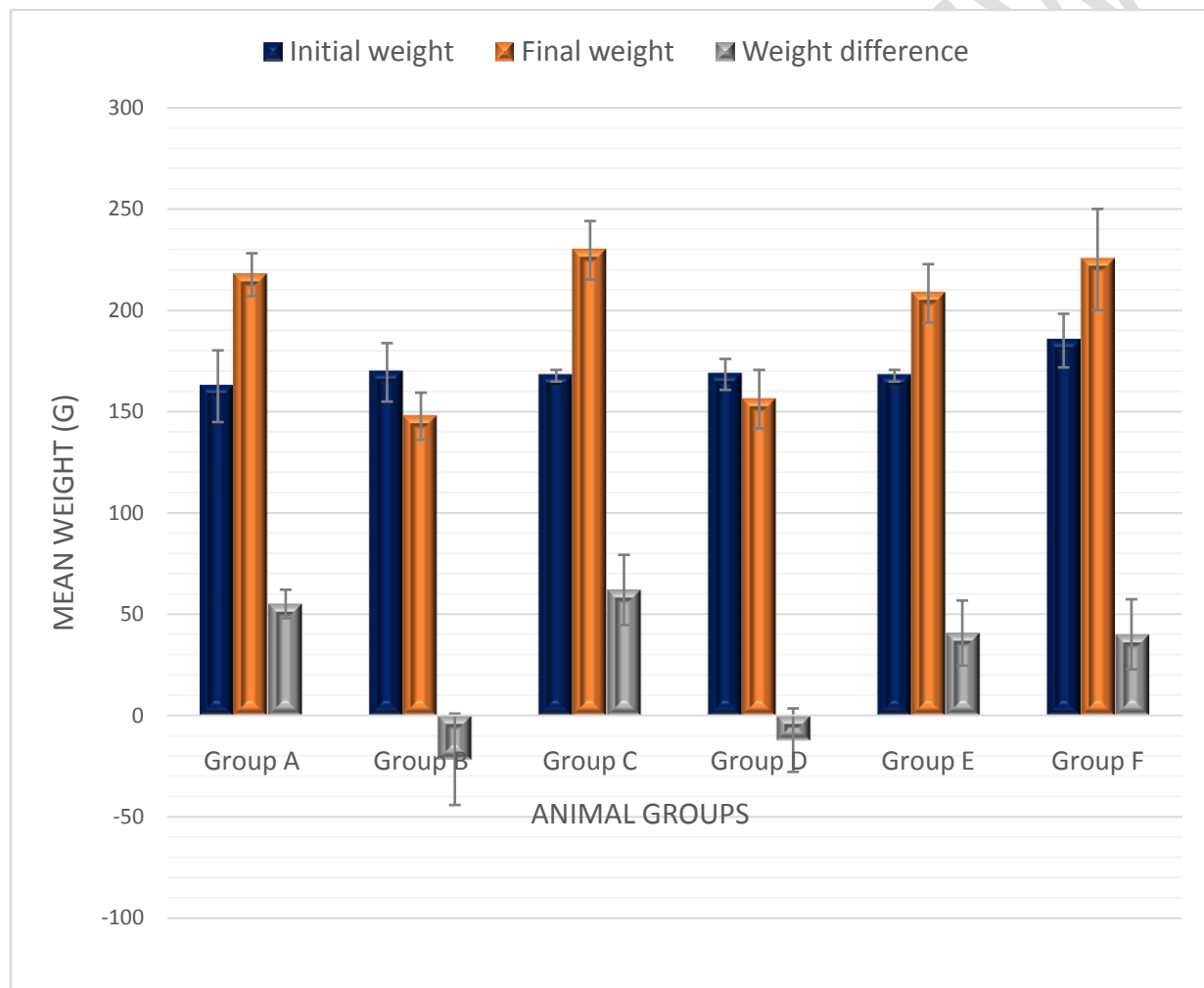


Figure 1. The Initial and Final Mean Body weight change for the various Experimental Groups *Effect of Ethanolic extract of Piper guineense and Paraquat on the relative kidney weight of adult Wistar rats.*

Table 2 shows the analysis of kidney weight. At the end of the experiment, group B had an increase in weight compared with the control (0.95±0.04). Group D had a significantly increased

relative organ weight compared with the control. Groups C, E, and F did not vary significantly from the control (Fig. 2).

Table 2: Mean relative Kidney weight

Relative kidney weight (%)	Mean ± STD	p-value	F-value
Group A	0.95±0.04		
Group B	1.58±0.17	0.00	10.35
Group C	0.99±0.16	0.74	
Group D	1.09±0.09	0.24	
Group E	0.91±0.06	0.76	
Group F	0.95±0.09	0.96	

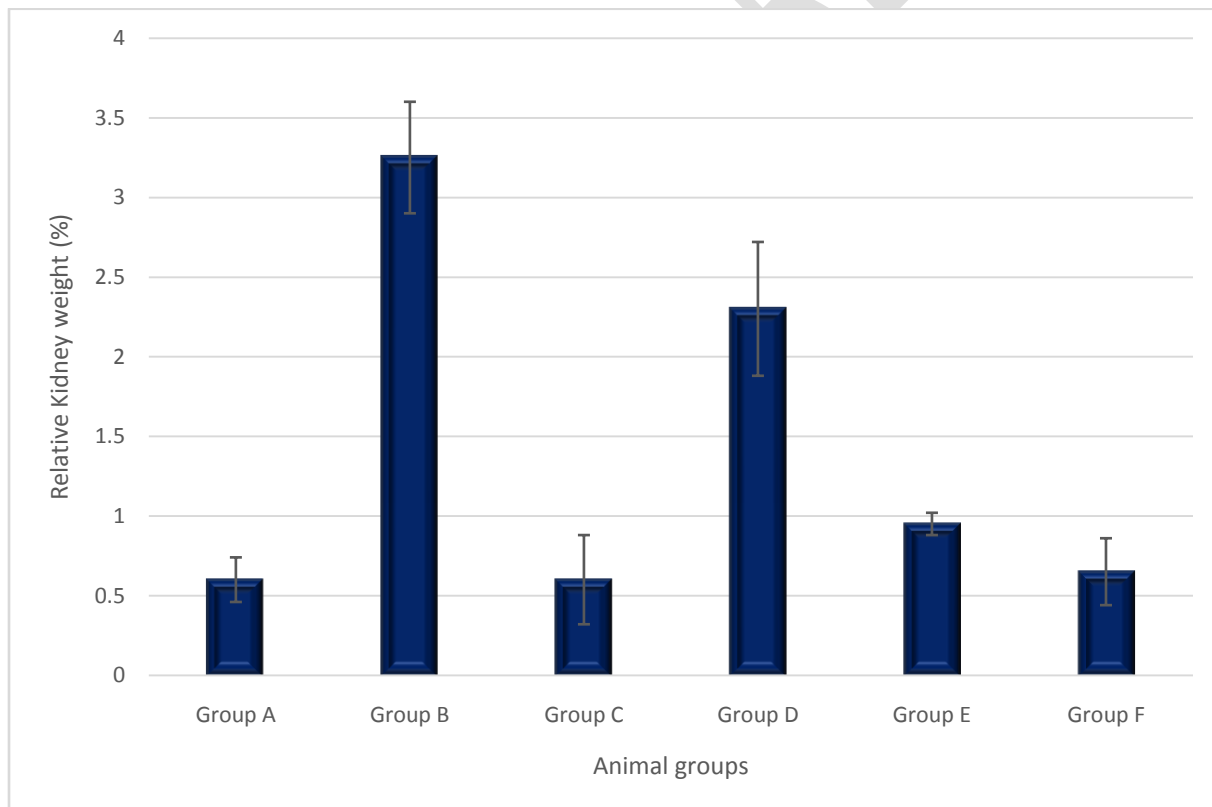


Figure 2: The relative kidney weight of animals in the experimental group.

Effect of Ethanolic Extract of Piper guineense and Paraquat on Serum Biochemical Parameters of kidney functions of adult male Wistar rats

To investigate kidney functions, we investigated urea and creatinine, two serum biochemical parameters. As shown in Tables 3a and b, there was a significantly increased level of urea and creatinine in the PQ-treated group compared to the control group. However, pre-treatment with *piper guineense* could prevent PQ-induced increased levels of these serum biochemical parameters close to the control (Fig. 3a and b).

Table 3a: The serum urea level obtained at the end of the experiment

Urea (mg/dL)	Mean±STD	p-value	F-value
Group A	20.5±2.12		
Group B	54±8.49	0.00	8.32
Group C	20.5±3.54	1.00	
Group D	35±7.07	0.07	
Group E	24±8.49	0.61	
Group F	22.5±6.36	0.77	

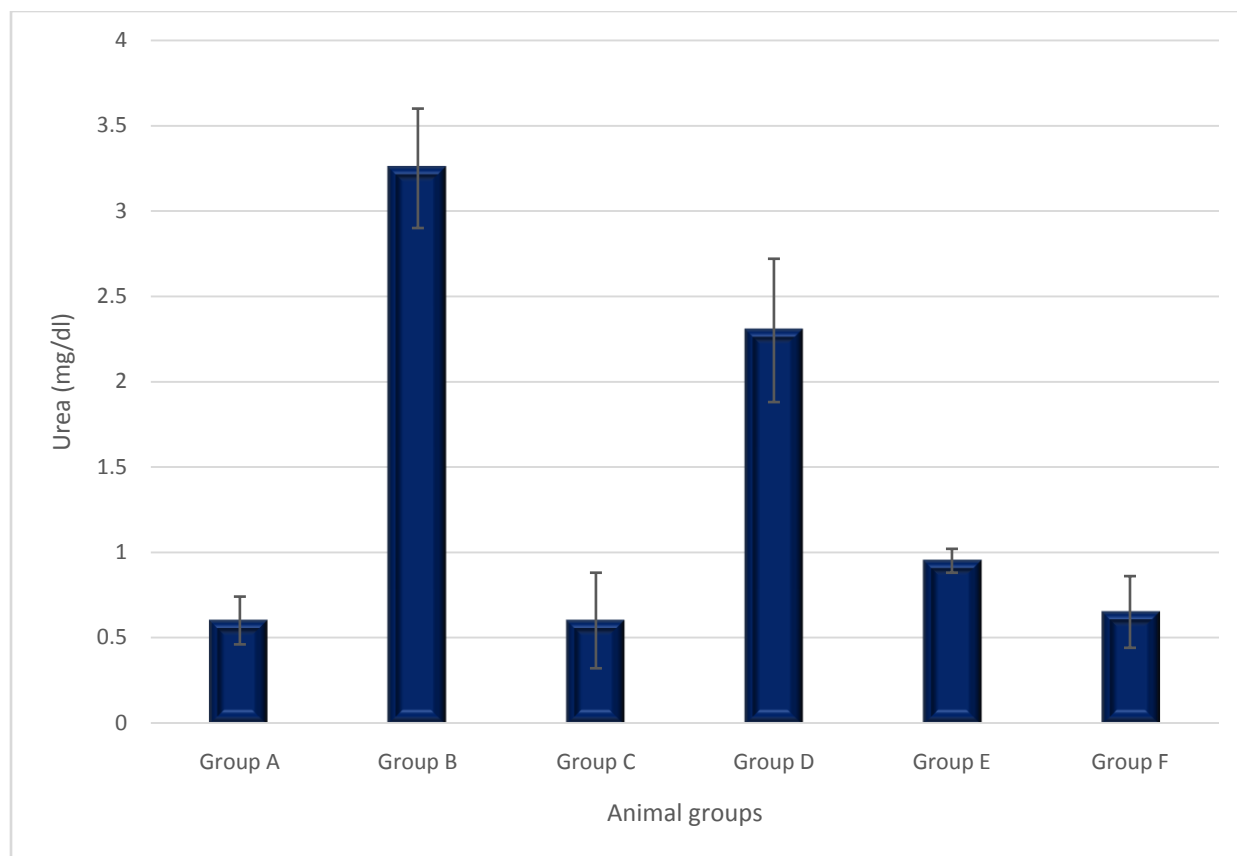


Figure 3a. The serum urea level of animals in various experimental groups.

Table 3b: The serum creatinine level obtained at the end of the experiment.

Creatinine (mg/dL)	Mean±STD	p-value	F-value
Group A	0.6±0.14		
Group B	3.25±0.35	0.00	33.11
Group C	0.6±0.28	1.00	
Group D	2.3±0.42	0.00	
Group E	0.95±0.07	0.25	
Group F	0.65±0.21	0.86	

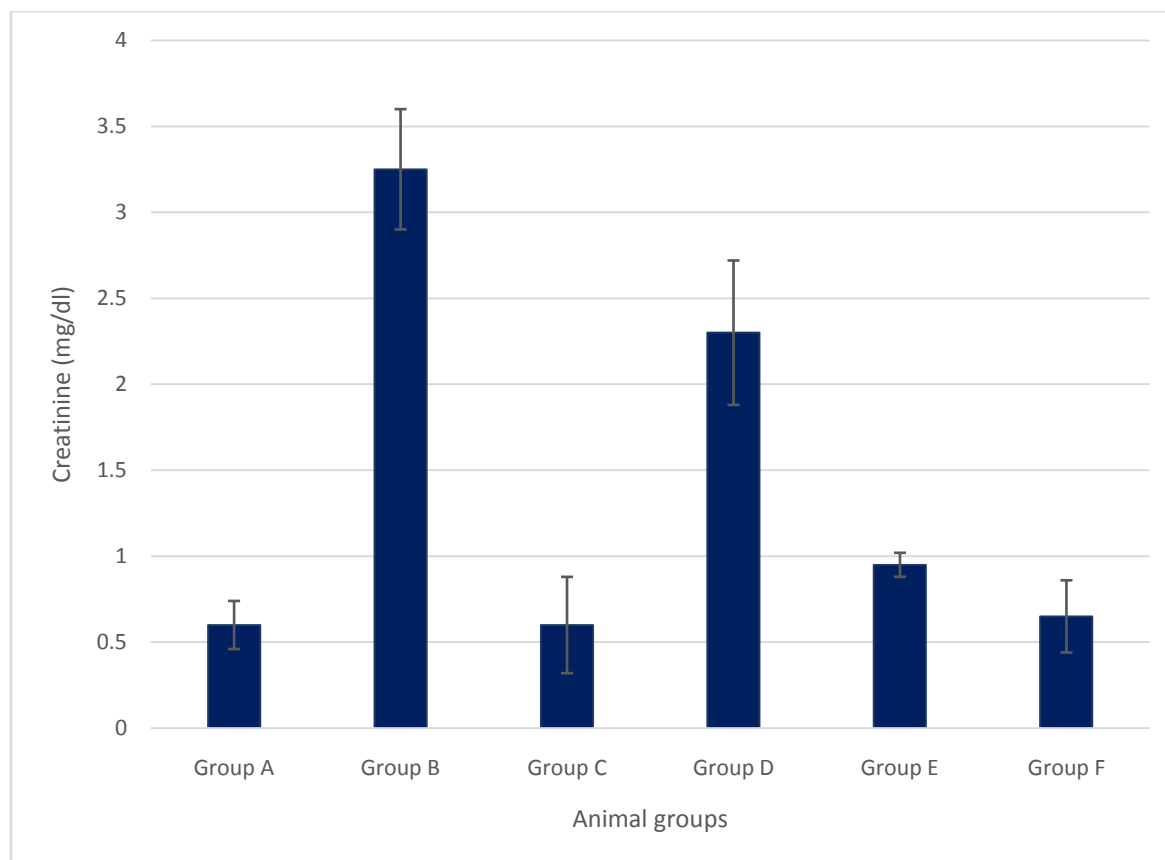


Figure 3b: The creatinine level of animals in various experimental groups.

Effect of Ethanolic extract of Piper guineense and Paraquat on histological morphology of adult male Wistar rats

Fig. 4 shows the histopathological changes from kidney segments of the normal and experimental groups. We observed renal inflammation, necrotic debris, and intrarenal haemorrhage in the PQ-treated group. However, pre-treatment with *Piper guineense* ameliorated PQ-induced alterations and kept the pathological lesions close to the normal range.




Fig. 4. Effects of *Piper guineense* on PQ-induced histological changes in kidney section. Histological examination was performed by H&E staining; loss of integrity of glomerulus and tubules is marked with acronym (X400). Bowman space (BS), severe intra-renal inflammation arrest (SIRIA), severe intra-renal inflammation (SIRI), intra-renal haemorrhage (H), cast nephropathy (CN) and aggregate of inflammation cell (AIC), congestion of blood vessel (CBV), important congestive vessels (ICVs), mild focal area of haemorrhage (FAH).

DISCUSSION

Herbicides have been shown to cause a number of histological and renal function abnormalities. Herbicide paraquat is widely used in agriculture and has different toxicity pathways in different organs, including the kidneys. In this investigation, the high toxic effect resulted in significant body weight alterations as well as organ and tissue damage. The administration of 20mg/kg of Paraquat in group B caused a significant decrease. Given that oxidative stress is involved in PQ-induced cytotoxicity (Felehgari *et al.*, 2022), the current observed decreased body weight and increased organ weight. Based on the results, the treatment with *piper guineense* leaf extract significantly brought the changes relative to normal compared to the PQ group.

Furthermore, the administration of *piper guineense* increased body weight levels significantly compared to the PQ group. Udoekong and Ochagu (2023) observed weight gain following dietary intake of *piper guineense*. However, the increase in weight was most significant in the groups that received 200 and 100 mg/kg b.w. in our study.

In our study, Paraquat (PQ) led to failure in renal function, which was indicated by weight loss and function. “To evaluate this disorder, urea and creatinine serum content, two main biomarkers for discovering damage to kidney tissue in poisoning with PQ were detected. Usually, urea is a byproduct of protein digestion in the body, and creatinine is a waste product of creatine phosphate excreted by the kidneys. However, in the case of PQ poisoning, their concentration rises due to renal dysfunction” (Yoon *et al.*, 2011; Felehgariet *al.*, 2022). This study found that the treatment with PQ led to an increase in urea level and was conveyed by the accretion of creatinine content, indicating that PQ contact damaged kidney function.

Furthermore, the histological assessment showed significant variations in the structure of the kidneys, including severe intra-renal inflammation, necrosis and renal haemorrhage; kidney weight in the PQ group significantly increased compared to that in control groups. The current study's results align with the findings obtained by Wei *et al.* (2014) and Felehgariet *al.* (2022). Treatment with *Piper guineense* leaf extract revealed a protective effect against nephrotoxic PQ, as documented by low urea and creatinine serum levels. “This study showed that urea was properly excreted in all groups administered the different doses of extracts compared to the control. This result also showed that leaves' extract of *P. guineense* encouraged elimination of urea by the kidney better than the other extracts. Decrease in the level of urea has been reported following administration of *piper guineense* leaves extract in impaired kidney to filter urea up to normal levels” (Imo, *et al.*, 2021).

Photomicrograph of the normal kidney showed normal histoarchitecture of the renal tissue (Fig. 4). The kidney of PQ-treat (group B) showed severe intra renal inflammation and renal haemorrhage, necrotic debris around hemorrhagic area space following administration of 20mg/kg b.w, while kidneys of rats administered ethanolic leaves' extract of *P. guineense* (200mg/kg bw) showed mild aggregate of moderate degeneration with moderate intra renal inflammation arrest (Group C). Photomicrograph of kidney section from a rat-administered ethanolic leaves' extract of *P. guineense* (80 mg/kg bw) showed normal glomerulus and moderate intra renal haemorrhage (Group E). In comparison, the kidney section from a rat-administered

ethanolic leaves' extract of *P. guineense* (100 mg/kg bw) showed mild healing with a moderate glomerular aggregate of inflammation within important congestive vessels (ICVs) around the mild focal area of haemorrhage (FAH (Group F). The histoarchitectural state of the kidney sections showed apparent alteration by the different doses of the extract; however, it showed no correlation with the results of the biochemical analysis.

CONCLUSION

The findings of the study demonstrated that PQ produced kidney toxicity in rats, although piper guinease's antioxidant qualities mitigated the harmful kidney malfunction and tissue damage brought on by PQ poisoning. The care and treatment plans for PQ poisoning patients may benefit from these data. To identify the molecular mechanism behind the actions of piper guinease, more assessments are necessary.

Ethical Approval

This research was sought and obtained from the Chairman Committee of the Faculty of Basic Medical Sciences, David Umahi University of Health Sciences, Uburu, Ebonyi State, Nigeria. The experimental procedures of this study complied with ARRIVE guidelines, National Institutes of Health (NIH) guidelines, and National Health Research Ethics Laboratory Animals.

Reference

1. Akinloye, O.A., Alagbe, O.A., Ugbaja, R.N. and Omotainse, S.O., (2020). Evaluation of the modulatory effects of Piper guineense leaves and seeds on egg albumin-induced inflammation in experimental rat models. *Journal of ethnopharmacology*, 255, p.112762.
2. Amadi, G., Iwuji, S.C., Azeez, T.O., Nwaokoro, C.J. and Wodu, C.O., (2019). Biochemical effects of Piper Guineense (African Black Pepper) in female diabetics: opportunities for diabetes treatment. *International Journal of Translational Medical Research and Public Health*, 3(1), pp.59-65.
3. Atashpour, S., Jahromi, H.K., Jahromi, Z.K. and Zarei, S., (2017). Antioxidant effects of aqueous extract of Salep on Paraquat-induced rat liver injury. *World journal of hepatology*, 9(4), p.209.
4. Awadalla, E.A., (2012). Efficacy of vitamin C against liver and kidney damage induced by paraquat toxicity. *Experimental and toxicologic pathology*, 64(5), pp.431-434.
5. Besong, E.E., Balogun, M.E., Djobissie, S.F., Mbamalu, O.S. and Obimma, J.N., (2016). A review of Piper guineense (African black pepper). *Int. J. Pharm. Pharm. Res*, 6(1), pp.368-384.
6. CHINWENDU, S., Ejike, E.N., Ejike, B.U., Oti, W. and Nwachukwu, I., (2016). Phytochemical properties of Uziza leave (Piper guineense). *European Journal of Pure and Applied Chemistry Vol*, 3(2).
7. Felehgari, H., Khiripour, N., Mehri, F., Asl, S.S., Ahmadimoghaddam, D. and Ranjbar, A., (2022). Investigating Preventive Effect of Vitamin D and N-acetylcysteine Against

Kidney Injury in Rats Versus the Promotive Effect of Paraquat. *Avicenna Journal of Medical Biochemistry*, 10(2), pp.114-119.

8. Gotter A. What is paraquat?; (2022). Available:<https://www.healthline.com/health/paraquatpoisoning#:~:text=Paraquat%20is%20a%20chemical%20herbicide,control%20weed%20and%20grass%20growth> Accessed 14/4/22.
9. Hashemi, R.A., Jaddi, Y., Sadeghi, M.A., Ghiamati, S. and Motazedi, M., (2017). Study of toxicology effects of herbicide paraquat on hematological parameters of Mesopotamichthys sharpeyi. *Open Journal of Marine Science*, 7(2), pp.258-270.
10. Imo, C., Arowora, K.A., Ezeonu, C.S., Ikwebe, J., Yakubu, O.E., Imo, N.G. and Danlami, G.C., (2021). Biochemical and histological effects of ethanolic extracts of fruits of *Xylopia aethiopica* and seeds and leaves of *Piper guineense* on liver and kidney function in male albino rats. *Future Journal of Pharmaceutical Sciences*, 7, pp.1-12.
11. Memudu, A.E., Akinrinade, I.D., Ogundele, O.M. and Dare, B.J., (2014). Effects of crude extract of dry fruits of *Piper guineense* on male fertility parameters of adult Sprague Dawley rats. *European Journal of Medicinal Plants*, 5(3), pp.297-303.
12. National Center for Biotechnology Information. (2022). PubChem Compound Summary for CID 15939, Paraquat;. Retrieved April 14, 2022. Available:<https://pubchem.ncbi.nlm.nih.gov/compound/Paraquat>
13. Nwosu, N.C., Onwuka, O.M. and Oghenemavwe, L.E., (2022). Antioxidant Effects of Ethanolic Extract of *Piper guineense* (Uziza) Leaves on Lead-Induced Testicular Toxicity in Wistar Rats. *Saudi J Biomed Res*, 7(2), pp.95-100.
14. Ojinnaka, M.C., Odimegwu, E.N. and Chidiebere, F.E., (2016). Comparative study on the nutrient and antinutrient composition of the seeds and leaves of Uziza (*Piper guineense*). *IOSR Journal of Environmental Science, Toxicology and Food Technology*, 10(8), pp.42-48.
15. Okolonkwo, B.N., Ekwempu, A.I., Brisibe, N., Konne, J.B. and Nyenke, C.U., (2022). Hepatocellular recovery of chronic paraquat induced liver toxicity in vitamin E and C treated male wistar rats. *International Journal of Biochemistry Research & Review*, 31(7), pp.1-8.
16. Onwidiwe, T.C., Unekwe, P.C., Chilaka, K.C., Ilo, C.E., Ughachukwu, P.O. and Aligwekwe, A.U., (2021). Evaluation of gastroprotective activities of fraction extracts of piper guineense leaf on ethanol-induced ulcer in wistar rats. *Saudi Journal of Medical and Pharmaceutical Sciences*, 7(9), pp.458-468.
17. Thomas SHL (2018). Poisoning. *Davidson's Principles and Practice of Medicine*.7:131-150. ISBN-13: 978-0702070280; ISBN10: 0702070289
18. Udoekong, E.C. and Ochagu, S.I., (2023). Effect of dietary supplementation of black pepper (*Piper quineense*) leaf and seed meals on growth performance and blood characteristics of the finisher broiler chickens. *Nigerian Journal of Animal Science*, 25(1), pp.107-116.
19. Wasswa, J.N., Omorodion, T.N., Avwioro, G.O. and Asimiyu, O.S., (2017). Histological effect of *Piper guineense* (UZIZA) leaves on the liver of wistar rats. *Int J Res Rev*, 4(3), pp.36-41.
20. Wei, T., Tian, W., Liu, F. and Xie, G., (2014). Protective effects of exogenous β -hydroxybutyrate on paraquat toxicity in rat kidney. *Biochemical and biophysical research communications*, 447(4), pp.666-671.

21. Yoon, S.P., Han, M.S., Kim, J.W., Chang, I.Y., Kim, H.L., Chung, J.H. and Shin, B.C., (2011). Protective effects of chitosan oligosaccharide on paraquat-induced nephrotoxicity in rats. *Food and chemical toxicology*, 49(8), pp.1828-1833.
22. Zhou, D.C., Zhang, H., Luo, Z.M., Zhu, Q.X. and Zhou, C.F., (2016). Prognostic value of hematological parameters in patients with paraquat poisoning. *Scientific reports*, 6(1), p.36235.

UNDER PEER REVIEW