

A one-year follow up treatment of an 8-year old child with thumb sucking habit using a new habit breaking appliance: A Case Report

ABSTRACT

This report describes the management of an 8-year-old male child with thumb sucking habit and anterior open bite. Comprehensive diagnosis was performed and patient's records were taken (extra-oral and intra-oral photographs, lateral cephalometric and panoramic radiographs, and study models) along with impressions for appliance fabrication. When received from the laboratory, the appliances were disinfected, fitted, then cemented and adjusted in the patient's mouth. The patient and his parents were enlightened about the advantages of the appliances, which entailed cessation of thumb sucking habit thus allowing tooth eruption and open bite closure, and giving them instructions at time of appliance insertion. A questionnaire to test patient compliance was given to the parents every follow-up. Treatment was consummated once the child ends 12 months of follow-up regardless of the fact that it could be achieved.

Treatment effects were evaluated by comparing pre and post treatment records along with the questionnaire answers. The report showed the patient was compliant with the appliance, with significant increase in overbite and the maxillary intercanine width. This might be the result of stop of thumb pressure on the palate. It also showed a significant reduction of lower anterior facial height. The maxillary incisors had been uprightened. The interlabial gap greatly reduced after treatment while the nasolabial angle recorded no significant change. It was concluded that the magnetic habit breaker was effective to stop the habit and help bite closure due to the appliance's dual effect and good patient acceptance.

Keywords: Anterior open bite; thumb sucking; habit breaking appliance; abnormal oral habit

1. INTRODUCTION

Thumb sucking is the most common oral habit with a prevalence between 13 to 100% in some communities [1]. This habit is accompanied by damaging dento-facial effects; anterior open bite, poor esthetics, speech difficulties and bad psychological impact [2,3]. This entails careful examination of the habit for proper diagnosis and treatment plan. Treatment of thumb sucking habit was suggested to be carried out early in the mixed dentition for control over the adverse effects on the dentofacial components, hence improve the possibility of success, stability as well as restricting or redirecting vertical growth. Moreover, the patient can benefit from an improved mastication, esthetics and speech [4,5].

Management of thumb sucking habit can be done by many habit breaking appliances such as palatal crib, palatal spurs and blue grass appliance, that act as a mechanical barrier to thumb to encourage discontinuation of the habit and bite closure [6]. However, these appliances have many drawbacks such as difficulty of speech and eating, poor esthetics due to their bulky size [6–8]. Moreover, some clinicians stated that using spurs appliance may result in negative patient or parent reactions due to injury to tongue or thumb from the metal spurs [9]. These shortcomings might affect patient compliance and call for a new habit breaking appliance that can efficiently break the habit with better patient acceptance.

2. CASE PRESENTATION

An 8-year old male child and his parent with no relevant medical or social history came to the clinic with a chief complain of difficult speaking, and annoying jaw appearance due to Anterior Open bite as a result of a history of thumb sucking habit. His mother reported that he is constantly bullied by his classmates at school. There was a previous trial with a habit breaking appliance that failed to stop the habit because the child wasn't compliant with the appliance's metal appearance and bulky size, so he continued to practice thumb sucking during day and night. Clinical examination showed lip incompetence and Anterior Open Bite.

Diagnostic records were taken for the child including extra-oral and intra-oral photographs (Fig.1), obtained by digital camera (*Canon 750D digital camera, Japan*) with ring flash (*Yongnuo model YN-14EX-C, China*) and 100 mm macro lens (*Canon EF 100mm f/2.8 Macro USM Lens, Japan*), study models using an alginate impressions (*Hydrogum soft-Zhermack-Italy*) for the maxillary and mandibular arches with fitted sized perforated trays. The impressions were immediately disinfected, sent to the lab, and poured with orthodontic stone material (*super white, hard orthodontic stone –whipmix, Louisville, USA*), then properly trimmed to obtain orthodontic study casts. Digital Panoramic and lateral cephalometric radiographs were taken using panoramic and cephalogram machine (*VaTech x-ray system, South Korea*). The exposure parameters for the digital Panorama were set on 80 kV, 14 mA and 14 seconds while the exposure parameters for the digital cephalography were 70 kV, 10 mA and 14 seconds.

The obtained case history and clinical and radiographic examination data were summarized in the diagnostic chart. Habit history was taken through a questionnaire answered by the parent and child.

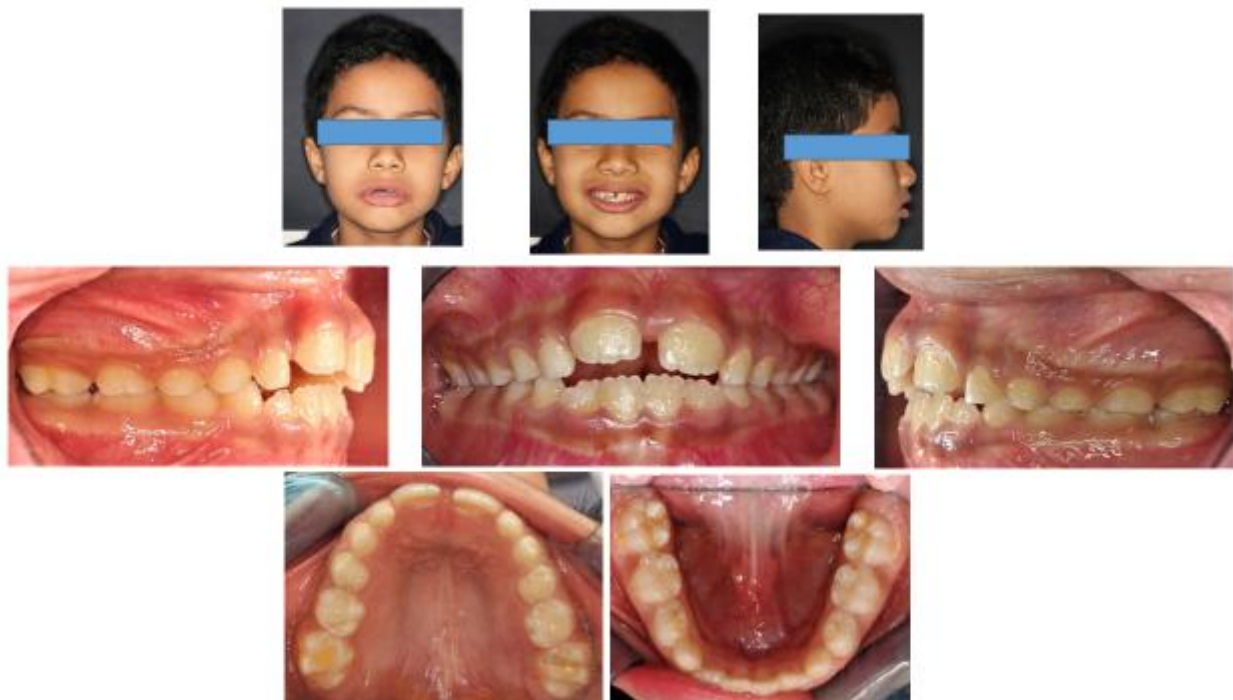

Figure (1): Extra-oral and Intra-oral photograph

3. TREATMENT AND APPLIANCE FABRICATION

After the parents were informed about the risks and benefits of our appliance, they signed an informed consent/assent and were handled a printed copy.

This appliance is called magnetic habit reminder which is a custom made fixed-removable appliance, consisting of two parts (fixed intraoral part and removable extraoral part) enclosing two poles of gold-plated disk shaped neodymium and iron boron magnets (*first4magnets™, UK*)[10].

The appliance was fabricated through the following steps[10]:

- i. Separators (*Oramco corporation, orange, USA*) were placed two days before seating the bands on the first permanent molars, then alginate impressions for the maxillary arch and the thumb were taken, the bands were removed from the patient's mouth, then repositioned and secured in the impression before being sent to the lab for pouring.
- ii. The intraoral acrylic part was constructed from cold cured acrylic resin (*Orthocryl® - Dentaaurum, Germany*), enclosing 12mm diameter x 2mm, thick, rare earth magnet and a 0.9mm stainless steel wire soldered to the bands. It is finished and polished and kept in water for 24 hours before cementation intraorally (Fig.2).
- iii. The extraoral part (thumb cover) was constructed from transparent soft 1.5 mm thick vacuum formed sheet (*ethylene vinyl acetate sheet, 3A MEDES company, South Korea*) enclosing a 4mm diameter x 1.5mm thick rare earth magnet. It was fabricated using vacuum forming machine (*Jintai Dental Vacuum Forming Machine, china*), to press the sheet over the thumb model which is fixed on the machine table. The thumb model was then removed, and the cover was dislodged from the model, trimmed to the drawn design and finished (Fig.3).
- iv. A child watch (Watch house company, Cairo, Egypt) was attached to the thumb cover via transparent string. This watch act as an additional support for the extraoral part (thumb cover), and also as an esthetic component for the child to improve the compliance (Fig.3).

At the delivery day, after the proper disinfection, dryness of the appliance and the intraoral isolation, its intraoral part was cemented with glass ionmer (Medicem, PROMEDICA, Germany). The fitness of the extra-oral part (clear thumb cover) was checked on the thumb. The patient was given the instructions particularly using plastic spoon during eating.

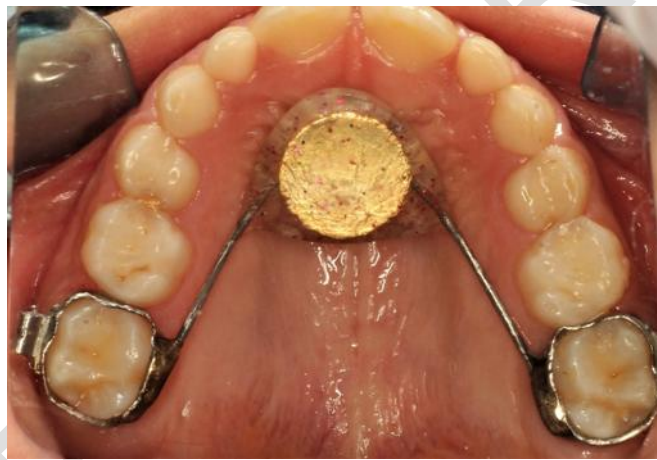

Figure (2): Intra-oral part

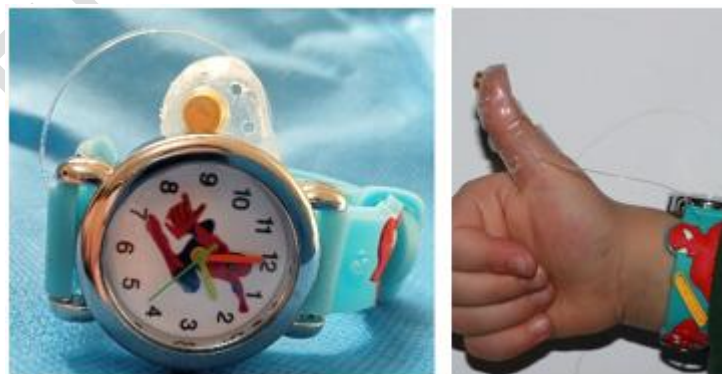

Figure (3): Extra-oral part (Thumb cover)

4.FOLLOW UP AND OUTCOME

The first follow up visit was scheduled after one week of appliance insertion to check the appliance fit. Then follow up visits were scheduled at a monthly interval for 12 months, to assess how well the patient was tolerating the appliance, to stress on the importance of breaking their habit, take intra-oral photographs to monitor the progress and Fill in the questionnaire of the habit

After 12 months of treatment, post-treatment records were taken the same as pre-treatment records to evaluate treatment outcomes (Fig.4).The Ortho Analyzer software (3Shape Co., Denmark) was used to measure the overbite and the maxillary inter-canine width on the digital models[8][11] (table 1).WebCeph™ software(version 1.5.0.) was used to measure jarabak ratio(PFH/AFH), upper incisor inclination (U1/PP), naso-labial angle and inter-labial gap on the lateral cephalometric radiographs (table 1).

The questionnaire given to the parents,was prepared to measure patient compliance. It combined two different questionnaires[12,13] to test patient compliance. It consisted of nine questions measuring the variables that test patient acceptance in term of eating, pronunciation, esthetics, and breakage,through the whole 12 months.

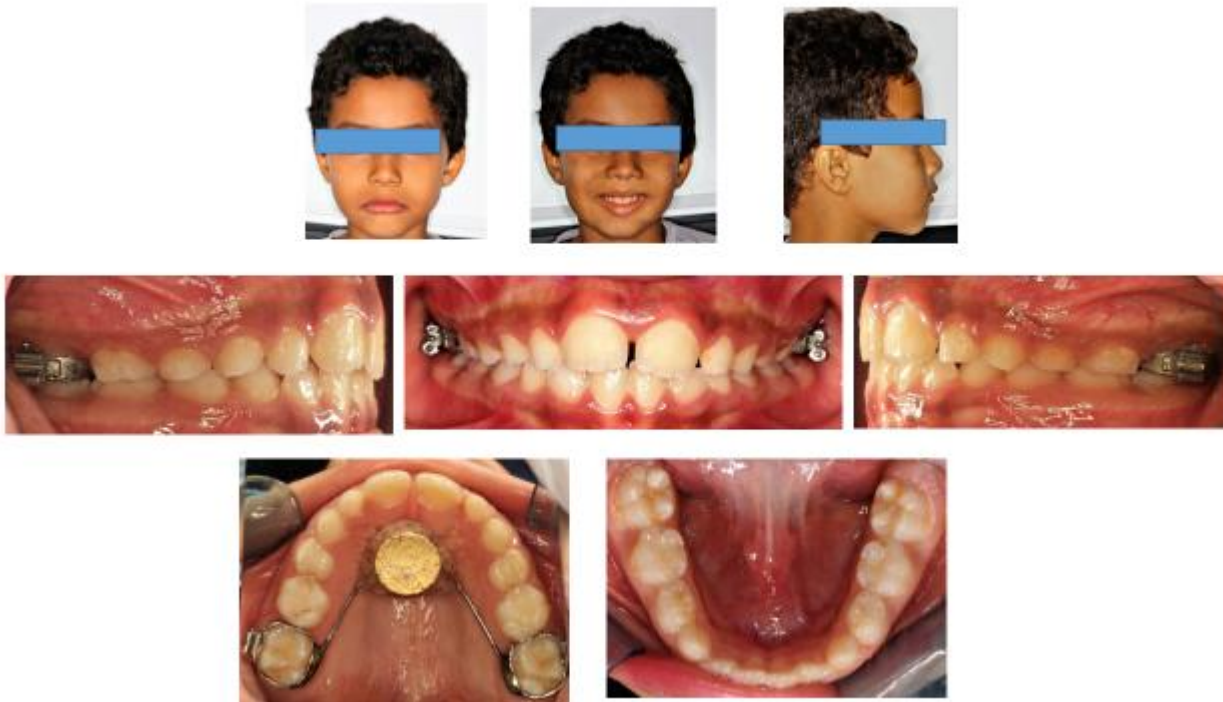


Figure (4): After 12 months of follow up

Table (1) showing pre-treatment and post-treatment measurements of cephalometric and cast analysis

Measurements	Pre-treatment	Post-treatment
PFH/AFH	60.3%	63%
U1/PP	112°	105°
Nasolabial Angle	78°	80°
Interlabial gap	5 mm	1 mm
Overbite	-2.16mm	+1.68mm
Maxillary inter-canine width	33 mm	35 mm

5. DISCUSSION

The current habit breaking appliances have many drawbacks such as tongue irritation, difficulty to maintain good oral hygiene, difficulty of speech and eating, negative emotional reactions and self-inflicted trauma[2,14]. Moreover, they are of low evidence at improving sucking cessation in children, highlighting the need for a high quality intervention to stop thumb sucking habit[15].

The magnetic habit reminder depends on two barriers to stop the habit: a mechanical barrier which is the acrylic part and a physical barrier which is the repulsion force between both parts. This helps prevent the thumb from resting on the palate at day and night, thus giving the appliance a dual effect. On the contrary to it, other habit breakers [13,16,17] include only a mechanical barrier.

In this study, greater improvement of open bite by 3.84 mm was observed with an increase of the maxillary inter-canine width by 2 mm, that might be due to the combination of mechanical and physical barrier of the appliance (dual effect). Also, there was a significant increase in Jarabak ratio (PFH/AFH) by 2.7% after treatment with magnetic habit breaker, this might be because habit cessation and bite closure bring about counterclockwise mandibular rotation leading to reducing anterior facial height [18]. The proclined maxillary incisors have been uprightened by 7° because the repulsion force stopped the thumb pressure on upper incisors. Moreover, there was significant improvement in the interlabial gap by 4 mm as a result of bite closure, while the nasolabial angle showed little significant change.

Parents reported in the questionnaire that their children didn't receive any comments on appliance appearance during talking, laughing and playing with their classmates in school. This may be because the appliance was invisible during different activities, in contrast to other habit-breaking appliances [6,7] which had an esthetic problem due to their visibility to others during smiling. Slight discomfort and speech difficulty were noted during insertion of our appliance. Otherwise, no difficulty was reported during eating and speaking till the end of treatment. On the other hand, there were discomfort, speech and chewing difficulties with palatal crip [13][17] and the palatal spurs caused irritation to tongue and injury to the thumb, with speaking, swallowing, eating impairments and risk of aspiration of debonded palatal spurs [6][9].

It is worth noting that addition of an attractive cartoon watch to the appliance, acted as a toy that enhanced patient acceptance.

6. CONCLUSION

1. Treatment with the magnetic habit reminder was effective to stop thumb sucking habit by its dual action - a combination of mechanical and physical barrier.
2. The magnetic habit reminder had excellent patient acceptance.
3. The anterior open bite was significantly improved with correction of the maxillary intercanine width.
4. Correction of the proclined upper incisors had occurred after cessation of thumb sucking.
5. Improvement of soft tissue profile by decreasing the interlabial gap.

CONSENT

As per international standards or university standards, patient(s) written consent has been collected and preserved by the author(s).

ETHICAL APPROVAL

As per international standards or university standards written ethical approval has been collected and preserved by the author(s).

ABBREVIATIONS

AFH: anterior facial height
PFH: posterior facial height
U1: upper incisors
PP: palatal plane

REFERENCES

- [1] Shahraki N, Yassaei S, Moghadam MG. Abnormal oral habits: A review. *J Dent Oral Hyg.* 2012;4(May):12-15. doi:10.5897/JDOH12.001 n.d.
- [2] Haryett RD, Hansen FC, Davidson PO. Chronic thumb-sucking: A second report on treatment and its psychological effects. *Amer J Orthodont.* 1970;57:164-178. n.d.
- [3] Ngan P. Open bite: A review of etiology and management. *Pediatr Dent.* 1997;19(2):91-98. n.d.
- [4] Canuto LFG, Janson G, De Lima NS, De Almeida RR, Caçado RH. Anterior open-bite treatment with bonded vs conventional lingual spurs: A comparative study. *Am J Orthod Dentofac Orthop.* 2016;149(6):847-855. doi:10.1016/j.ajodo.2015.11.026 n.d.
- [5] Cassis MA, De Almeida RR, Janson G, De Almeida-Pedrin RR, De Almeida MR. Treatment effects of bonded spurs associated with high-pull chincup therapy in the treatment of patients with anterior open bite. *Am J Orthod Dentofac Orthop.* 2012;142(4):487-493. do n.d.
- [6] Leite JS, Matussi LB, Salem AC, Provenzano MGA, Ramos AL. Effects of palatal crib and bonded spurs in early treatment of anterior open bite: A prospective randomized clinical study. *Angle Orthod* 2016;86:734–9. <https://doi.org/10.2319/031815-170.1>.
- [7] Haskell BS, Mink JR. An aid to stop thumb sucking: The “Bluegrass” appliance. *Pediatr Dent* 1991;13(2):83-5. n.d.
- [8] Suwwan, I.Y. (2008) Longitudinal effects of habit-breaking appliances on tongue and dento-alveolar relations and speech in children with oral habits. Dissertation. Toronto, Canada: University of Toronto, p. 183 n.d.
- [9] Justus R. Correction of anterior open bite with spurs: Long-term stability. *World J Orthod.* 2001;2:219-231. n.d.
- [10] Saifeldin, H., Negm, I., & Shehata, A. (2023). The Magnetic Habit Reminder For The Correction Of Thumb Sucking Habit. A Prospective Clinical Trial. *Egyptian Orthodontic Journal*, 63(1), 1-13. doi: 10.21608/eos.2022.175569.1059 n.d.
- [11] Howe RP, McNamara JA Jr, O'Connor KA. An examination of dental crowding and its relationship to tooth size and arch dimension. *Am J Orthod.* 1983;83(5):363-373. doi:10.1016/0002-9416(83)90320-2 n.d.
- [12] Miyawaki S, Yasuhara M, Koh Y. Discomfort caused by bonded lingual orthodontic appliances in 1999:83–8.
- [13] McRae EJ. Bondable lingual spur therapy to treat anterior open bite. ProQuest Diss Theses 2010:56.
- [14] Proffit WR. *Contemporary Orthodontics*. 3rd ed. St Louis: Mosby; 2000. 134-8 n.d.
- [15] Borrie FR, Bearn DR, Innes NP, Iheozor-Ejiofor Z. Interventions for the cessation of non-nutritive sucking habits in children. *Cochrane Database Syst Rev.* 2015 Mar 31;2015(3):CD008694. doi: 10.1002/14651858.CD008694.pub2. PMID: 25825863; PMCID: PMC8482062 n.d.
- [16] Rossato PH, Freire Fernandes TM, Assis Urnau FD, De Castro Ferreira Conti AC, Rodrigues De Almeida R, Pedron Oltramari-Navarro PV. Dentoalveolar effects produced by different appliances on early treatment of anterior open bite: A randomized clinical trial. *Angle Orthod* 2018;88:684–91. <https://doi.org/10.2319/101317691.1>.
- [17] Moore NL. Suffer the little children: fixed intraoral habit appliances for treating childhood thumbsucking habits: a critical review of the literature. *Int J Orofacial Myology.* 2002;28:6–38. n.d.
- [18] Johnson ED, Larson BE. Thumb-sucking: Literature review. *ASDC J Dent Child* 1993;60(4):385-91. n.d.