

EFFECTIVE SURGICAL MANAGEMENT OF FEMORALHEAD AFFECTIONS IN DOGS: Review of ten cases

ABSTRACT:

Ten dogs suffering from various conditions affecting the coxofemoral joint, including hip dysplasia, hip luxation, and femoral capital fractures, were included in the study. Nine of these dogs underwent treatment with femoral head osteotomy, while one case of hip luxation was treated using a toggle technique. All procedures involved a cranio-lateral incision approach and osteotomy performed with an oscillating saw. Following physiotherapy and passive range of motion exercises, all the dogs exhibited pain-free ambulation.

Keywords: Hip luxation, hip dysplasia, femoral head and neck osteotomy, toggle pin

INTRODUCTION:

The hip joint plays a vital role in dogs' mobility and shock absorption during physical activities. A variety of hip disorders can impact its functionality and health, stemming from genetic factors, developmental issues, injuries, or degenerative changes over time (Fathy *et al.*, 2022). The malformation of the femoral head and acetabulum is associated with the onset of osteoarthritis and pain in the coxofemoral joint (Smith *et al.*, 2012). Femoral head and neck Osteotomy (FHO) surgery is a common procedure performed on the coxofemoral joint, aiming to reduce bony contact between the femoral head and acetabulum and facilitate the formation of a false joint (pseudoarthrosis) composed of dense fibrous tissue (Barr *et al.*, 1987). Conditions that may prompt consideration for an FHO procedure include aseptic necrosis of the femoral head (Legg-Calvé-Perthes disease), joint laxity, hip luxation, osteoarthritis, fractures involving the hip bones, hip dysplasia, and complications arising from total hip replacement surgery (Ozaydinet *et al.*, 2003).

Materials and Methods:

Ten dogs with coxofemoral joint affections were included in the study which were presented to the Madras Veterinary College Orthopedic Outpatient Unit. Following a general examination, a thorough orthopedic assessment was carried out, documenting details such as weight-bearing status, age, breed, and cause of the condition. Among the recorded cases, coxofemoral joint affections encompassed hip dysplasia, hip luxation, and femoral capital fractures.

Hip dysplasia and femoral capital fractures were addressed through Femoral Head and Neck Osteotomy (FHO). For cases involving hip luxations where the event

duration was short, closed reduction was performed followed by the application of an ehmer sling. However, for cases of luxation with dysplastic hips, FHO was preferred since these dogs were not suitable candidates for closed reduction. In cases where the hip configuration was good, these were treated with toggle pin procedure.

All the cases were premedicated with Inj. Butorphanol 0.2mg/kg + Inj. Xylazine 0.5 mg/kg i/m followed by Inj. Diazepam 0.2mg/kg i/v and Inj. Ketamine 6mg/kg i/m and maintained with Isofurane in 100% oxygen.

After aseptic preparation of the surgical site, the dogs were positioned in lateral recumbency with the affected leg facing upward. A curved skin incision was made slightly cranial to the greater trochanter, followed by dissection of the subcutaneous tissue in the same plane. The plane between the tensor fascia lata and biceps femoris muscles was incised and separated. The tensor fascia lata was then retracted cranially, while the biceps musculature was retracted caudally. The superficial and middle gluteal muscles were identified and retracted dorsally without excision of the musculature or tendinous insertions. Partial tenotomy of the deep gluteal muscle near its insertion on the greater trochanter was performed, followed by identification and incision of the underlying hip joint capsule in a radial fashion along the acetabulum and onto the femoral neck.

The femoral head was dislocated by rotating the leg such that the patella faced the ceiling, and the teres ligament was cut. Using an oscillating saw, head and neck osteotomy was performed from the greater trochanter to the lesser trochanter, and any bone spurs were rasped using a rasper. The joint capsule was then sutured using PGA in an appositional manner, followed by suturing of the deep gluteus in a cruciate pattern and the tensor fascia lata to the biceps femoris in a continuous manner, and finally, closure of the subcutaneous tissue and skin.

In the treatment of a hip luxation case, a toggle pin technique was utilized. The procedure began by accessing the femur head and acetabulum, followed by performing an osteotomy of the greater trochanter. With the aid of an aiming device, a hole was drilled from the lateral aspect of the femur into the femur head, and another hole was drilled into the acetabulum. A toggle pin, connected with Polyester 1, was then passed through the acetabulum and the other end through the femur head, securely tying it in place. Subsequently, all muscles were closed using standard techniques.

Table1: Depicting about age, sex, presentation, surgery

S.no	Breed	Age	Sex	Presentation	Surgery
1	Golden retriever	1Y	Female	Hip	Femur head and neck

				dysplasia	ostectomy(FHO)
2.	Labrador retriever	10M	Male	Hip dysplasia	FHO
3.	Labrador retriever	6 M	Male	Hip dysplasia	FHO
4.	German shepherd	8 M	Male	Hip dysplasia	FHO
5.	Labrador retriever	3Y	Male	Hip dysplasia	FHO
6.	Spitz	6Y	Male	Capital fracture	FHO
7.	Spitz	9 M	Female	Hip luxation	FHO
8.	Spitz	4 M	Male	Femur head fracture	FHO
9	Labrador retriever	2 Y	Male	Hip luxation	FHO
10	German shepherd	2 Y	Male	Hip luxation	Toggle pin

M: Months;Y: year; FHO : Femoral head and neck Ostectomy

All the cases were advised, orally Tab Amoxicillin+ clavulinicacid 12.5mg/kg BID for 5days, addressing pain Tab carprofen 2.2 mg/kg BID for 4days, Elizabethan collar round the clock and cold fomentation for first 48hours followed by hot fomentation for next subsequent 48 hours on the surgical site. Furthermore, owners were instructed to perform passive range of motion exercises and engage in short leash walks for the first two weeks, gradually transitioning to longer walks to facilitate the dog's adjustment to full ambulation strength as soon as possible.

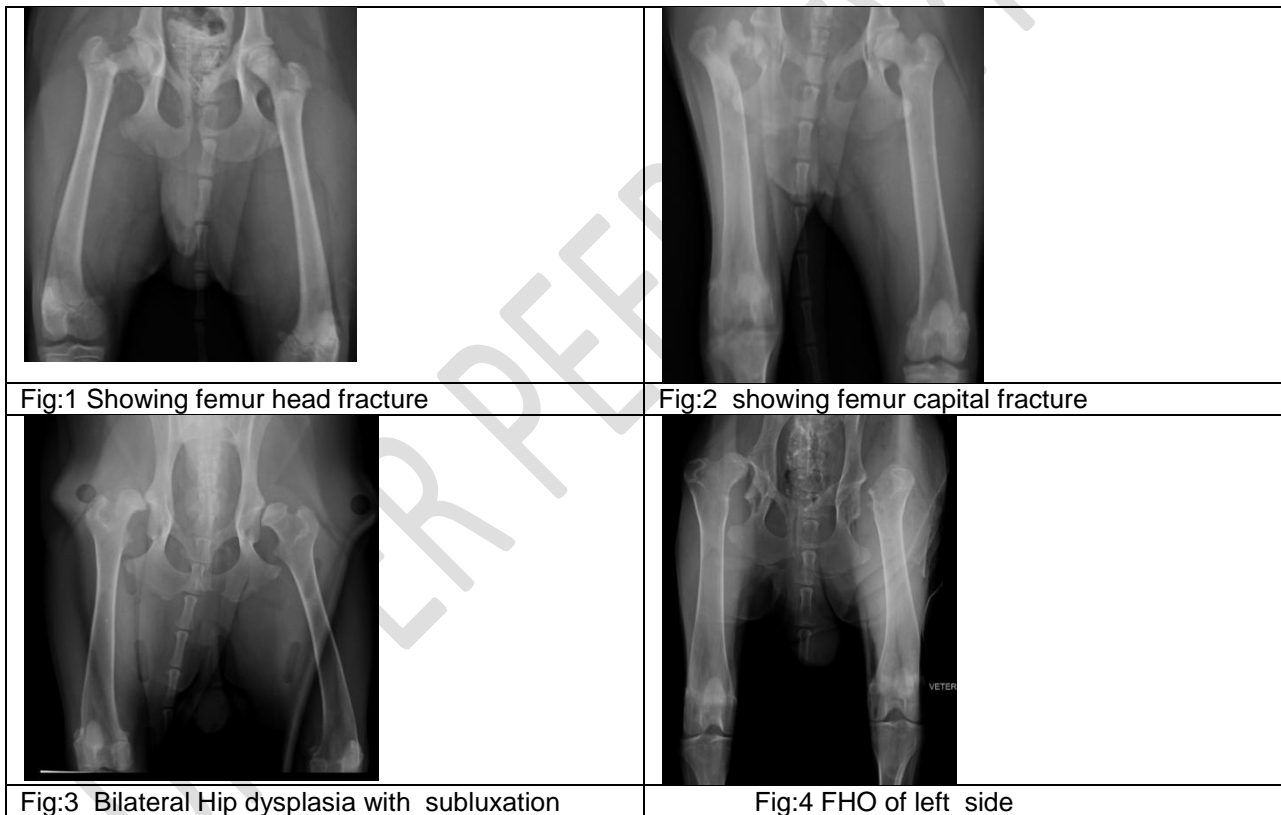
Results:

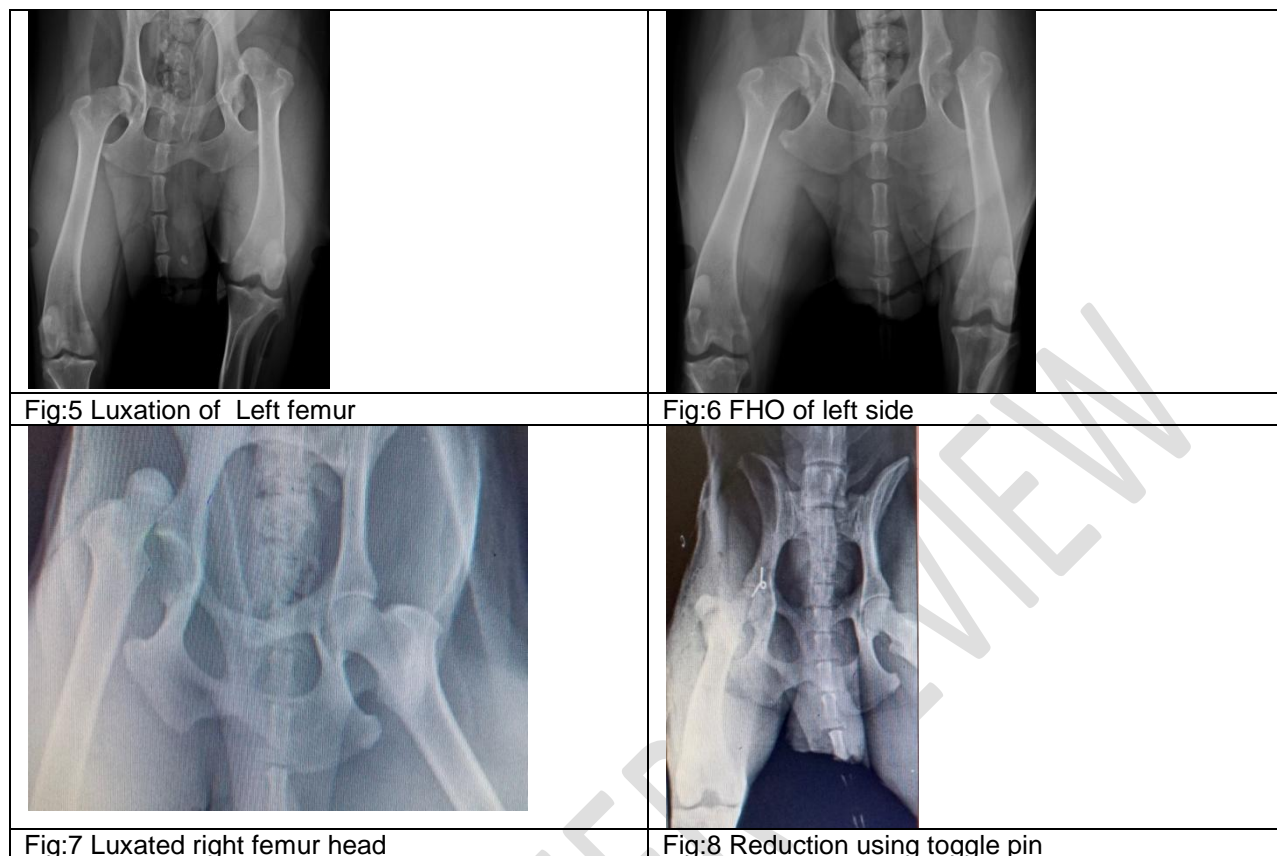
The Labrador Retriever was the most frequently affected breed (n=4), with three cases presenting hip dysplasia and one with hip luxation. Following this were Spitz dogs, where cases of hip luxation, femoral head fracture, and capital fracture were noted. Additionally, there was one case each of hip dysplasia in a German Shepherd, Golden Retriever and along with one case of hip luxation in a

German Shepherd. Among these cases, eight were male and two were female. Except for one case, all dogs underwent femoral head and neck osteotomy. The toggle pin technique was chosen for the remaining case with hip luxation.

Upon presentation (Case 2), the Labrador retriever, exhibited severe atrophy of thigh muscle, bunny hopping gait. Passive range of motion exercises were advised to restore muscle mass before surgery, as this would significantly impact the surgical outcome. Following improvement in muscle mass, a Femoral Head Osteotomy (FHO) was performed. Initially, the animal was non-weight bearing for the first 5 days, gradually transitioning to occasional weight bearing for the subsequent 7 days. Complete weight bearing was achieved by the 22nd day.

Labrador Retriever dogs (Case 3 and 5) exhibited weight bearing on the first postoperative day, achieving full strength by the 12th day. The German Shepherd (Case 4) had severe muscle atrophy, presenting challenges in mobility after resting before surgery. Following the operation, the animal began bearing weight after 3 days postoperatively (Fig: 3 &4)). While the activity of the animal improved thereafter, a slight difference in gait persisted.





In the case of a Spitz dog (Case 6) presenting with a capital fracture (Fig: 2), FHO was selected over fixation due to the absence of a fragment suitable for rigid stabilization. Weight bearing was observed from the second day onwards. Another Spitz (Case 7) with hip luxation experienced recurrent luxation despite initial close reduction and application of an Ehmer sling. Upon re-evaluation after 10 days, intermittent lameness and pain during flexion and extension of the hip joint noted. Therefore, FHO was chosen as a treatment option to enhance the quality of life.

Following an automobile trauma, a Labrador Retriever (Case 9) began exhibiting non-weight bearing on the left hind limb. Examination revealed palpation of the femur head outside the acetabulum, accompanied by crepitus upon flexion and extension of the hip joint, indicative of hip luxation which was confirmed by radiography as same (Fig: 5 and 6). Given the shallow acetabulum, attempts at reduction were deemed inappropriate, leading to the direct selection of FHO. On the first postoperative day, the animal began bearing weight, and by the tenth day, full strength was regained.

A German Shepherd (Case 10) presented with non-weight bearing lameness following an incident of high-rise syndrome. Radiographic examination confirmed hip luxation, for which the toggle pin technique was employed for fixation. Subsequently, the animal was placed in an Ehmer sling for a two-week period(Fig:7& 8). After this duration, the animal fully regained its range of motion and began bearing weight on the affected limb.

Discussion:

Majority of the femoral head and neck affections were surgically treated using femoral head and neck osteotomy. The objective is to enhance dog's quality of life by enabling pain free movement during

activity. Many dogs diagnosed with hip dysplasia experience thigh muscle atrophy because of improper weight distribution on those limbs. To achieve the best surgical outcomes, it's crucial to have adequate muscle mass, as these muscles play a key role in supporting the leg. Hence, physical therapy and passive range of motion exercises were suggested to build muscle mass before surgery, aiming for a positive outcome (Linset *et al.*, 2009). (Pilli *et al.*, 2023) reported higher incidence of hip dysplasia in Labradors and German Shephard dogs. Before surgery, attempts were made to reduce hip dislocations in all cases after inducing general anesthesia. This practice facilitates anatomical dissection for accessing the hip joint, consistent with the findings of (Harper, 2007).

In the study, (Kuzma *et al.*, 1989). utilized cortical screws inserted in a lag fashion from the articular surface of the femoral neck to treat femoral capital fractures. However, this approach resulted in premature closure of the capital growth plate and mild limb shortening in young dogs. Consequently, all cases in this study were managed with femoral head ostectomy (FHO). (Slatter, 1993), hip luxation primarily manifests in a craniodorsal position, a finding consistent with our study, where all three cases of hip luxation demonstrated craniodorsal positioning of the femoral head. (Harper, 2017), FHO serves as a salvage surgical procedure in dogs. Prognosis is usually good to excellent for return to normal or near-normal function of the limb. Active use of the limb may take more than 1 month. This result was accepted in this study as all cases took time for complete regaining of strength for use of the limb.

The present study findings align with the notion that the craniolateral approach offers excellent visibility of both the femoral head and acetabulum (Brinker *et al.*, 1990). All osteotomies were conducted with an oscillating saw which was convenient and facilitated precise cuts. This aligns with (Seddawy's, 2022) observation that oscillating saws are superior to Gigli wire for effectively severing the femoral neck from its base and (Harper, 2017) also opined that the oscillating saw is preferred over an osteotome for its precision in making smooth cuts and extended that in pets with chronic limb disuse atrophy, using an osteotome is discouraged due to the bone's osteopenic nature, which increases the risk of shattering and potential fractures in areas like the greater trochanter or femoral shaft.

Gait changes were common in the majority of cases in this study following femoral head ostectomy (FHO). The biomechanics of the hind limb change following FHO because the femoral head no longer articulates with the acetabulum and a fibrous false joint is present. muscle atrophy, and decreased stifle and hock angles, as well as restricted extension of the hip This results in a change in gait due to limb-shortening, dorsal displacement of the femur (Roush, 2012). Canine limbs treated with FHO had significantly lower peak vertical, peak propulsive, and impulse propulsive forces compared to the normal limbs (Grisneaux *et al.*, 2003). Return to maximal function following FHO can take as long as 6 months and depends on the chronicity of disease before surgery. The gait abnormality may be more obvious in dogs undergoing unilateral FHO, because of the structural difference between the two hind limbs after surgery (Rawson *et al.*, 2005).

CONCLUSION:

FHO is a simple, relatively inexpensive, surgical procedure that can be used to alleviate pain in the coxofemoral joint. Proper surgical technique, appropriate postoperative analgesia, and aggressive postoperative physical therapy are necessary to maximize function in the limb.

References:

1. Barr AR, Denny HR, Gibbs C. Clinical hip dysplasia in growing dogs: the long-term results of conservative management. *Journal of Small Animal Practice.* 1987,28(4):243-52.

2. Brinker WO, Piermattei DL, Flo GL. Handbook of small animal orthopedics and fracture treatment. WB Saunders Co.; 1983.
3. El-Seddawy FD, El-Mezayen AF, Tantawy MF, Gomaa M. Femoral Head and Neck Osteotomy (FHO) for Treatment of Different Hip Joint Disorders in Dogs. *Journal of Advanced Veterinary Research*. 2022,12(4):422-5.
4. Fossum TW. Diseases of the joints. Small animal surgery. 4th edition. St Louis (MO): Elsevier Mosby; 2012, 1305–16.
5. Grisneaux E, Dupuis J, Pibarot P, Bonneau NH, Charette B, Blais D. Effects of postoperative administration of ketoprofen or carprofen on short-and long-term results of femoral head and neck excision in dogs. *Journal of the American Veterinary Medical Association*. 2003,1;223(7):1006-12.
6. Harasen G. The femoral head and neck osteotomy. *The Canadian Veterinary Journal*. 2004,45(2):163.
7. Harper TA. Femoral head and neck excision. *Veterinary Clinics: Small Animal Practice*. 2017,1;47(4):885-97.
8. Harper, M.A.T., 2017. femoral head and neck excision, *Vet Clinic North Am. Small Animal Practice* 47, 885-897
9. Kuzma A, Sumner-Smith G, Miller C, McLaughlin R. A technique for repair of femoral capital epiphyseal fractures in the dog. *Journal of Small Animal Practice*. 1989,30(8):444-8.
10. Lins, BT., Selmi, AL., Souza, SS., Custodio, P. World Small Animal Veterinary Association World Congress Proceedings luxation by the transposition of the ligamentum sacrotuberous in dogs: an in vivo study. *Veterinary Surgery*. 2009, 32, 46-51.
11. Özyaydin İ, Kiliç E, Baran V, Demirkan İ, Kamiloglu A, Vural S. Reduction and stabilization of hip luxation by the transposition of the ligamentum sacrotuberale in dogs: an in vivo study. *Veterinary Surgery*. 2003, 32(1):46-51.
12. Peycke, Laura E. "Femoral head & neck osteotomy." (2011): 55-59.
13. Pilli M, Seyrek Intas D, Etikan I, Yigitgor P, Kramer M, Tellhelm B, von Puckler K. The Role of Femoral Head Size and Femoral Head Coverage in Dogs with and without Hip Dysplasia. *Veterinary Sciences*. 2023, 10(2):120.
14. Rawson EA, Aronsohn MG, Burk RL. Simultaneous bilateral femoral head and neck osteotomy for the treatment of canine hip dysplasia. *Journal of the American Animal Hospital Association*. 2005, 41(3):166-70.
15. Roush JK. Surgical therapy of canine hip dysplasia. *Veterinary surgery: small animal*. 2012;1:849-64.
16. Smith GK, Karbe GT, Agnello KA, McDonald-Lynch M. Pathogenesis, diagnosis, and control of canine hip dysplasia. *Veterinary surgery: small animal*. 2011,1:824-48.