

Case report

Overlap syndrome: Systemic lupus erythematosus and ANCA vasculitis in a case report

Abstract:

Introduction Microscopic polyangiitis is a systemic necrotising vasculitis that predominantly affects small-calibre vessels. It may be associated with systemic lupus erythematosus (SLE) as part of an overlap syndrome, but there are very few reports of this in the literature. **Case report** We report the case of a 19-year-old patient admitted with moderate haemoptysis, epistaxis and petechial pupura revealing intra-alveolar haemorrhage with a strongly positive P-ANCA. In addition, blood tests for antinuclear antibodies and rheumatoid factor were positive, with renal involvement suggesting associated lupus as part of an overlap syndrome. Progression was good with treatment. **Conclusion** The clinical presentation of overlap syndrome is rare and severe, with a dual immunological profile of antinuclear antibodies and neutrophil cytoplasm.

Introduction

Microscopic polyangiitis is a systemic necrotizing vasculitis that predominantly affects small-caliber vessels. The most typical clinical manifestations are extracapillary glomerulonephritis and alveolar hemorrhage. This is a vasculitis associated with neutrophil cytoplasmic antibodies (ANCA). The p-ANCA type, with anti-myeloperoxidase specificity, is found in 75-80% of patients. ANCA is negative, but may be associated with systemic lupus erythematosus (SLE) as part of an overlap syndrome. Very few reports of this condition have been published in the literature.

Case report

We report the case of a 19-year-old female patient with no previous pathological history who was admitted for moderate hemoptysis, associated with epistaxis and petechial purpura, with generalized mucocutaneous pallor, all of which had been evolving for 3 months in a context of declining general condition. The patient was admitted to hospital on an emergency basis, with conditioning and injections of haemostatic treatment.

Chest imaging revealed an interstitial syndrome with bilateral ground-glass, predominantly at the bases (figure 1).

Blood count was consistent with poorly tolerated iron-deficiency hypochromic microcytic anemia, with a hemoglobin level of 4.8g/dL, for which the patient received 3 packed red blood cells. Sedimentation rate was accelerated and CRP was elevated to 54mg/l. An emergency bronchioloalveolar lavage confirmed intra-alveolar haemorrhage on macroscopic examination (figure 2), with a Golde score of over 20. In the search for ENT involvement, nasofibroscopy showed inflammation with nasal ulceration of the inferior turbinate and bulging of the upper wall of the cavum, and a biopsy was unremarkable.

The Blondeau scan revealed a deviated nasal septum with no evidence of acute or chronic sinusitis (figure 3). The renal work-up was in favor of a pure nephrotic syndrome, with 24h proteinuria at 3.5g/24h and albuminemia at 25g/L. Renal ultrasound was unremarkable, so a renal biopsy was indicated. The blood immunoassay showed strongly positive P-ANCA. The diagnosis of microscopic polyangiitis was thus accepted according to the diagnostic criteria described in the guide to long-term illnesses. The renal work-up revealed a pure nephrotic syndrome, with 24h proteinuria at 3.5g/24h and albuminemia at 25g/L. Renal ultrasonography was unremarkable, so a renal biopsy was indicated. The biopsy showed stage 3 extramembranous glomerulonephritis with vascular deposition of IgG, IgM and C3. In addition, blood tests for antinuclear antibodies and rheumatoid factor were positive at 320 and 16.06 IU/ml respectively. Thus, the patient also met the diagnostic criteria for SLE according to the EULAR/ACR classification. The patient was started on bolus corticosteroids, followed by oral corticosteroids at a dose of 1mg/kg/d with progressive tapering, then bolus cyclophosphamide at 3-week intervals, followed by azathioprine.

Hemoptysis subsided with radiological clearance (figure 4).

Discussion

Overlap syndromes are defined by the presence of criteria for several systemic diseases (at least two) at the same time in the same patient [1]. Unlike systemic lupus erythematosus (SLE), ANCA vasculitides (AAV) have rarely been associated with other autoimmune diseases [2]. The LES /VAA overlap syndrome is a rare condition defined by the existence of a systemic disease meeting both LES and VAA classification criteria. The diagnosis of LES may precede, follow or be concomitant with that of VAA, as was the case in our patient. Females were frequently involved.

SLE and AAV are two autoimmune diseases that differ in their autoantibody profile (antinuclear AAN antibodies in SLE and anti-neutrophil cytoplasm antibodies in AAV), resulting in different systemic involvement. Renal involvement is common in both diseases, and is of the glomerulonephritis type with immune complex deposits in LES, and of the pauci-immune extracapillary glomerulonephritis type without immune complex deposits in VAA[3,4].

Although rare, the LES/AAV overlap syndrome could be explained by immunopathological mechanisms common to both LES and AAV, in particular neutrophil activation and the involvement of ketosis, a cellular immune process that affects neutrophil polynuclear cells, releasing fibers composed of DNA and proteins called NETs, whose function is to trap pathogenic microorganisms. Significant netosis and impaired clearance of NETs are involved in the pathophysiology of tissue damage observed in various autoimmune diseases and small-vessel vasculitides [5]. The occurrence of SLE and VAA has been reported under anti-TNF therapy [6].

In patients with lupus nephropathy, overlapping histological lesions with necrotizing extracapillary glomerulonephritis, as defined for vasculitis, make the diagnosis of an overlap syndrome. This may be associated with granulomatous inflammation of the entire respiratory tract in the LES/Wegener association, eosinophil-rich granulomatous inflammation of the respiratory tract associated with asthma and hypereosinophilia in the LES/granulomatosis eosinophilia with polyangiitis association, pneumo-renal syndrome without granulomatous inflammation in the LES/microscopic polyangiitis association, and with or without ANCA positivity by IFI and/or ELISA. In the case of extra-capillary necrotizing glomerulonephritis of a VAA diagnosed 1st, overlapping histological lesions with the presence of unexpected deposits of immune complexes (C3, IgG, C1Q) or validation of at least four diagnostic criteria for LES, including ANCA, and/or anti-DNA-native positivity will make the diagnosis of an

overlap syndrome [7,8].

An overlap syndrome is excluded in patients with lupus nephropathy associated with the presence of ANCA only, without clinical or histological arguments for ANCA vasculitis, or in patients with necrotizing extracapillary glomerulonephritis associated with the presence of antinuclear antibodies (ANA) or native anti-DNA but without clinical or histological arguments for SLE or positivity of antibodies directed against the glomerular basement membrane [3]. It should be noted that genuine vasculitis can occur in the course of SLE, but rarely meets the criteria for classification as AAV [9].

Currently, there are no treatment guidelines, and management decisions are often left to clinicians, depending on the predominant features of ANCA disease or lupus nephritis at the time of presentation [10]. Systemic corticosteroid therapy in the form of a bolus of methylprednisolone, 1 g/day for 3 days, followed by prednisone at a dose of 1mg/kg/day, combined with a synthetic antimalarial (hydroxychloroquine) has been described in the literature[11] . Accelerated biopsy and initiation of treatment are crucial to preserve renal function[12] Plasma exchange in patients with severe ANCA-associated vasculitis did not reduce the incidence of death or end-stage renal disease. However, it has been shown to be beneficial in patients with diffuse alveolar hemorrhage, compared with patients without diffuse alveolar hemorrhage[13].

Conclusion

The association of LES and VAA with renal involvement remains rare. The clinical presentation of LES/VAA overlap syndrome is severe, with a dual immunological profile of AAN and neutrophil anti-cytoplasm. In our patient, the evolution was favorable under treatment, but strict monitoring remains important to detect a potentially serious relapse.

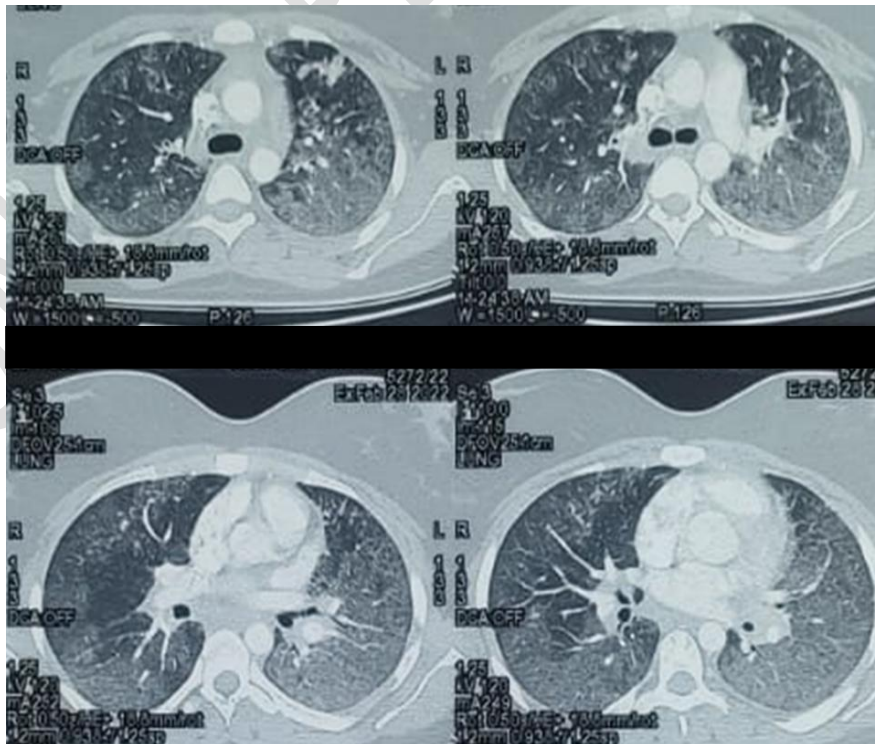


Figure 1: Chest CT scan showing diffuse ground-glass appearance

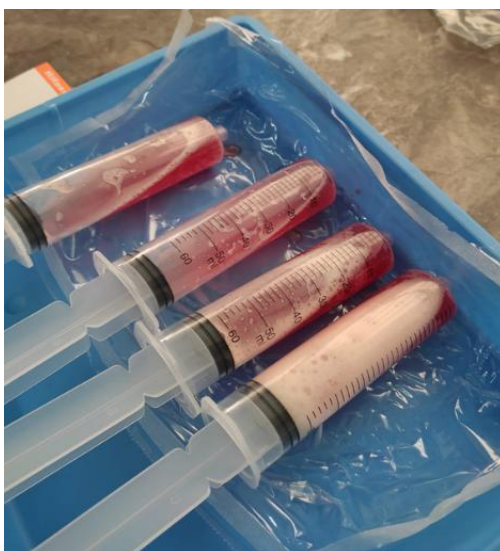

Figure 2: Macroscopic appearance of frankly haemorrhagic bronchoalveolar lavage.

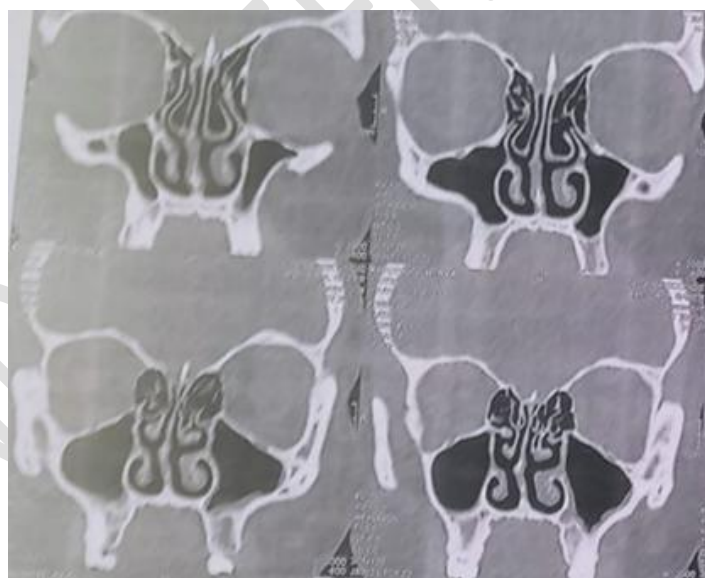

Figure 3: Blondeau scan in favour of a deviated nasal septum.

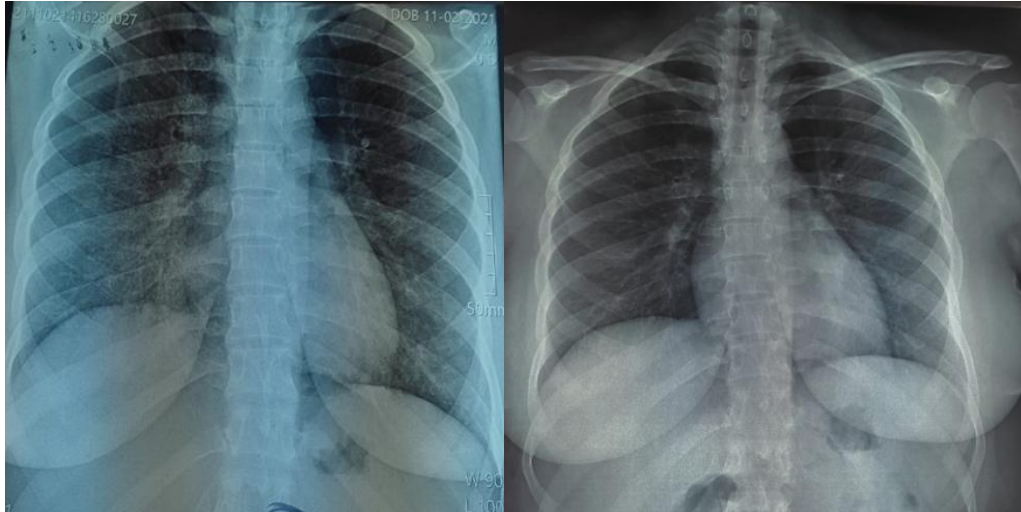


Figure 4: Radiological clean-up after 3 months of treatment

References :

- [1] Autoimmune pathologies: epidemiological aspects, diagnosis and treatment principles COFER (French College of Teachers in Rheumatology) Item 192 EU VIII
- [2] T. Quemeneur et al. Systemic vasculitis during the course of systemic sclerosis: report of 12 cases and review of the literature *Medicine (Baltimore)* (2013)
- [3] Jennette JC, Falk RJ, Bacon PA, et al. "Consensus Conference Nomenclature of Vasculitis." *Arthritis Rheum* 2013.
- [4] Piette JC, Amoura Z, Francès C. "Systemic lupus erythematosus. Antiphospholipid syndrome" *Rev Prat.* 2003;53:2175-82
- [5] Poli.C et al. Netosis and autoimmunity. *Revue Francophone Des Laboratoires*, 2014(462), 59–63.
- [6] N. Jourde-Chiche et al. ANCA vasculitis – lupus overlap syndrome occurring after introduction of anti-TNF treatment: report of a case
- [7] Chin HJ, Ahn C, Lim CS et al. "Clinical implications of antineutrophil cytoplasmic antibody test in lupus nephritis." *Am J Nephrol* 2000;20:57-63
- [8] Hervier B, Hamidou M, Hanoche J et al. " Systemic lupus erythematosus associated with ANCA-associated vasculitis: an overlapping syndrome?" *Rheumatol Int* 2011; 32:3285-90
- [9] Nishiya K, Chikazawa H, Nishimura S et al. "Anti-neutrophil cytoplasmic antibody in patients with systemic lupus erythematosus is unrelated to clinical features." *Clin Rheumatol* 1997;16:70-5
- [10] Jaclyn Khil et al. Systemic lupus erythematosus and ANCA-associated vasculitis overlap syndrome: a case report *Rein Med.* November 2022; 4(11): 100544.

[11] Neirouz Ghannouchi Jaafoura et al. Granulomatous polyangiitis with eosinophilia associated with systemic lupus erythematosus biology Department of Internal Medicine, Farhat Hached University Hospital, avenue Ibn el Jazzar, Tunisia

[12] Jayne DR, Gaskin G., Rasmussen N. et al. Randomized trial of plasma exchange or high-dose methylprednisolone as adjunctive therapy for severe renal vasculitis. *J Am Soc Nephrol.* 2007; 18 (7): 2180-2188. [PubMed] [Google Scholar]

[13] Walsh M., Merkel PA, Peh CA et al. Plasma exchange and glucocorticoids in severe ANCA-associated vasculitis. *N Engl J Med.* 2020; 382 (7): 622-631. [PMC free article] [PubMed] [Google Scholar]

UNDER PEER REVIEW