

Lateral Pectus Carinatum and Non-surgical treatment: A case report

ABSTRACT

Aims: The objective of the present work is to describe a congenital bone deformity known as Pectus Carinatum, being a prominence generated in the anterior region of the chest wall, in the regions of the manubrium of the sternum.

Presentation of Case: The first contact with the patient was in February 2023 and ended in September 2023. The study is of a descriptive observational nature and data collection was carried out through interviews and photographic records, the patient was approached peacefully, and he agreed to inform his clinical case.

Discussion: This study is based on a case report of a male patient, 16 years old, from Tocantins, with the condition of Lateral Pectus Carinatum which performed the non-invasive dynamic chest compression procedure (DTC) in the Federal District. Thus, together with the doctor responsible for the case, the patient's legal representatives authorized the study through the medical records of the consultations over a period of 1 year. After the aforementioned period of treatment, correctly, it showed great progress in decreasing prominence, without the need for an invasive procedure.

Conclusion: This study aims to better understand the anatomical deformity and verify possible diagnostic and prognostic methods, in order to guarantee a better quality of life for the patient.

Keywords: [Pectus Carinatum, Case Report, Orthopedics]

1. INTRODUCTION

Pectus Carinatum (PC) or “keel chest” is a congenital bone deformity resulting from the prominence generated in the anterior region of the chest wall, specifically in the regions of the manubrium or body of the sternum bone, the latter being the one with the highest incidence. This condition is mostly asymptomatic, and in most of its presentations it generates simple complications such as aesthetic discomfort, however when symptomatic there is increased sensitivity at the site, decreased chest expansion and in more severe cases dyspnea and tachypnea on exertion¹. The prognosis of such a condition is good considering that, in the long

term, adverse effects on the patient's health are rare and the deformity can be corrected when desired, either by minimally invasive surgical procedures or by correction through restriction by external orthoses².

The diagnosis of PC is generally carried out during adolescence, because although this deformity presents itself from the first moments of childhood, recognition becomes easier in this age group, in which the individual experiences greater growth. Its incidence may be related to other conditions such as Marfan Syndrome and Morquio Syndrome (One of the mucopolysaccharidoses, resulting from genetic transmission, which occurs in the absence of lysosomal enzymes that degrade mucopolysaccharides, molecules that play an important role in the structural function of tissues, cellular interactions and regulation of cellular metabolism. In the case of Morquio's syndrome, type IV mucopolysaccharidosis is found, with deposition and accumulation of these molecules, resulting in phenotypes of significant anatomical structural changes.) making it special in terms of treatment approach in some cases. In Brazil, the deformity has an incidence of 1:1000 adolescents, it is estimated that worldwide it may be present in up to 5% of the population, being more common in males in proportions of 4:1. It is important to highlight that in clinical interest the phenomenon of Pectus Excavatum (PE), which in turn presents itself as a retraction in the anterior region of the thorax, has attracted more attention within the class of chest wall deformities with a predominance variable between 3:1 and 13:1¹.

As for treatments, they can be surgical or not, surgical treatments can be further divided into resective and non-resective. As a first choice in cases where the sternum is rigid with little or no articulation and associated with malformations. The open resective surgical technique consists of the resection of the rib cartilages with preservation of the perichondrium, associated with sternal osteotomies fixed with bars that can be removed later². As for the minimally invasive surgical technique, the option is for thoracoscopic resection to occur. by multiple short chondral and segmental rib resections under the intrathoracic aspect, while there is also extrathoracic resective thoracoscopy that uses a subpectoral dissection of the pectoral muscles performed with carbon dioxide, which after this, will give freedom for a small incision of 2.9 - 4.7 cm and portal holes. Although advantageous, surgical procedures can cause keloids, damage to soft tissues and in some cases excessive blood loss during the operation³.

Still among surgical treatments, non-resective thoracoscopy performed through incisions lateral to the chest, generates better aesthetics, less blood loss and reduced operative time. In more compliant cases of PC, it is now understood that the first choice, aiming at non-surgical intervention, is orthosis therapy, which consists of the use of a dynamic compression system which comprises an initial correction pressure measured through the rigidity of the rib cage, which is necessary to correct the deformity, while at each return to the doctor, adjustments are made to the treatment pressure, which is the pressure exerted continuously¹. It is important to highlight that there is still no consensus on the minimum number of hours of use of the device and whether it can be used on adult individuals, given their complete

development and rigidity of the rib cage³. That said, given the incidence of the disorder as well as the presentation of treatments that are not yet consensual regarding the time spent using orthoses, it is necessary to share data in the individualized treatment of the condition and the search for better approaches to treatment. Despite this, the study by Haje et al. (2021) experienced the compressor and presented evidence of efficacy and treatment time estimation, taking into consideration the severity of each PC. The dynamic chest compression orthosis is used in the treatment of localized pectus excavatum. It consists of two anterior padded plates supported on the lower costal margins and other padded plates in the dorsal region. After the treatment is correctly followed, with at least 24 months of use, the orthosis is gradually removed. The patient's commitment to wearing the orthosis is emphasized for the accuracy of the effectiveness of this treatment².

2. PRESENTATION OF CASE

Male patient, 16 years old, white, single, born in Tocantins, was admitted to a Secondary Care Unit specialized in Orthopedics in January 2012, reporting an anatomical deformity in the anterior chest wall. After a thorough analysis carried out by the doctor, he was referred to a PC specialist in the Federal District – DF, Brazil. There's no family history.

2.1 PHYSICAL EXAMINATION

Good general condition, declared absence of associated cardiorespiratory pathologies, such as asthma and chronic bronchitis. However, when carrying out sporting activities he experiences palpitations and dyspnea. No agenesis of upper limbs was identified. The abnormality in the upper limbs was not identified.

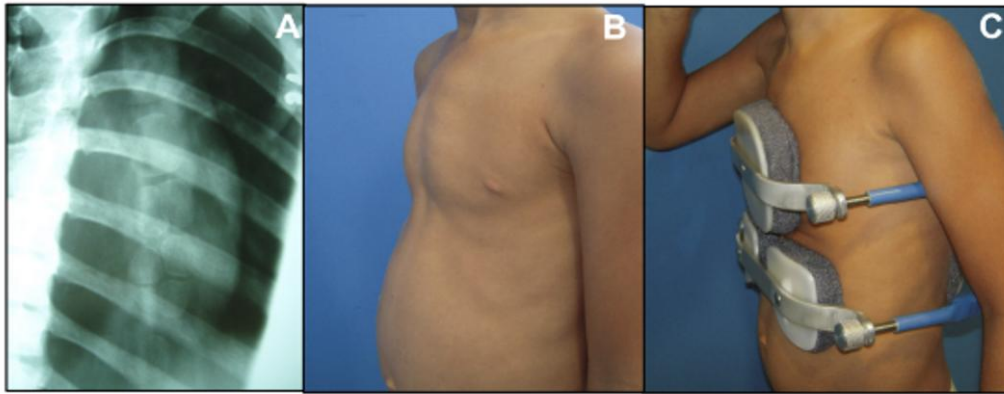
2.2 DIAGNOSTIC HYPOTHESIS

The diagnostic hypothesis of Lateral PC was made on May 15, 2012.

2.3 CONDUCT

The patient was advised to undergo physiotherapy and physical exercises, especially swimming, to help with the prognosis. The X-ray confirmed the need for the Dynamic Chest Compressor (DTC), (Figure 1) and treatment is expected to be completed in two years, that is, in May 2014.

Fig.1 Evolution before and after the use of DTC



Legend: (A) X-ray of the anterior chest wall; (B) Before using DTC; (C) After placing the DTC.

2.4 EVOLUTION

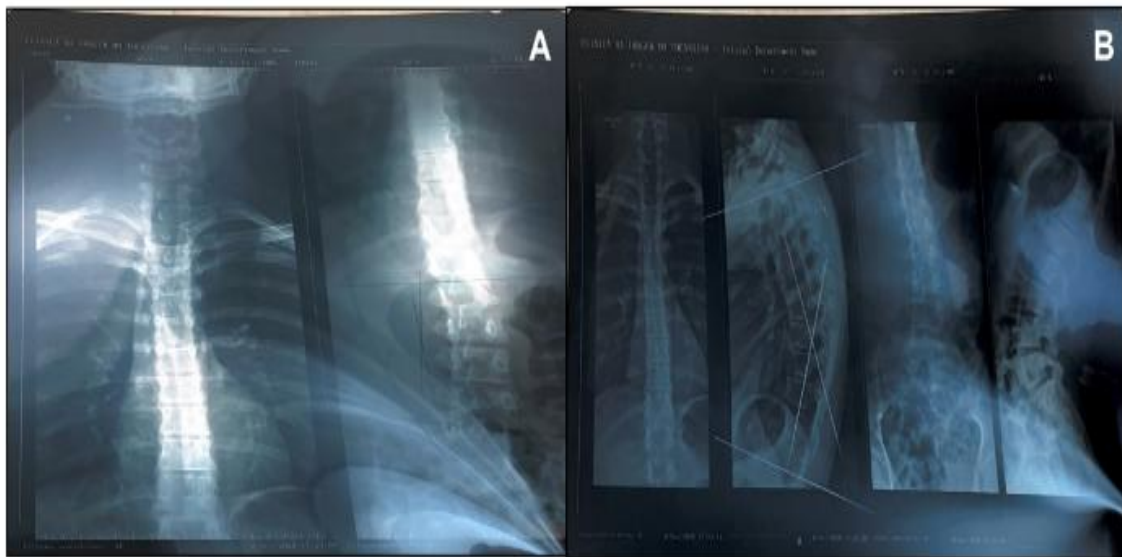His treatment was scheduled to end in May 2014. However, unfortunately, the doctor responsible died. Therefore, he was unable to complete the therapeutic intervention within the previously stipulated period. The patient used the CDT during the age range consisting of childhood and adolescence (06 to 16 years of age). He reported aesthetic and emotional implications, being introverted and withdrawn, not practicing physical exercises that expose the chest. And he didn't seek psychological support. After six years, in November 2020 he found a new specialist in

PC to continue the prognosis. During this period, he developed physical complications, such as increased anatomical deformity, exacerbated thoracic kyphosis (ICD: m400 M954), mild signs of scoliosis (ICD-10 M41) and shortening of the posterior chain (Figure 2). The patient stated that in adolescence the signs of the clinical entity became more evident.

In relation to social life, during childhood it was easier, considering that his colleagues did not show a critical eye, on the contrary, the children supported him during the treatment, thus being able to use the equipment for 84 hours a week. However, during adolescence, social stigma is exacerbated, reducing the time used for DTC to 3 hours per week. In 2021, a period of pandemic and social isolation, the patient made great progress in his treatment, as he was able to use the device at home for around 126 hours a week. After the pandemic, the return to in-person classes reduced the time to 3 hours per week.

Currently, the use of type 1 and 2 DTC, physiotherapy, stretching, going to the gym three times a week, topical use of creams to alleviate skin irritations due to prolonged use of the equipment is recommended. The patient denies using the device in public and busy environments, uses the DTC about 3 hours a week, goes to the gym four times a week and has never gone swimming. He reports that these are small details to align the anterior chest wall and the deformity does not bother him as much as it did in the past.

Fig. 2. Radiological evaluation of the case



Legend: A) Scoliosis X-ray; (B) X-ray of thoracic kyphosis

3.DISCUSSION

The etiology of PC is not fully known, but the literature suggests that its occurrence is related to factors acquired throughout the patient's life or congenital aspects⁹. Studies show that congenital factors are associated with: family history¹⁰, presence of the deformity at birth, congenital heart disease and hand agenesis¹¹.

However, experimental research in rats has shown that variability in the shape of the thorax is generated due to contiguous lesions¹².

PC does not receive the same attention as PE, and its treatment is still unknown to many doctors, such as pulmonologists, pediatricians and thoracic surgeons, and lack of knowledge of the correct procedures leads to patients not being referred. According to Migliavacca⁴, this fact is due to the predominance of 5 times more PE in relation to PC. The prevalence of this change most frequently affects whites and Latinos and is uncommonly found in blacks and Asians. Coelho² in his study highlights the incidence of 0.6 to 0.97 for every 1000 adolescents, being more frequent in men.

The patient covered in the present study does not have any cardiorespiratory disease, but reported palpitations and dyspnea when performed sports activities. The cause of its occurrence can be congenital or acquired, as PC is rarely noticed at birth, it is believed that its occurrence is more acquired than congenital. PC can occur in three ways: inferior, superior and lateral (situation of the patient in this report). Even though surgical modality is the most used method in the last 50 years, Martinez-Ferro⁵ point out other methodologies for treatment, such as the use of the Nuss bar, introduced through 2-3cm incisions passing through the highest point of the protuberance to the other side, to put pressure on bone formation. However, due to the great surgical risks, this treatment method was reserved only for severe cases.

In the study of Maddali³, it was shown that PC can occur after medical action in pediatric heart surgery. One of the characteristics addressed by this patient was the stigma when using the DTC, as its use decreased considerably after the post-pandemic period, when he returned to attending the educational institution. Coelho² mentions that the psychological implications lead patients to be introverted, withdrawn and have an inferiority complex, which makes it difficult to accept treatment and guarantee satisfactory results.

In the study by Haje⁶, it was shown that the flexibility associated with regular use of the device generated a positive result in 83% of patients, with $p=0.005$. With the support of the literature providing evidence of the great effectiveness of the use of DTC, in addition to having minimal negative effects, this method requires long-term patient adherence to treatment in order to be effective. However, Wahba⁸ mentions that prolonged, continuous use ends up being ineffective as it causes discomfort to the patient, such as pain, social anxiety and skin problems. Therefore, during his study of the prolonged use of DTC, it was found that intense use of this technique has the same effectiveness as using it for a shorter period of time.

Therefore, the patient in this report did not need to undergo an invasive procedure such as surgery that could expose risks, proving that the non-surgical technique has a similar cosmetic efficacy. Therefore, patients should undergo the non-surgical technique first, and only opt for it in cases that do not respond to DTC. Otherwise, the DTC allowed orthopedic and aesthetic treatment to be carried out without any surgical procedure.

5. CONCLUSION

Therefore, the patient was successful in reducing the prominence in the chest using a non-invasive method such as DTC, but it was difficult to use due to aesthetics and psychological factors of living in society. During the pandemic, due to social isolation, the patient used the non-invasive method for a longer period, obtaining a better result during that time. Furthermore, the DTC allowed orthopedic and aesthetic treatment to be carried out without any surgical procedure. Currently, he still uses DTC, but for a reduced period due to social factors, hence the importance of this work, involving not only the treatment and instigating the search for alternatives that aim to improve treatment and provide greater patient comfort.

ETHICAL APPROVAL (WHERE EVER APPLICABLE)

This research was submitted for approval by the Research Ethics Committee in Brazil, in accordance with CNS resolution 466/2012, as it is research involving human beings and which, directly or indirectly, will involve individuals in their entirety or parts, including the management of information and materials. To this end, the study was approved, with Opinion Number: 6.410.603 and CAAE: 73100723.8.0000.5518, the Free and Informed Consent Form was collected, informing the patient's authorization, in addition to the authorization of the health institution.

REFERENCES

1. McHam B, Winkler L. Pectus Carinatum. In: StatPearls. Treasure Island (FL): StatPearls Publishing; 2023.
2. Coelho M de S, Guimarães P de SF. Pectus carinatum. *Jornal Brasileiro de Pneumologia*. 2007 Aug;33(4):463–74. doi.org/10.1590/s1806-37132007000400017
3. Maddali MM, Valliattu J, Kandachar PS, Thomas E, Nishant AR. Induced Pectus Carinatum. *Journal of Cardiac Surgery*. 2016 Mar 16;31(5):357–60. doi: 10.1111/jocs.12734.
4. Migliavacca C, Laura Vitória Xavier, Thais Caroline Fin, Frighetto J, Pinho K. Abordagem de pectus carinatum na Atenção Primária e seu impacto na saúde emocional do paciente. *Revista Brasileira de Medicina de Família e Comunidade*. 2022 Dec 23;17(44):3495–5. doi: 10.5712/rbmf17(44)3495
5. Martinez-Ferro M, Bellia-Munzon G, Schewitz IA, Toselli L. Pectus carinatum: When less is more. *African Journal of Thoracic and Critical Care Medicine*. 2019 ;25(3). doi:10.7196/AJTCCM.2019.v25i3.019

6. Haje DDP, Haje SA, Volpon JB, et al. Localized Pectus excavatum treated with brace and exercise: long term results of a brazilian technique. *Acta Ortopédica Brasileira*. 2021 Aug;29(3):143–8.doi: 10.1590/1413-785220212903241550
7. Martinez-Ferro M, Fraire C, Bernard S. Dynamic compression system for the correction of pectus carinatum. *Seminars in Pediatric Surgery*. 2008 Aug;17(3):194–200. Doi: 10.1053/j.sempedsurg.2008.03.008
8. Wahba G, Nasr A, Bettolli M. A less intensive bracing protocol for pectus carinatum. *Journal of Pediatric Surgery*. 2017 Nov;52(11):1795–9. doi: 10.1016/j.jpedsurg.2017.01.057.
9. Coelho MS, De Campos JR, Stori WS. Congenital Deformities of the Anterior Thoracic Wall. In: Saad Jr R, Carvalho WR, Ximenes Netto M, Forte V, editors. *General Thoracic Surgery*. São Paulo: Atheneu Publishing House; 2005.p.765-91.
10. Coelho MS, Guilherme EV, Kume MK, Vialle LA. Incidence of thoracic deformities among schoolchildren in Curitiba. *J Pneumol*. 1982;9(Supl):175.
11. Lodi R, Bondioli A, Curti L, Bruni GC, Palmieri B. [Surgical correction of pectus excavatum and carinatum in adults. Report of an unusual case of combined dorsi recti and pectus excavatum] *Minerva Chir*. 1975;30(3):131-8. Italian.
12. Haje SA, Bowen JR, Harcke HT, Guttemberg ME, Bacon CR. Sternal growth disturbances and pectus deformities: an experimental model and clinical correlation. *Ata Ortop Bras*; 1998; 6(2):67-75.