

# **SUBACUTE USE OF AQUEOUS EXTRACT OF WATER MELON(*Citrullus lanatus*) SEEDS MITIGATES AGAINST PYRAMIDAL NEURONAL TOXICITY OF LEAD ACETATE IN ADULT WISTAR RATS.**

## **Author Contribution:**

All authors have equal contributions in completing the present research work. All authors read and approved the final manuscript

## **ABSTRACT**

**INTRODUCTION:** As a reported bio-toxic environmental and industrial pollutant, Lead (Pb) do accumulates in almost all body tissues to cause health complications with the cerebellar region of the central nervous system reported to be more susceptible to cellular distortions. As a flowering plant species of the Cucurbitaceae family, watermelon (*Citrulluslanatus*) is associated with numerous medicinal properties.

**AIM:** This study investigated the possible neuroprotective potential of aqueous extract of *citrulluslanatus* seed on lead acetates-induced neurotoxicity in the Cerebral cortex of adult Wistar rats.

**PLACE OF STUDY:** Department of Anatomy, Faculty of Basic Medical Sciences Olabisi Onabanjo University, Ogun State, Nigeria.

**METHOD:** Twenty(20) healthy adult female wistar rats weighing  $150\pm 50$ g were randomly assigned into 4 groups (n=5). The Control group received 2mls/kg of distilled water, Treatment group (T1) was administered 7.5 mg/kg of lead acetate, Treatment group (T2) was administered 200 mg/kg of aqueous extract of *citrulluslanatus* and Treatment group (T3) was administered 7.5 mg/kg of lead acetate and 200 mg/kg of aqueous extract of *citrulluslanatus* concomitantly orally for fourteen (14) days. H and E and Cresyl violet histological staining protocols and Biochemical assays for SOD, CAT activities and MDA concentration was determined. Data obtained from the study were analyzed using one-way ANOVA and subjected to Turkey's post hoc test from the multiple comparison.

**RESULTS:** Revealed no statistically significant differences ( $p>0.05$ ) in body weight and brain weight changes across groups relative to the control group while SOD and Catalase activities were increased significantly in the Treatment groups compared to control group. Histological findings in control group showed normal histoarchitectural appearance of cerebral cortex Pyramidal neurons while the lead exposed group (T1) revealed features of neurodegenerative changes evident by nuclear shrinkage.

**CONCLUSION:** In summary, *Citrullus lanatus* mitigates against pyramidal neuronal cells distortions following lead acetate induced toxicity in Wistar Rats and also further affirms its antioxidative potential.

**Key words:** Cerebral cortex neuroprotective, lead acetate, *citrulluslanatus*.

## 1.0 INTRODUCTION

### 1.1 LEAD ACETATE

Being a bio-toxic environmental and industrial pollutant, lead (Pb) do accumulate in almost all the body tissue such as the liver, kidneys, lungs and immune system (1). It has been reported the physiological, biochemical, and behavioral effect of this toxic lead in disorder of central and peripheral nervous and cardiovascular systems (2), kidneys, liver and Reproductive system (3)

Lead acetate may induce oxidative stress leading to the generation of free radical and alterations in oxygen free radical scavenging enzymes system or antioxidant and damage membrane structure (4).

Lead acetate does not remain in tissue for long periods, except in bones when it is deposited in an inert form but from which it can be liberated at a later date in sufficient quantity to cause lead poisoning (5).

Lead (II) acetate paper is used to detect the poisonous gas hydrogen sulfide that reacts with lead (II) acetate on the moistened test paper to form a grey precipitate of lead (II) sulfide (6). An aqueous solution of lead (II) acetate is the byproduct of the 50/50 mixture of hydrogen peroxide and white vinegar used in the cleaning and maintenance of stainless steel firearm suppressor (silencers) and compensator. The solution is agitated by the bubbling action of the hydrogen peroxide and the main

reaction is the dissolution of lead deposit within the suppressor by the acetic acid, which form lead acetate (7). Because of its high toxicity, this chemical solution must be appropriately disposed by a chemical processing facility or hazardous materials center (7).

Alternatively, the solution may be reacted with sulfuric acid to precipitate nearly insoluble lead (II) sulfate. The solid may then be removed by mechanical filtration and is safer to dispose of than aqueous lead acetate (8). Sugar of lead was a recommended agent added to linseed oil during heating to produce “boiled” linseed oil with lead and heat acting to cause the oil to cure than raw linseed oil (9).

## **1.2 Water Melon (*Citrullus lanatus*)**

Watermelon (*Citrullus lanatus*) is a flowering plants species of the Cucurbitaceae family. It is associated with numerous medicinal properties. Among important abilities of *Citrullus lanatus* is to prevent cancer. *Citrullus lanatus* a fruit crop, is a herbaceous creeping plant belonging to the family Cucurbitaceae. It is mainly propagated by seeds and thrives best in warm areas. It is a tropical plant and requires a lot of sunshine and high temperature of over 25°C for optimum growth. Watermelon thrives best in a drained fertile soil of fairly acidic nature. It can be grown along the coastal areas of Ghana, the forest zone and especially along river beds in the Northern Savannah areas (10).

Watermelons seed are known to be highly nutritional; they are rich source of protein, vitamin B, mineral such as (magnesium, potassium, phosphorus, sodium, iron, zinc, manganese and copper) are fat among other as well as photochemical. (10)

## **1.3 CEREBRUM**

The cerebrum is the part of the prosencephalon (forebrain) of the brain that contains the cerebral cortex as well as such subcortical structure as the hippocampus, amygdala, basal ganglia, olfactory bulb, and corpus callosum (11). In humans, the cerebrum is the superior-most (topmost) region of the central

nervous system (CNS). However, in nearly all vertebrates, the cerebrum is the anterior-most region of the CNS as most animals rarely assume an upright anatomical position (12).

In mammals, cerebrum has been used synonymously with the term “telencephalon” or “end brain”; however, in other vertebrates, the term telencephalon is used to refer to the embryonic structure from which the mature cerebrum developed (13).

The surface of the cerebral cortex is highly convoluted in large mammals, with the folds and grooves allowing a much greater surface area in a confined space as in the skull. In human, this highly folded structure with gyri and sulci is particularly pronounced, and allowing some 15-33 billion neurons in the cerebral cortex, each connected by a synapse, to several thousand other neurons (14).

The cerebrum is involved in speech and language, spatial recognition, learning and memory, sensory processing and olfaction (15). In addition to the assistance of the cerebellum, the cerebrum controls all voluntary actions on the body. Notably, while the two cerebral hemispheres of humans appear structurally similar, they differ in many functions. For example, in most people, the dominant hemisphere for language is the left hemisphere, where most of the neural processing takes place for speech comprehension, the formation of thought into speech, and the generation of motor output for language communication. In most people, the non-dominant hemisphere is adopted for spatial reasoning and musical ability (16). Damage to specific areas can cause such conditions as the inability to recall faces or have fluid and rapid speech but lacking meaning, with the words tossed together (17).

## **2.0 MATERIALS AND METHODS**

### **2.1 Ethical concerns in animal study**

All animal experiments and protocols adhered to the guidelines and regulations set forth by the National Research Council in regards to laboratory animal care and utilization (2011). Following the conclusion of experiments, animal carcasses were buried, no less than two feet beneath the natural surface, and covered with lime, disinfectant, and soil.

## **2.2 METHODOLOGY**

### **2.2.1 SUBSTANCE PREPARATION**

- Lead acetate of powdery form was procured from central drug house(P)LTD New Delhi (INDIA) Batch No: 330417

### **2.2.2 RAT MANAGEMENT**

Twenty male and female Wistar rats of second filial generation weighing ( $150\pm 50$ g) were obtained and brought to the animal holding unit of the department of Anatomy Ladoke Akintola University of Technology, Ogbomoso for this study. They were kept in clean cages in a well-ventilated environment. The rats were allowed free access to water and standard mouse chow for an acclimatization period of three weeks in accordance with the guidelines of the ethics of internal animal care and life committee.

### **2.2.3 PLANT EXTRACTION:**

Fresh *Citrullus Lanatus* was purchased from Odo-oba market, Ogbomoso, Nigeria. The seeds were harvested, air-dried and milled with grinding machine into powdery form after which it was taken to food science laboratory for processing into an aqueous extracted form.

### **2.2.4 EXPERIMENTAL DESIGN**

Twenty rats were randomly assigned into four groups {n=5} as control group {C} administered distilled water only {2 ml/kg} and treatment Groups T1 administered {7.5mg/kg} of Lead Acetate solution, T2 administered *Citrullus lanatus* only {200mg/kg} and T3 simultaneously administered {7.5mg/kg} of lead acetate solution and {200mg/kg} of *Citrullus lanatus*. All the animals were exposed for a period of 14 days. Throughout the exposure duration, daily weights of the rats were taken and documented.

### **2.2.5 TISSUE EVISCERATION AND PRESERVATION:**

At the end of exposure, all the animals were sacrificed by cervical dislocation after which the skulls were carefully opened and the brain specimens were harvested, weighed and documented. Pool of the harvested brain specimens were fixed in 10% formal calcium fixative for paraffin wax embedding protocols and the rest were frozen for bioassay.

## **2.2.6 MORPHOLOGICAL STUDIES**

The paraffin wax embedded tissues were serially sectioned at 5 $\mu$ m and processed for Haematoxylin and Eosin staining reactions as well as Cresyl violet staining for Neurons.

## **2.2.7 BIOCHEMICAL ASSAY**

The cerebral brains were removed, measured and cut to a constant 0.25mg, then homogenized and mixed with 2.5mls of the combination of phosphate buffered saline maintained at a pH of 7.4 and processed for biomarkers of oxidative stress.

### **2.2.7.1 BIOCHEMICAL PARAMETERS**

- **Determination of Malondialdehyde concentration**

Normal saline (0.5ml) was pipette into test tube containing 0.5ml of the serum sample. About 2 ml of thiobarbituric acid (TBA) mixture was added, allowed to boil for 1 hour, cooled to room temperature and centrifuged at 4000rpm for 5min. the clear supernatant was read at 535nm.

- **Determination of Catalase activity**

Distilled water (2.5ml) was pipetted into test tube containing 0.5ml H<sub>2</sub>O<sub>2</sub> and about 40ul sample was added and mixed thoroughly. Rate of decomposition of hydrogen peroxide was read at 240nm at 30 sec interval for 5 mins.

- **Determination of superoxide dismutase (SOD) activity**

Sample extract (20 ml) and 2.5 ml of 0.05 M carbonate buffer (pH 10.2) were mixed together and equilibrated in the spectrophotometer. In addition, 0.3 ml of 0.3mM freshly prepared adrenaline was added and mixed by inversion. The increase in absorbance at 480 nm was monitored spectrophotometrically at 30 seconds intervals for 3 mins.

## **2.8 Photomicrography**

Image acquisition and analysis: A bright light microscope (10 - 40x magnification objective) was used. Digital camera - OMAX Top view 3.7 attached to P.C - HP was used. Java Application Software (image J Software) was used.

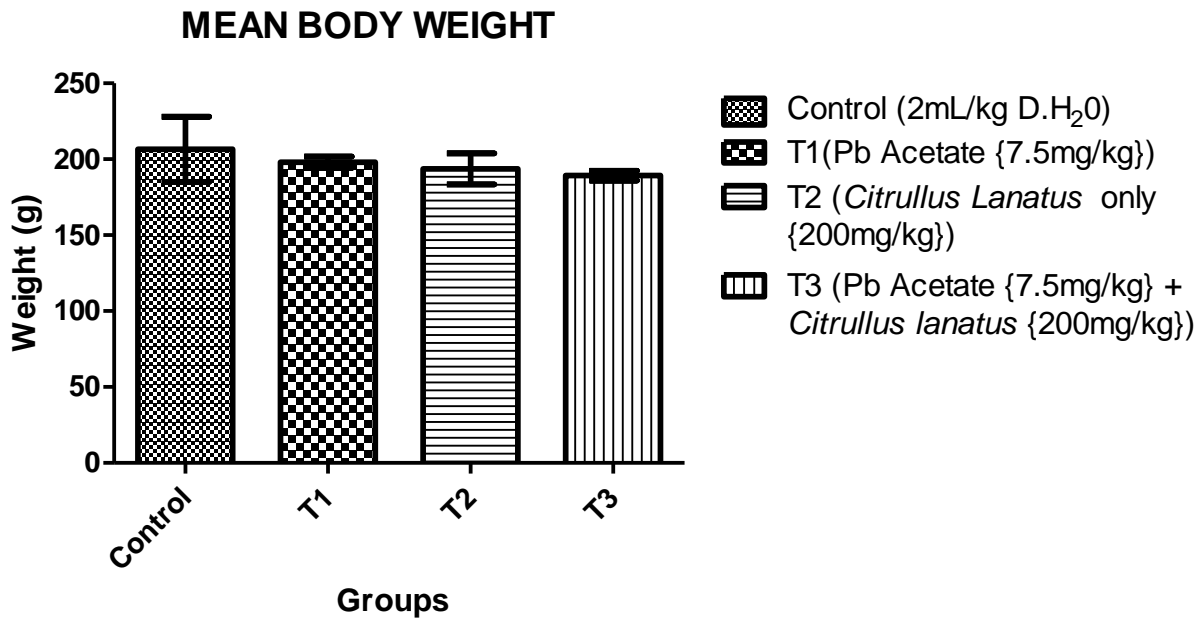
## **2.9 STATISTICAL ANALYSIS**

The data obtained from this study were analyzed using ANOVA and comparison were made between control and experimental groups using Tukey's multiple comparison test. All results were expressed as mean  $\pm$ SEM.  $P < 0.05$  was taken as the statistical significance level.

## **3.0 RESULTS**

### **3.1 EFFECT OF LEAD ACETATE AND *CITRULLUS LANATUS* ON MEAN BODY WEIGHT**

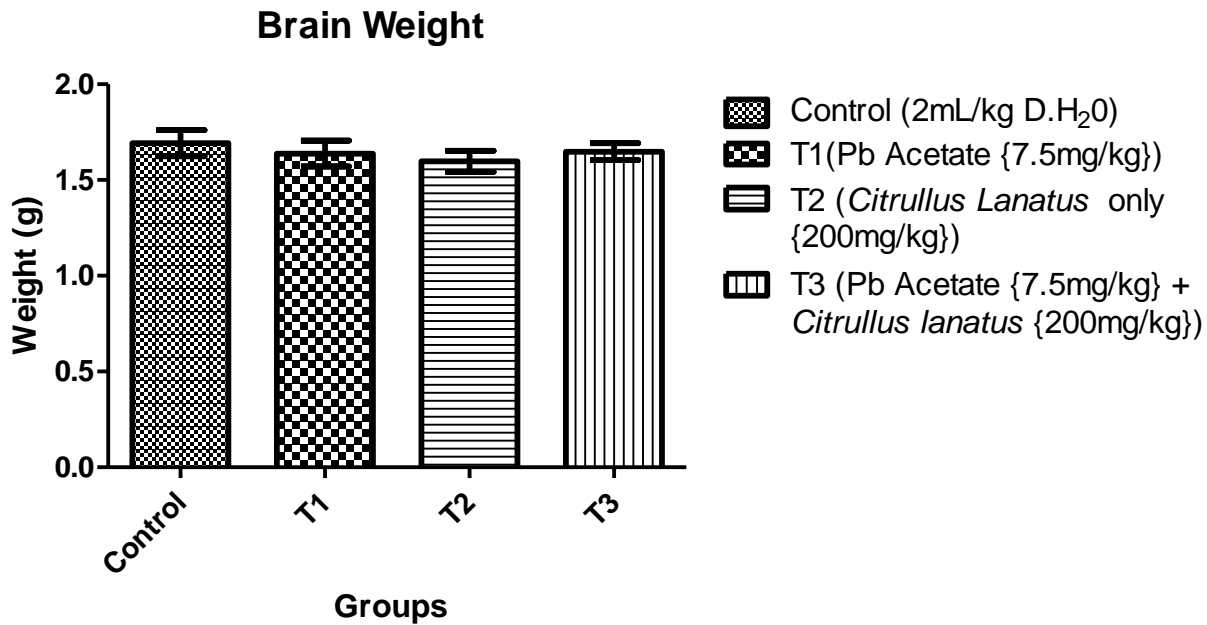
Assessment of the mean body weights (Fig1) of rats across groups following treatments with lead acetate and *Citrullus lanatus* showed no statistical difference ( $p = 0.7257$ ,  $F = 0.4431$ ) with the lead acetate only treated group T1 having statistically decreased value ( $198 \pm 3.80$ )g, *Citrullus lanatus* only T2 ( $193.6 \pm 10.19$ )g and their co-treatment group T3 ( $193.2 \pm 3.20$ ) were compared to the control ( $206.50 \pm 21.50$ )g. Also, no observable significant difference when T1 ( $198 \pm 3.80$ ) was compared to the T2 ( $193.6 \pm 10.19$ )g group, and also when the T2 ( $193.6 \pm 10.19$ )g was compared to T3 ( $193.2 \pm 3.20$ )g.



**Fig 1:** Bar chart represents the effect of Lead acetate, *Citrullus lanatus* and their co-treatments on the body weight of rats across the groups. Values are expressed as mean  $\pm$  SEM (n= 5), Statistical significance ( $p < 0.05$ ).

### 3.2 EFFECT OF LEAD ACETATE AND *CITRULLUS LANATUS* ON BRAIN WEIGHT

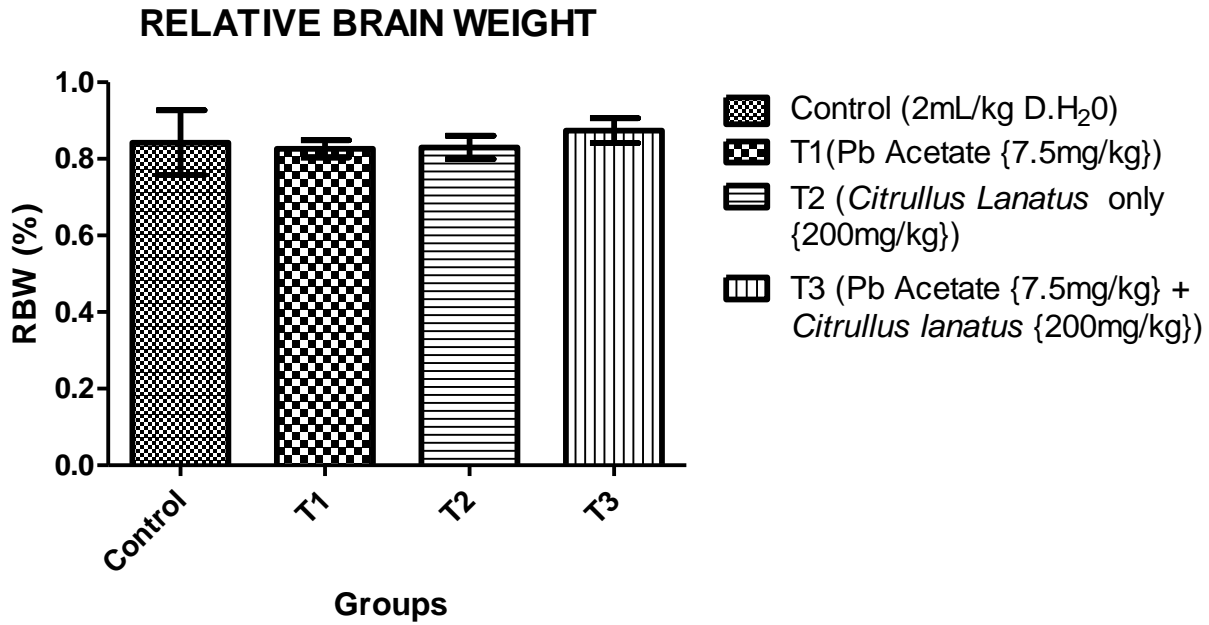
The effect of the administration of lead acetate and *Citrullus lanatus* on the brain weight is presented (Fig 2). In this study, lead acetate only treatment group T1 ( $1.64 \pm 0.07$ )g, *Citrullus lanatus* only treatment group T2 ( $1.60 \pm 0.05$ )g and their co-treatment group T3 ( $1.65 \pm 0.04$ )g did not result in any significant changes ( $p = 0.7488$ ,  $F = 0.4091$ ) in the brain weight as compared to the control ( $1.69 \pm 0.07$ )g.



**Fig 2:** Bar chart represents the effect of Lead acetate, *Citrullus lanatus* and their co-treatments on the brain weights of rats across the groups. Values are expressed as mean  $\pm$  SEM (n= 5). Statistical significance ( $p < 0.05$ ).

### 3.3 EFFECT OF LEAD ACETATE AND *CITRULLUS LANATUS* ON THE RELATIVE BRAIN WEIGHT

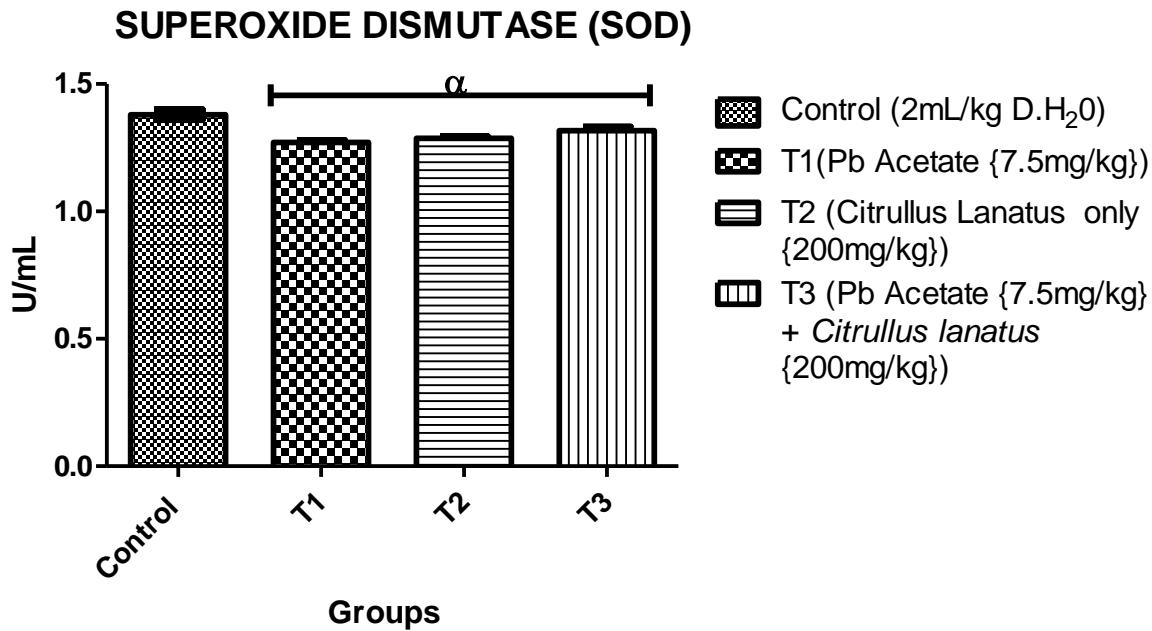
The effect of the administration of lead acetate and *Citrullus lanatus* on the relative brain weight is shown in (Fig). Result obtained on the relative brain weight showed that lead acetate only treatment (T1) ( $0.83 \pm 0.02$ ), *Citrullus lanatus* only (T2) ( $0.83 \pm 0.03$ )g and their co-treatments (T3) ( $0.87 \pm 0.03$ )g did not cause any significant ( $p = 0.8521$ ,  $F = 0.2614$ ) changes in the relative brain weight as compared to the control ( $0.84 \pm 0.08$ )g.



**Fig 3:** Bar chart represents the effect of Lead acetate, *Citrullus lanatus* and their co-treatments on the brain weights of rats across the groups. Values are expressed as mean  $\pm$  SEM (n= 5). Statistical significance is indicated at ( $p < 0.05$ ).

### 3.4 EFFECT OF LEAD ACETATE AND *CITRULLUS LANATUS* ON SOD ACTIVITY

As obtained in this study on the SOD activity (Fig 4) following administration of lead acetate and *Citrullus lanatus* extract treatments. There was statistically significant decrease ( $p = 0.021$ ,  $F=12.70$ ) in superoxide dismutase activity in the lead acetate only treated group (T1) ( $1.27 \pm 0.01$ )IU/L, *Citrullus lanatus* only treated group (T2) ( $1.29 \pm 0.01$ )IU/L, and the co-treatment group (T3) ( $1.32 \pm 0.02$ )IU/L as compared to the control ( $1.38 \pm 0.02$ )IU/L. However, there was no significantly different SOD activity when lead acetate only treated group (T1) was compared with *Citrullus lanatus* only treated group (T2) ( $1.29 \pm 0.01$ )IU/L and when *Citrullus lanatus* only treated group (T2) ( $1.29 \pm 0.01$ )IU/L was compared with Co-treatment group (T3) ( $1.32 \pm 0.02$ )IU/L.

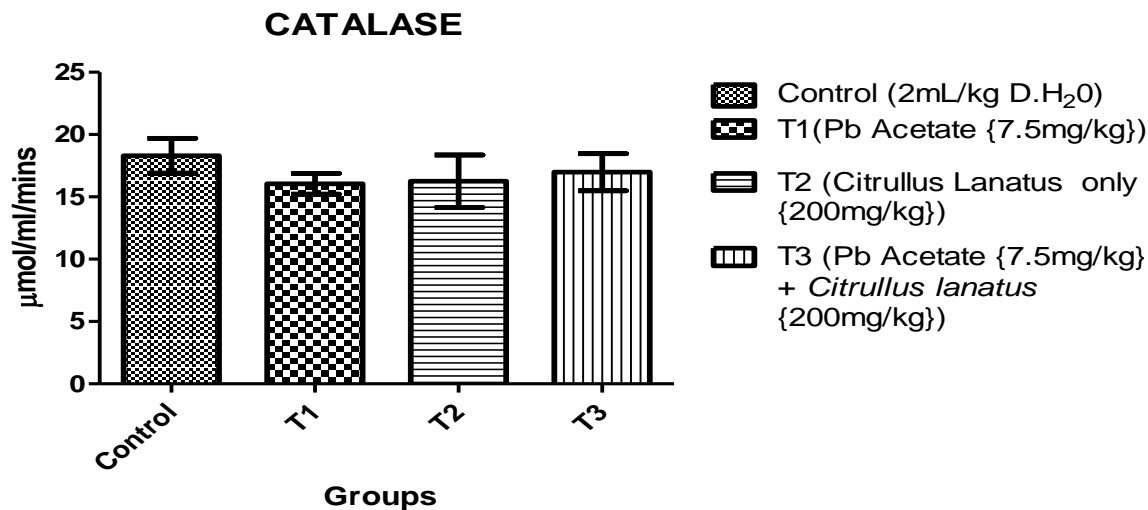


**Fig 4:** Bar chart represents the effect of Lead acetate, *Citrullus lanatus* and their co-treatments on SOD activity in the brain tissues of rats across the groups. Values are expressed as mean  $\pm$  SEM (n= 5). Statistical significance ( $p < 0.05$ ).

### 3.5 EFFECT OF LEAD ACETATE AND *CITRULLUS LANATUS* ON CATALASE ACTIVITY

The result obtained on this study on the CAT activity (Fig) following administration of lead acetate and *Citrullus lanatus* extract treatments showed no statistical significant difference ( $p = 0.7283$ ,  $F=0.4438$ ) when the lead acetate only treated group (T1) ( $16.05 \pm 0.84$ )IU/L, *Citrullus lanatus* only treated group (T2) ( $16.27 \pm 2.10$ )IU/L, and the co-treatment group (T3) ( $16.98 \pm 1.49$ )IU/L were compared to the control group ( $18.30 \pm 1.40$ )IU/L.

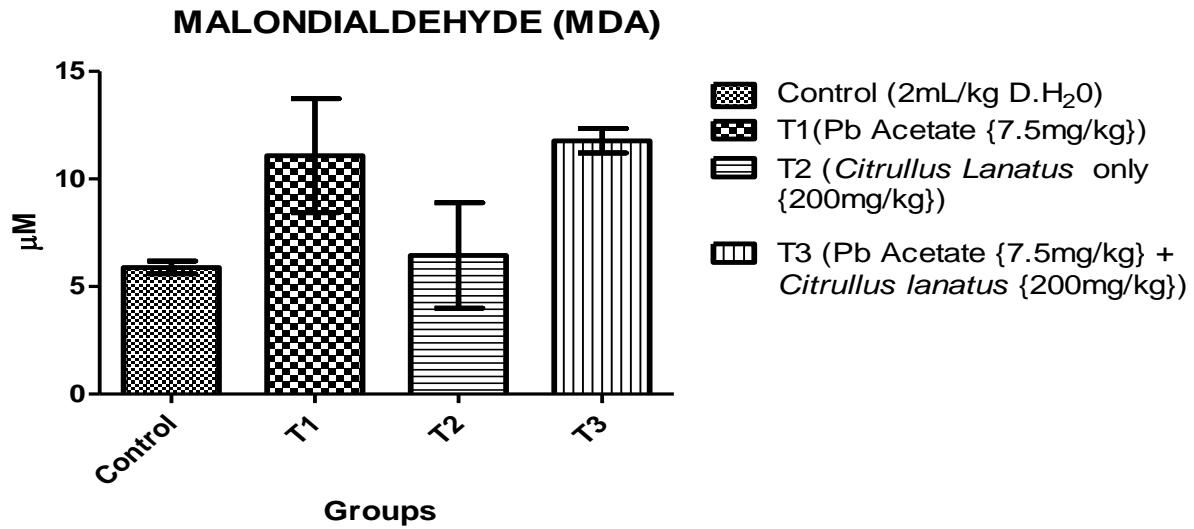
Likewise no statistically significant difference was observed when lead acetate only treated group (T1) ( $16.05 \pm 0.84$ )IU/L was compared to *Citrullus lanatus* only treated group (T2) ( $16.27 \pm 2.10$ )IU/L and the Co-treatment group (T3) ( $16.98 \pm 1.49$ )IU/L and when *Citrullus lanatus* only treated group (T2) ( $16.27 \pm 2.10$ )IU/L was compared to the Co-treatment group (T3) ( $16.98 \pm 1.49$ )IU/L.



**Fig 5:** Bar chart represents the effect of Lead acetate, *Citrullus lanatus* and their co-treatments on catalase activity in the brain tissues of rats across the groups. Values are expressed as mean  $\pm$  SEM. Statistical significance ( $p < 0.05$ ).

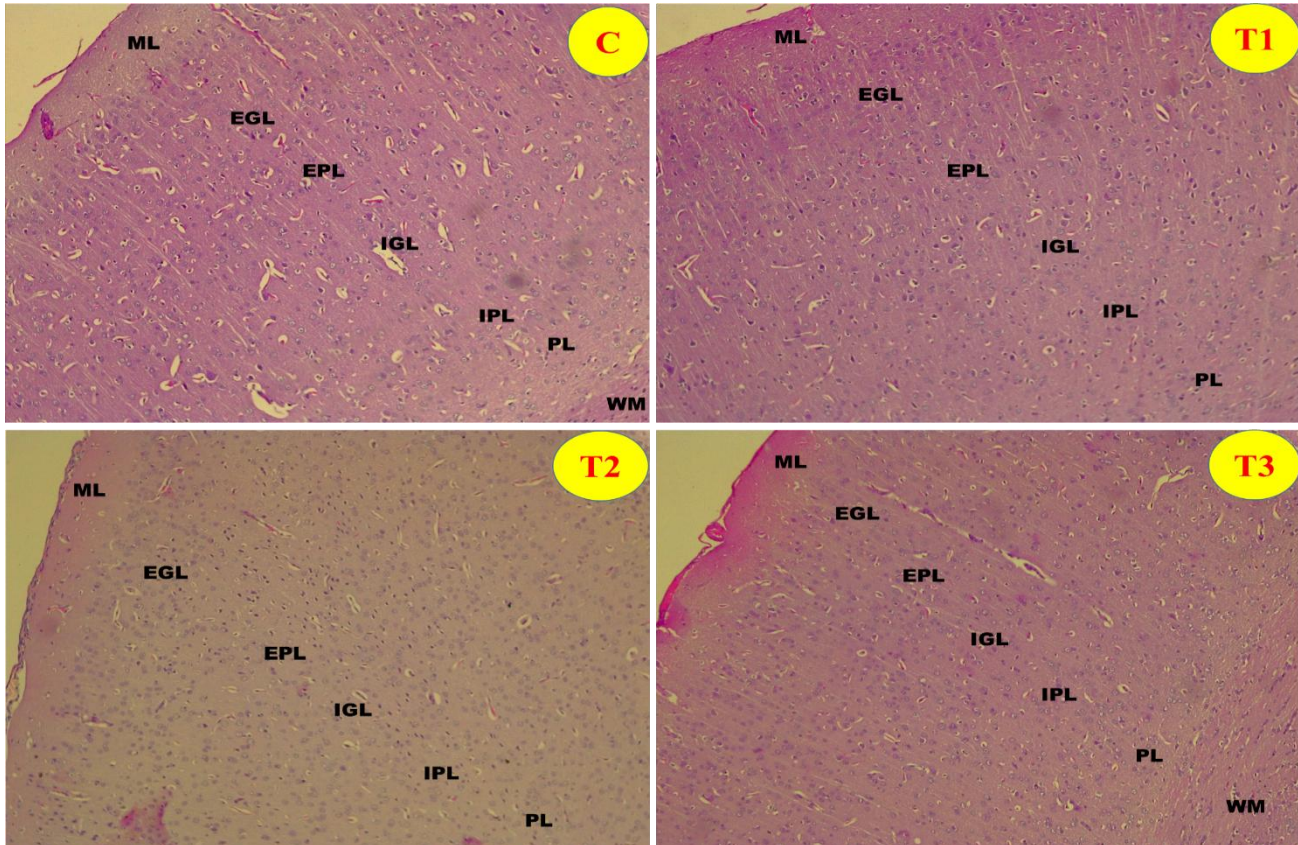
### 3.6 EFFECT OF LEAD ACETATE AND *CITRULLUS LANATUS* ON MDA CONCENTRATION

MDA concentration (Fig 6) in the brain tissues was evaluated across the groups following administration of lead acetate and *Citrullus lanatus* extract treatments. In the study, there was no significant difference ( $p = 0.1089$ ,  $F=2.796$ ) in MDA concentration in the brain tissues with the lead acetate only treated group (T1) ( $11.09 \pm 2.65$ )IU/L, *Citrullus lanatus* only treated group (T2) ( $6.44 \pm 2.44$ )IU/L, and the Co-treatment group (T3) ( $11.78 \pm 0.57$ )IU/L were compared to the control group ( $5.88 \pm 0.29$ )IU/L. There was also no statistically significant difference when lead acetate only treated group (T1) ( $11.09 \pm 2.65$ )IU/L was compared to *Citrullus lanatus* only treated group (T2) ( $6.44 \pm 2.44$ )IU/L and the co-treatment group (T3) ( $11.78 \pm 0.57$ ) and when *Citrullus lanatus* only treated group (T2) ( $6.44 \pm 2.44$ )IU/L was compared to the co-treatment group (T3) ( $11.78 \pm 0.57$ )IU/L.



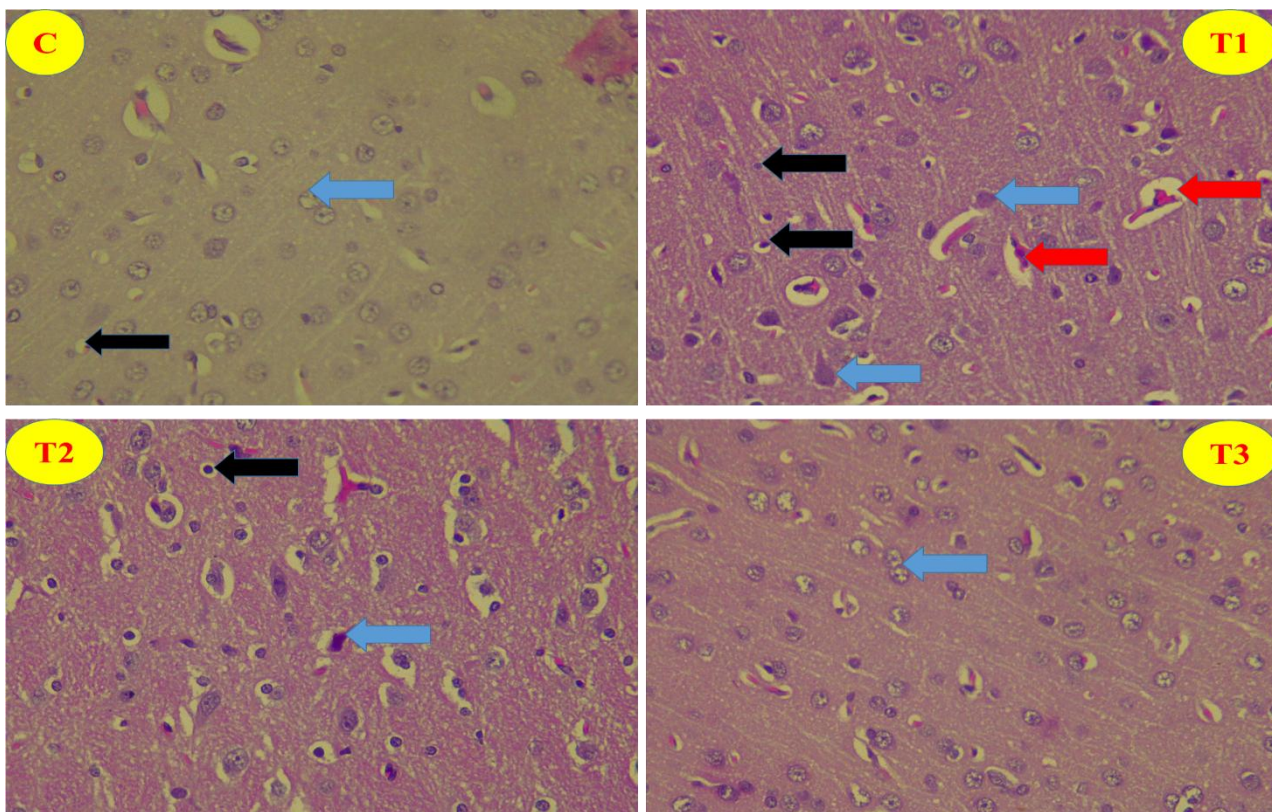
**Fig6:** Bar chart represents the effect of Lead acetate, *Citrullus lanatus* and their co-treatments on MDA concentration in the brain tissues of rats across the groups. Values are expressed as mean  $\pm$  SEM (n= 5). Statistical significance ( $p < 0.05$ ).

### HISTOLOGY OF THE CEREBRUM



**PLATE 1:** Representative light photomicrographs showing the cortical layers stained cortex of the control, T1 (lead acetate only), T2 (*Citrullus lanatus* only) and co-treatment groups T3 (lead acetate + *Citrullus lanatus*) groups. **Stain:** H and E; **Magnification:** x100.

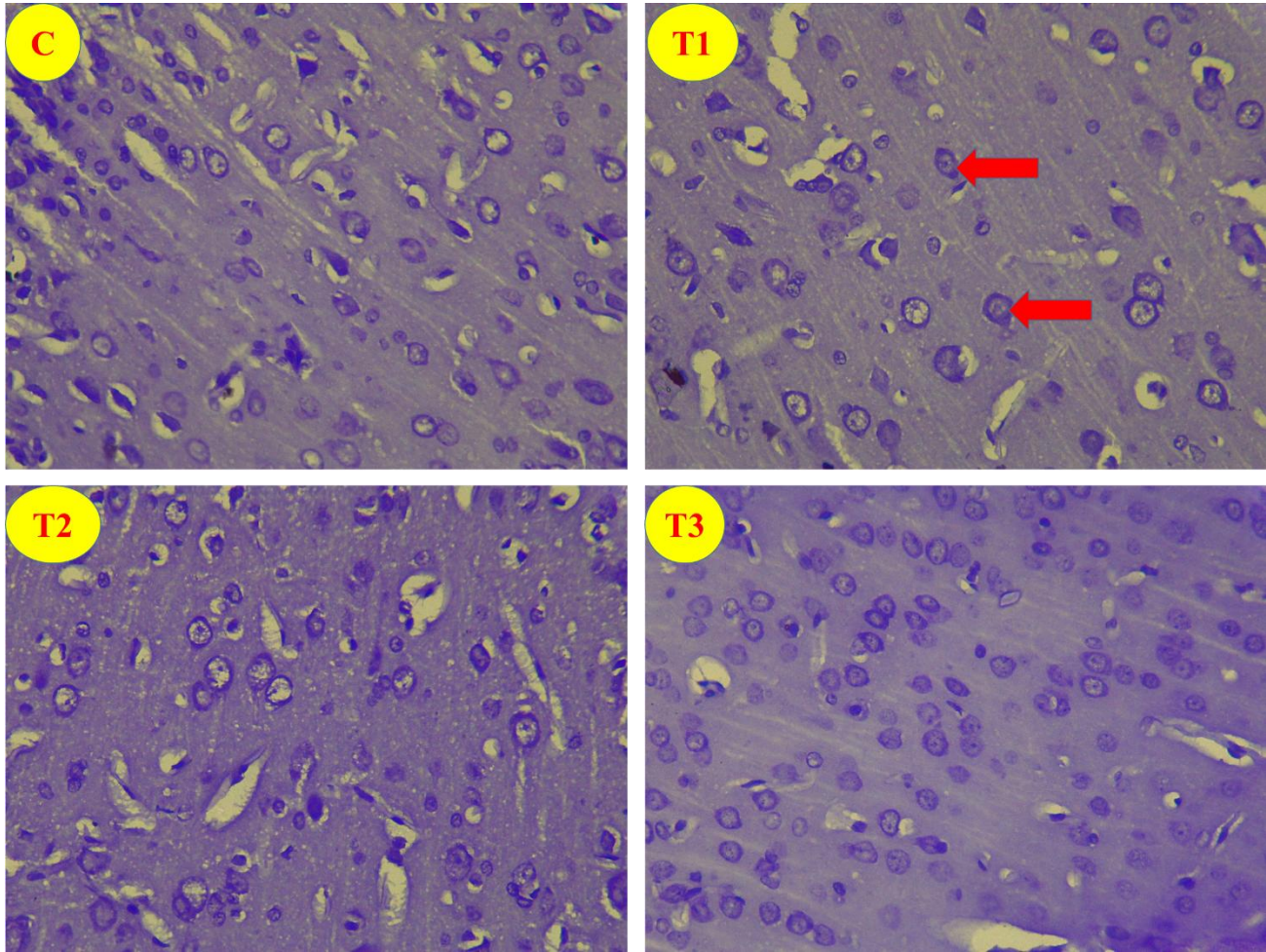
**Abbreviation:** ML-Molecular layer; EGL-External granular layer; EPL- External pyramidal layer; IGL-Internal granular layer; IPL- Internal pyramidal layer; PL (Polymorphic layer or Multiform); WM- white matter (Subcortical)



**PLATE 2:** Representative light photomicrographs showing frontal cortex of the control, T1 (lead acetate only), T2 (*Citrullus lanatus* only) and co-treatment groups T3 (lead acetate + *Citrullus lanatus*) groups. The control group showed normal histoarchitectural appearance of the frontal cortex as evident by intact Pyramidal neurons (green arrow), oligodendrocytes (black) are also remarkable. Observed in T1 are neuronal vacuolations and pyknotic neurons (red arrow), few oligodendrocytes are also remarkable. T2

and T3 showed frontal cortical sections with the normal neuronal morphology. **Stain:** H and E;

**Magnification:** x400



**PLATE 3:** Representative light photomicrographs showing cortex of the control, T1 (lead acetate only), T2 (*Citrullus lanatus* only) and co-treatment groups T3 (lead acetate + *Citrullus lanatus*) groups. The control group showed normal histoarchitectural appearance of the frontal cortex as evident by intact Pyramidal neurons, while in T1, neuronal cytoplasm appears intensely stained and also there is loss of cytoplasmic Nissl substances. T2 and T3 showed frontal cortical sections with the normal neuronal morphology. **Stain:** Cresyl violet; **Magnification:** x400

#### 4.0 DISCUSSION

This study investigated the potential effect of subacute administration of aqueous extract of water melon(*citrulluslanatus*) seed on lead acetate induced toxicity in the cerebrum which is one of the system vulnerable to the adverse effect of administration of lead acetate is the central nervous system . Lead is a heavy metal that has also been regarded as a neurotoxicant known to accumulate in soft tissues (18). Lead acetate possess the ability to penetrate the blood brain barrier thereby exerting its deleterious effects. Different routes of exposure to lead toxicity has been documented, which may include food, water, air, or occupational exposure (19).

The result obtained from this study (fig 1) revealed significant decrease in the body weight of T1 administered lead acetate only when compared to the control. This is in tandem with the report of (20) also reported decrease in body weight following lead acetate administration.

The reduction in the body weight could be attributed to increased metabolism or a probable suppression in the appetite as a consequence of lead treatment.

The brain weight (Fig 2) of the rats across the groups were not significantly different from the control group. Although, there was neurodegenerative change in the brain of group T1 which could lead to decrease in the cortical volume or thickness and as a result causing reduction or decline in the brain weight. The possible explanation why there was no effect lead on the brain weight in this group and other experimental groups relative to the control could based on the frequency, time and route of exposure. Increasing the frequency, time all the exposure could impact negatively on the brain weight. However, this subject to further studies

The relatively brain weight is the ratio of brain to the body weight express in percentage. The relatively brain weight (Fig 3), show no significance different across all experimental groups when compare to the control changes in the brain weight relative to the body weight is a possible event as observed in the reduction of the relative weight of T1, albeit non-significant to control. Lead is highly toxicity metal that

persist in the environment and has been known to disrupt neurological and normal biological function (21). Chronic poisoning by lead is one of the major public concerns in developing countries (22). Several mechanisms have been proposed by which lead induced neurotoxicity which includes oxidative stress, inflammation, disruption in the neurotransmitter systems e.t.c. Lead acetate exposure results in the generation of reactive oxygen species (ROS) such as superoxide radical, hydrogen peroxide and lipid peroxide there increasing oxidative damage to cellular materials (23). The neurotoxic effect of lead acetate could also be interference with the cholinergic system and also alteration in the intercellular communication.

The histological assessment of both haematoxylin and cresyl violet stained cerebral cortical section of T1 group shows distortion in the histoarchitectural organization of the cerebral cortex evident by distortion in the pyramidal neuronal cell, with wide perivascular space, broken axon with scantily distributed glial cells, in Group T2 concomitantly administered lead acetate and Citrullus lanatus extract showed a preserved cerebral cortex histoarchitecture showing the neuroprotective ability of aqueous extract of Citrullus lanatus which could be due to the phytochemical constituent present in Citrullus lanatus which has been previously documented by (24).

Our study shows that administration of lead significantly reduced the superoxide dismutase (SOD) and catalase (CAT) level while there was a significant increased malondialdehyde (MDA) Antioxidants which exerts a protective activity on neurons against a variety of experimental neurodegenerative conditions, (25). Citrullus lanatus has antioxidants that have been used to reverse lead mediated toxicity by ameliorating oxidative stress status (26).

## **5.0 CONCLUSION**

In conclusion, *citrulluslanatus* extract shows a promising mitigating and ameliorative property against lead induced neurotoxicity, offering a potential therapeutic intervention.

## **6.0 RECOMMENDATION**

Further research should explore the underlying molecular and immunological application of *citrulluslanatus* in mitigating and addressing neurotoxicity caused by heavy metals. There is a need to further understand the long term effect and optimum dosage and potential side effects

## **CONSENT**

Not applicable

## **ETHICAL APPROVAL**

All animal experiments and protocols adhered to the guidelines and regulations set forth by the National Research Council in regards to laboratory animal care and utilization(2011)

## **ACKNOWLEDGEMENT**

The authors will like to acknowledge Ladoke Akintola University of Technology, Ogbomoso, Nigeria and Olabisi Onabanjo University, Sagamu campus, Nigeria for providing Resources and a conducive Environment for conducting this research.

## **COMPETING INTEREST**

Authors have declared that no competing interests exist.

## REFERENCES

1. Flora Gagan, Deepesh Gupta and Archana Tiwari(2012),. Toxicity of lead: A review with updates. *InterdiscipToxicol*. 5(2):47-58
2. Vaziri D. Nosratola(2008). Mechanism of lead –induced hypertension and cardiovascular disease. *American Journal of physiology-Heart and Circulatory physiology*. 295(2)H454-H465
3. NgadinoRustanti Setiawan K and Sudjarwo SA(2015), protective effect of ethanol extract of mangostana L pericarp against lead acetate induced hepatotoxicity in mice. *Int. J Curr Res* 7(2), 12518-12522.
4. Dorostghoal M, Seyyendnejad SM, Jabari A(2014). Protective effects of Fumaria perviflora L on lead-induced testicular toxicity in male rats.*Andrologia*46(4), 437-446
5. Muhammad S, Ayaz A.K, Zahid H, Muhammad Z.A, Sohaib R, Farooq R and Razaqat I, (2011). Effect of lead acetate administered orally at different dosage levels in broiler chicks. *African journal of Environmental Science and Technology*. 5(12), 1017-1026
6. Ramki K, Rajapriya A, Sakthivel P, Murugadoss G, Thangamuthan R and Rajesh M.K(2020). Rapid Degradation of Organic dyes under sunlight using tin-doped ZnS nanoparticles. *Journal of Materials Science*: 31, 8750-8760
7. Linda F Bisson and Jonathan E. K. (2010). Genetics of yeast impacting wine quality. *Annual Review of Food Science and Technology*. 1,139-162
8. Mokwelu Onyinye V. (2019) Bioassay guided fractionation of Angiotensin converting enzyme inhibitor Compound from Hypericum Perforatum. *University of the Western Cape*
9. Youn Y.S, Bo G, Yong W, and Martin JT (2015). Flaxseed oil processing and selected products. *Trends in Food Science and Technology* 43(2), 162-177
10. Betty Tabiri, Jacob K. A, Faustina D.W, Elsa I.O (2016). Watermelon Seeds as Food: Nutrient composition, Phytochemicals and antioxidant activity. *International Journal of Nutrition and Food Sciences*
11. Kinaan Javed, Vamsi Reddy, and Forshing Lui(2019), Neuroanatomy Cerebral cortex
12. Marsel Mesulam M. (2023). Temporal regions of the human brain. *Brain* 146(1), 20-41
13. Jean M H, and Gord F(2008). The genetics of early telencephalon patterning: some assembly required. *Nature Reviews Neuroscience* 9(9), 678-685
14. Jiawei Zhang (2019), Basic Neural units of the Brain: Neurons, Synapses and action potential. *arxiv preprint arxiv*: 1906.01703

15. Jonas K.O and Jay A.G (2015), The Muted Sense: Neurocognitive limitations of Olfactory language. *Trends in Cognitive Sciences*. 19(6), 314-321
16. Annukka K.L. (2011). Lateral thinkers are not so laterally minded: Hemispheric asymmetry, interaction and creativity. *Asymmetries of Body, Brain and Cognition* 16(4), 479-498
17. Wilder Penfield and Lamar Roberts (2014), Speech and Brain mechanisms. *Princeton University press*
18. Roberts, J.R., (1999) Metal toxicity in children in Training Manual on Pediatric Environmental Health: Putting it into practice.
19. Fleming S., (2006). Liver disease.<http://www.canin-epilepsy-guardianangle.com/diagnostic-testing>
20. Abdullateef O.Y, Buraimoh A.A, Agbon A.N, Raji K.B, Akpulu P.S(2017). Preliminary histological studies on the effect of aqueous fruits extract of Phoenix dactylifera L.(date palm)on lead acetate induced cerebellar damages in wistar rat. *African Journal of Cellular Pathology* 8(1), 1-8
21. Alessia C, Graziantonio L, Maria S. S, Giuseppe G. (2016), lead toxicity, antioxidant defense and environment. *Reviews of environmental contamination and toxicology*, 45-67
22. Flora, S., Suashil,k., (2012), Toxicology, effect of combined exposure to lead and ethanol on some biochemical indices in the rat. *Biochem*
23. El-Nekeety A.A, El-Kady A.A, Mahmoud S.S, Hassan N.S, Mosaad A.A.(2009). Protective effect of Aquilegia Vulgaris against lead acetate-induced oxidative stress in rats. *Food and Chemical toxicology*. 47(9), 2209-2215
24. Khuzhaev V.U and Aripova S.F (2000). Pseudocarpaine from Carica papaya. *Chemistry of Natural Compounds* 36, 418
25. Kuhad A. and Chopra K (2007) Curcumin attenuates diabetic encephalopathy in rats: behavioral and biochemical evidences. *European Journal of Pharmacology* 576(1-3), 34-42
26. Hsu Ping-Chi and Guo Y.L (2002). Antioxidant nutrients and lead toxicity. *Toxicology* 180(1), 33-44