

A CASE OF DOUBLE INFERIOR VENA CAVA : A CASE REPORT

ABSTRACT

The incidence of double inferior vena cava (IVC) ranges from 0.2% to 3%. Most of the cases of double IVC are diagnosed incidentally from imaging given it has a lack of symptoms and clinical findings. Embryogenesis of IVC is very complicated hence predisposing to diverse anomalies. These anomalies are usually of no clinical significance however may predispose to thromboembolism likely due to venous stasis. The abnormal vessels also can be misdiagnosed as masses which can cause massive haemorrhage if mismanaged. In this report, we present a 14 years old boy, who was incidentally diagnosed to have double IVC from computed tomography (CT) done for other reasons.

Key word: inferior vena cava, Duplications, Anomalies, CT scan,

INTRODUCTION

Abnormalities of the inferior vena cava are extremely rare. Most of the diagnoses were made from Computed Tomography (CT) scans that were performed for other reasons because the majority of the cases were asymptomatic. The complexity in the development of IVC leads to several anomalies, including left-sided IVC, duplicated IVC, and absent IVC.

“The first case of inferior vena cava duplication (IVCD) was described in 1916 in a male subject dissected during an autopsy by Lucas in London” [1]. “As reported in the literature, the incidence of IVCD is 1.5% (range 0.2%–3%), with intraoperative findings between 0.2% and 0.6%” [2–4]. In this report, we discuss the embryology of the double IVC and its clinical significance.

CASE REPORT

A 14-year-old boy with no significant past medical history had a road traffic accident. Upon arrival at the casualty department, he had a full Glasgow coma scale (GCS), however, his vital signs showed episodes of hypotensive with tachycardia. Generally, he looked pink and he had tenderness over the abdomen. Focus assessment sonography for trauma (FAST) showed positive intrabdominal free fluid indicating intraabdominal injury. Computed tomography of the abdomen revealed that he sustained AAST classification grade 1 splenic injury, however, another pathology was incidentally noticed in the CT scan in which he has double Inferior vena cava.

The CT showed double IVC that runs upward, accompanying the abdominal aorta on each side as shown in Figure 1. Both IVCs were formed from the respective common iliac veins in which the left-sided IVC terminated into left renal veins as shown in Figure 2. The left renal

vein crosses the aorta posteriorly to the right side, in which it joins with the right IVC. The right IVC, once receiving the left and right renal veins, ran upwards as a single vein continuing superiorly as the azygos vein within the retrocrural space subsequently drained into the superior vena cava.

Otherwise, he is asymptomatic for the double IVC, and the splenic injury was successfully treated conservatively.

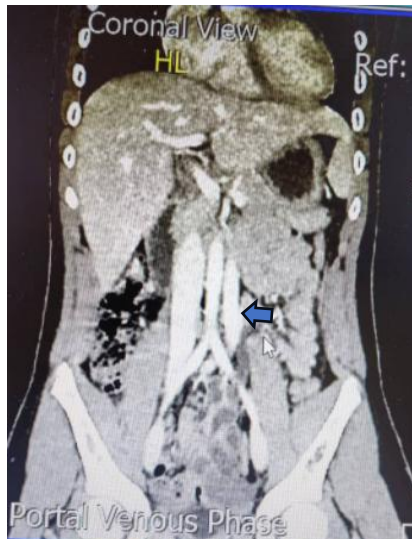

Figure 1: Double IVC ran upwards bilaterally to the abdominal aorta. Abnormally located IVC pointed with blue arrow run on the left side of the aorta.

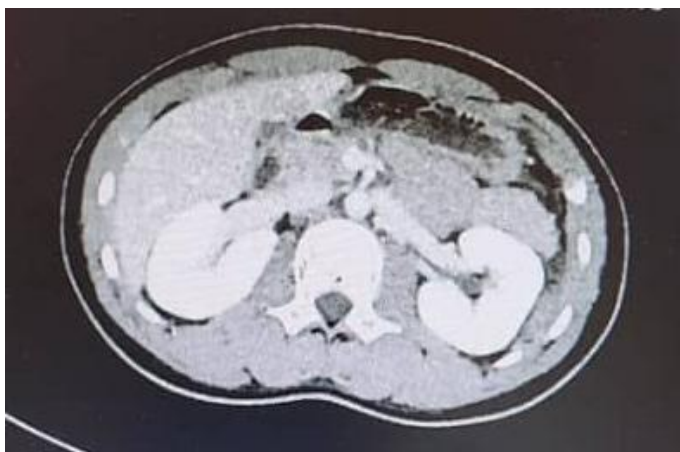

Figure 2: The left IVC terminated into the left renal vein

DISCUSSION

“IVC is composed of four segments, namely hepatic, renal, suprarenal and infrarenal segments. Development of IVC begins at 6th week of gestation from 3 primitive veins which are posterior cardinal, subcardinal, and supracardinal veins. During embryogenesis, the 3 primitive veins undergo evolution and regression. The posterior cardinal vein persists in the pelvis as the common iliac veins, the right supracardinal vein forms the infrarenal IVC, and

the right subcardinal vein forms into the suprarenal segment by the formation of the subcardinal-hepatic anastomosis while the left subcardinal vein and the left supracardinal vein regress completely” [2, 4, 6]. “Anastomosis between subcardinal and supracardinal veins forms the renal segment while the hepatic segment derives from the right vitelline vein” [6, 7]. Diversification at any point during the IVC development, may result in various anatomical anomalies. Major anomalies that commonly occur in IVC development are circumaortic left renal vein (8.7%), retro aortic left renal vein(2.1%), double IVC (0.2-3%), left IVC(0.2-0.5%) and absence of the hepatic segment of the IVC with azygos continuation of the IVC(0.6%)

As in our case, the anomaly detected is the double IVC up to the level of the left renal vein, which results from the persistence of the right and the left supracardinal veins. The left IVC merged with the left renal vein before it passed posterior to the aorta to drain into the right IVC.

This condition is usually asymptomatic, however, the abnormally located IVC on the left side can be misdiagnosed as abdominal mass or lymphadenopathy, especially in a patient who is investigated for intraabdominal neoplasm mainly renal tumor. Furthermore, a patient with double IVC is at risk of life-threatening hemorrhage resulting from IVC injury during a retroperitoneal procedure, hence identification of vascular anomalies is very crucial before any procedure. Identification of any vascular anomalies can be achieved by Contrast-enhanced CT or magnetic resonance imaging (MRI) [7].

The thromboembolism phenomenon is also highly associated with double IVC [8,9]. Alteration of the blood flow in the abnormal vessels seems to be the pathogenesis of the thromboembolic event. In the case of recurrent emboli from lower limb deep vein thrombosis in a patient with an IVC filter, it may suggest the presence of double IVC.

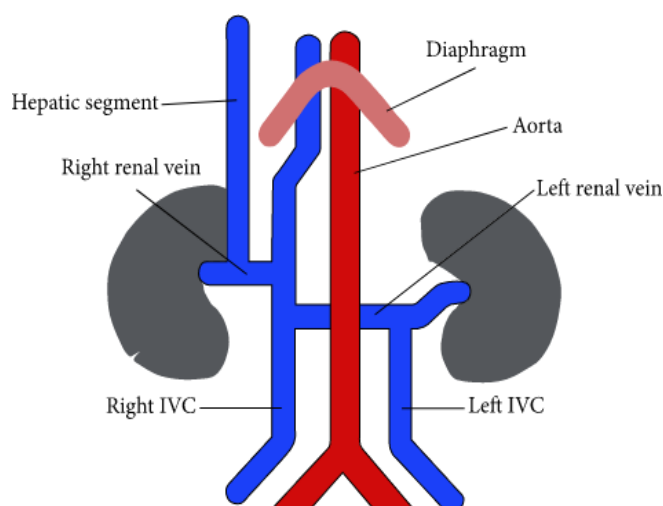


Figure 3: Schematic figure illustrating double IVC with a retro aortic left renal vein, azygos continuation

CONCLUSION

Abnormal development of fetal venous circulation may result in various IVC anatomical anomalies. Identification of any abnormal vessels is very important in any type of imaging, as

most of the cases are asymptomatic. Computed tomography is the imaging of choice in the diagnosis of abnormal vessels since it is non-invasive if compared to angiography. Awareness of the various anomalies is necessary for radiologists and surgeons to prevent misinterpretation of the aberrant vessels. The presence of double IVC can cause very severe complications if not detected, hence awareness of any vascular anomalies is very crucial.

Consent

As per international standards, parental written consent has been collected and preserved by the author(s).

Ethical Approval:

As per international standards or university standards written ethical approval has been collected and preserved by the author(s).

Conflict of interest: None

Acknowledgements: We would like to express our gratitude to the patient's parents **who gave** their permission for this case report.

REFERENCES

1. M. F. Lucas, "A case of double inferior vena cava," *Journal of Anatomy*, vol. 51, pp. 69–70, 1916. View at: [Google Scholar](#)
2. A. Banerjee, S. Maharana, I. A. Kumar, and P. Jhansi, "Duplication of the inferior vena cava-report of a rare congenital variation," *International Journal of Anatomical Variations*, vol. 5, pp. 141–143, 2012. View at: [Google Scholar](#)
3. K. Natsis, S. Apostolidis, G. Noussios, E. Papathanasiou, A. Kyriazidou, and V. Vyzas, "Duplication of the inferior vena cava: anatomy, embryology, and classification proposal," *Anatomical Science International*, vol. 85, no. 1, pp. 56–60, 2010. View at: [Publisher Site](#) | [Google Scholar](#)
4. H. Chen, S. Emura, S. Nagasaki, and K.-Y. Kubo, "Double inferior vena cava with interiliac vein: a case report and literature review," *Okajimas Folia Anatomica Japonica*, vol. 88, no. 4, pp. 147–151, 2012. View at: [Publisher Site](#) | [Google Scholar](#)

5. R. J. Babaian and D. E. Johnson, "Major venous anomalies complicating retroperitoneal surgery," *Southern Medical Journal*, vol. 72, no. 10, pp. 1254–1258, 1979. View at: [Publisher Site](#) | [Google Scholar](#)
6. R. Mathews, P. A. Smith, E. K. Fishman, and F. F. Marshall, "Anomalies of the inferior vena cava and renal veins: embryologic and surgical considerations," *Urology*, vol. 53, no. 5, pp. 873–880, 1999. View at: [Publisher Site](#) | [Google Scholar](#)
7. Cizginer S, Tatli S, Girshman J, et al. Thrombosed interrupted inferior vena cava and retro aortic left renal vein mimicking a retroperitoneal neoplasm. *Abdom Imaging*. 2007;32:403–406. [[PubMed](#)] [[Google Scholar](#)]
8. Sartori MT, Zampieri P, Andres AL, et al. Double vena cava filter insertion in congenital duplicated inferior vena cava: a case report and literature review. *Haematologica*. 2006;91:ECR30. [[PubMed](#)] [[Google Scholar](#)]
9. Kouroukis C, Leclerc JR. Pulmonary embolism with duplicated inferior vena cava. *Chest*. 1996;109:1111–1113. [[PubMed](#)] [[Google Scholar](#)]