

## **Evaluation of the effects of alpha-tocopherol, quercetin and their combination on ethanol-induced pancreatic and duodenal mucosal injuries: An experimental study**

### ***Abstract***

**Aim:** In this study, the effects of alpha-tocopherol (AT), quercetin (QT) or their combination on ethanol-induced pancreatic and duodenal mucosal damage was investigated in rats using morphological and biochemical evaluations.

**Study design:** Experimental study

**Place and duration of study:** University of Ibadan, Ibadan, Nigeria

**Methodology:** Ethanol-induced injuries were produced by oral administration of 40% ethanol (0.2 ml/day) for 40 consecutive days, while a control group of rats was served distilled water. Other groups received AT (2.5 mg/kg), QT (50 mg/kg) or their combination with 40% ethanol during the experimental period.

**Results:** Blood glucose levels was significantly ( $p < 0.05$ ) increased in ethanol-treated rats relative to controls. Ethanol administration caused shrinkage of insulin-secreting islets tissues in the pancreas, while lesions such as erosions, loss of villi and severe inflammatory cell infiltrations of the mucosa and sub-mucosa were observed in the duodenum. These changes were accompanied by significant elevation in the levels of hydrogen peroxide ( $H_2O_2$ ), malondialdehyde (MDA) and advanced oxidation protein products (AOPP) in the pancreas and duodenum, along with reduced activities of glutathione peroxidase (GPx) and glutathione S-transferase (GST). Treatment of rats with AT, QT, and especially their combination, yielded profound reversal of ethanol-induced effects indicated by restoration of blood glucose to control levels, preservation of pancreatic and duodenal morphology and the inhibition of ethanol-induced oxidative stress.

**Conclusion:** Overall, dietary supplementation with AT and/or QT could potentially counteract the adverse effects associated with chronic alcohol consumption.

**Keywords:** Alcohol, antioxidants, pancreas, duodenum, oxidative stress

### **1. Introduction**

Chronic alcohol consumption is known to be an important risk factor for the development of upper gastrointestinal tract damage involving the stomach, duodenum, and accessory digestive organs such as the pancreas (1, 2). Compared to other organs, the upper GIT often comes in direct contact with ingested alcoholic beverages and is therefore, prone to diverse morphological, functional, and metabolic disturbances (3). Regarding the intestines, morphological alterations are reportedly more pronounced in the duodenum compared to the jejunum and ileum (4). Mucosal injuries such as duodenal erosions and bleeding induced by alcohol in the upper GIT are responsible for disturbances in digestion and absorption of nutrients with consequent malnutrition and loss of weight frequently observed in chronic alcohol users (5). Furthermore, increased intestinal permeability resulting from alcohol-induced mucosal injuries may facilitate the movement of toxic substances such as endotoxins into the blood circulation from where they are transported to other critical organs (6). Due to the intimate anatomical relationship between the duodenum and pancreas, it is highly likely that the severity of alcohol-induced toxicity in one of the organs could also reflect in the other. In fact, chronic alcohol consumption has been reported to cause 17-25% of acute pancreatitis and 40-70% of chronic pancreatitis cases (1).

Although most ethanol absorbed from the portal vein is metabolized in the liver, the gastrointestinal tract is also relevant in the metabolism of ethanol in small quantities via alcohol dehydrogenase in mucosal cells of the stomach and small intestine, accounting for what is known as the first pass metabolism (7). Alcohol dehydrogenase converts ethanol to acetaldehyde which is further converted to acetate by acetaldehyde dehydrogenase (8). In chronic alcohol exposure, however, the pathway of ethanol metabolism tend to shift towards the involvement of microsomal ethanol oxidizing system (MEOS) with induction of cytochrome P450 2E1, which is accompanied by increased generation of reactive oxygen species (ROS), including hydrogen

peroxide and superoxide radicals and resultant oxidative stress (9, 10). The interaction of ROS with cellular macromolecules, such as DNA and proteins causes structural and functional alterations, while oxidation of lipids by ROS produces toxic aldehydes such as malondialdehyde (MDA) and 4-hydroxynonenal (4-HNE) which causes further tissue damage (11). In addition, ROS and acetaldehyde have been implicated in the depletion of cellular glutathione and other components of the antioxidant system (10). In addition, several gut bacteria possess the ability to metabolize ethanol into acetaldehyde, although this mostly occurs in the lower GIT i.e., the colon and rectum (12).

The common approaches for treatment of alcohol-related tissue damage in the gastrointestinal tract include the prevention of absorption of ingested alcohol from the intestines, as well as neutralizing harmful metabolites of alcohol metabolism and ROS. In addition, certain modern pharmacological agents e.g., disulfiram, acamprosate and naltrexone have been advanced for promotion of behavioural modifications such as induction of complete self-restraint towards alcohol use, reducing alcohol craving as well as the prevention of relapse (13). However, these drugs possess several side effects, including gastrointestinal and neurological symptoms (14). Therefore, novel treatments from natural products that can efficiently attenuate alcohol toxicity are increasingly sought out as promising therapeutic agents (15). Alpha-tocopherol (AT), a lipid-soluble vitamin and antioxidant has been shown to exert protective benefits on various tissues including the liver and cardiovascular tissues via its anti-oxidative and anti-inflammatory actions (16, 17). Being hydrophobic, it is an essential component of biological membranes where it serves a protective role against the peroxidation of fatty acids, thus preventing structural and functional injury to cells (18). Quercetin (QT), a natural compound is found in diverse sources and possesses antioxidant, radical scavenging and anti-inflammatory

properties (19). Several pharmacological properties of QT including hepato-protective (20), neuro-protective (21), anti-hypertensive (22) and anti-cancer (23) activities have been described.

Despite the continued toxicological importance of ethanol poisoning, there is limited information of the protective abilities of AT or QT against chronic ethanol-induced toxicity in pancreatic and duodenal tissues of rats, considering the proximity of these organs. Using biochemical and morphological approaches, the present study was undertaken to investigate the protective effects of AT, QT or their combination on pancreatic and duodenal mucosal injury caused by chronic oral exposure of rats to ethanol.

## **2. Materials and methods**

### *Chemicals*

Ethanol, alpha tocopherol, quercetin, xylol orange, sorbitol, ammonium ferrous sulphate, reduced glutathione (GSH), 1, 2-dichloro-4-nitrobenzene (CDNB), thiobarbituric acid (TBA), trichloroacetic acid (TCA), sodium hydroxide, 5, 5'-dithiobis-2-nitrobenzoic acid (DTNB) and hydrogen peroxide were purchased from Sigma-Aldrich (St. Louis, Missouri, USA). All other chemicals were of the highest purity commercially available.

### *Animals and experimental design*

A total of forty (40) male Wistar rats weighing 120 to 150 g were purchased from the Experimental Animal Unit of the Faculty of Veterinary Medicine, University of Ibadan (Ibadan, Nigeria). The rats were housed inside plastic cages in a well-ventilated animal house facility with

12 h light/dark cycle during an initial acclimatization period of one week and the actual experimental period. They were allowed unrestricted access to rat chow and clean tap water throughout the duration of the experiment. All animals were handled following guidelines in the “Guide for the Care and Use of Laboratory Animals” prepared by the National Academy of Science and published by the National Institute of Health (24)

The rats were allocated randomly into five groups made up of seven rats each including (I) control rats administered normal saline (2 ml/kg); (II) Eth40 group exposed to ethanol mixed with normal saline to a final concentration of 40% (v/v); (III) Eth40+AT group consisting of rats exposed to 40% ethanol along with alpha tocopherol (2.5 mg/kg);(IV) Eth40+QT group of rats administered 40% ethanol and quercetin (50 mg/kg);(V) Eth40+AT+QT group where rats were exposed to all three compounds i.e. ethanol, alpha tocopherol and quercetin at the indicated dosages. The administration of the compounds was done by oral gavage and lasted for forty consecutive days. On each day, alpha tocopherol and quercetin were administered one hour prior to ethanol exposure. The dosages of ethanol (25), alpha tocopherol (26) and quercetin (27) were chosen based on previous studies.

#### *Blood glucose measurement*

Following overnight fasting of rats on the final day of the experiment, blood samples were withdrawn from the tail vein and were used for the measurement of fasting plasma glucose levels using the AACU-CHECK Active Blood Glucose monitoring system (Roche Diagnostics Int. Ltd, Rotkreuz, Switzerland).

#### *Determination of biochemical markers of oxidative stress*

At the end of the experiment, the rats were sacrificed by cervical dislocation and the pancreas and duodenum were carefully dissected out. The duodenum was opened longitudinally along the entire length and both tissues were homogenized in potassium phosphate buffer (100 mM; pH 7.4). The homogenate was then centrifuged with a refrigerated centrifuge (4 °C) at 12,000  $g$  for 10 min. The supernatant collected was used for the determination of levels of oxidative stress markers and the activities of some antioxidant enzymes.

The protein content of the tissues was quantified using Biuret reagent and values were extrapolated from a standard curve prepared with bovine serum albumin(28). Hydrogen peroxide ( $H_2O_2$ ) concentration in the tissues was measured according to the method of Wolff *et al* (29) from a reaction mixture containing sorbitol (100  $\mu$ L), ammonium ferrous sulfate(250  $\mu$ L), xylenol orange (100  $\mu$ L) and sulfuric acid(25  $\mu$ L). The mixture was incubated at room temperature and the absorbance was read at 560 nm. The total thiol content of the tissues was estimated according to the method of Ellman (30), using 5, 5'-dithiobis-(2-nitrobenzoic acid) (DTNB) as the colorigenic chemical.

Lipid peroxidation in the tissues was estimated by measuring the concentration of malondialdehyde (MDA) according to the method of Varshney and Kale (31). Briefly, samples (0.4 mL) were initially added to Tris-KCl buffer (1.6 mL) and then deproteinized with trichloroacetic acid (TCA, 30% w/v). Thereafter, thiobarbituric acid (TBA, 0.75% IN 0.2 M HCl) was added to specifically react with MDA. The mixture was heated at about 80°C in a water bath for 45 min, with the development of a pink color indicative of the formation of the TBA-MDA complex. Following centrifugation, the absorbance of the supernatant was read at 532 nm and MDA concentration was calculated from a molar extinction coefficient of  $1.56 \times 10^5 \text{ cm}^{-1}, \text{ M}^{-1}$ .

The level of advanced oxidation protein products (AOPP) in the duodenum and pancreas was determined according to the method of Kayali *et al* (32). The reaction mixture contained the colon homogenate added to 1.16 M potassium iodide and acetic acid. Following incubation, the absorbance was read at 340 nm and the AOPP content was calculated using a molar extinction coefficient of  $261 \text{ cm}^{-1} \text{ mM}^{-1}$ .

The activity of the antioxidant enzyme, glutathione peroxidase (GPx) in the pancreatic and duodenal tissues was determined according to the method of Rotruck *et al* (33). The activity of Glutathione S-transferase (GST) was monitored over a time period of 3 min at an absorbance 340 nm at 30-seconds intervals using its ability to catalyze the conjugation of GSH with 1-chloro-2, 4-dinitrobenzene (CDNB). The assay was performed according to the method of Habig *et al*(34).

#### *Histopathological examination*

The pancreas from selected rats was carefully dissected from its attachment to the duodenum and was immediately placed in 10% phosphate-buffered formalin until the processing for histopathological examination. Similarly, portions of the duodenum were also fixed in phosphate-buffered formalin. Thereafter, the tissues were embedded in paraffin; sections of about  $5\mu\text{m}$  were made and were stained on glass slides with Haematoxylin and eosin (H&E). The slides were examined by a pathologist who was blinded to the experimental design

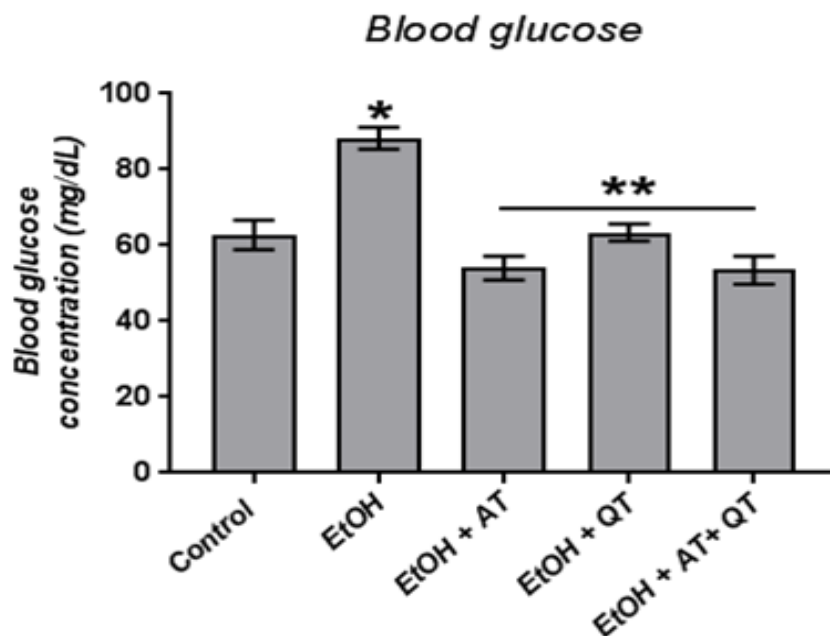
#### *Statistical analysis*

The data obtained are presented as mean  $\pm$  standard deviation. The means were analyzed and compared with one-way analysis of variance (ANOVA) followed by Tukey's post-hoc test using GraphPad Prism software Version 7 (GraphPad Software Inc. San Diego, CA)

### **3. Results**

#### **Blood glucose**

Blood glucose levels in the experimental rats are presented in Fig. 1. From the obtained results, blood glucose levels in rats administered ethanol was significantly ( $P < .0001$ ) elevated when compared with the control group. On the other hand, treatment of rats with alpha tocopherol ( $P < .0001$ ) or Quercetin ( $P < .0001$ ), separately or in combination ( $P < .0001$ ), led to significant decrease in blood glucose levels.



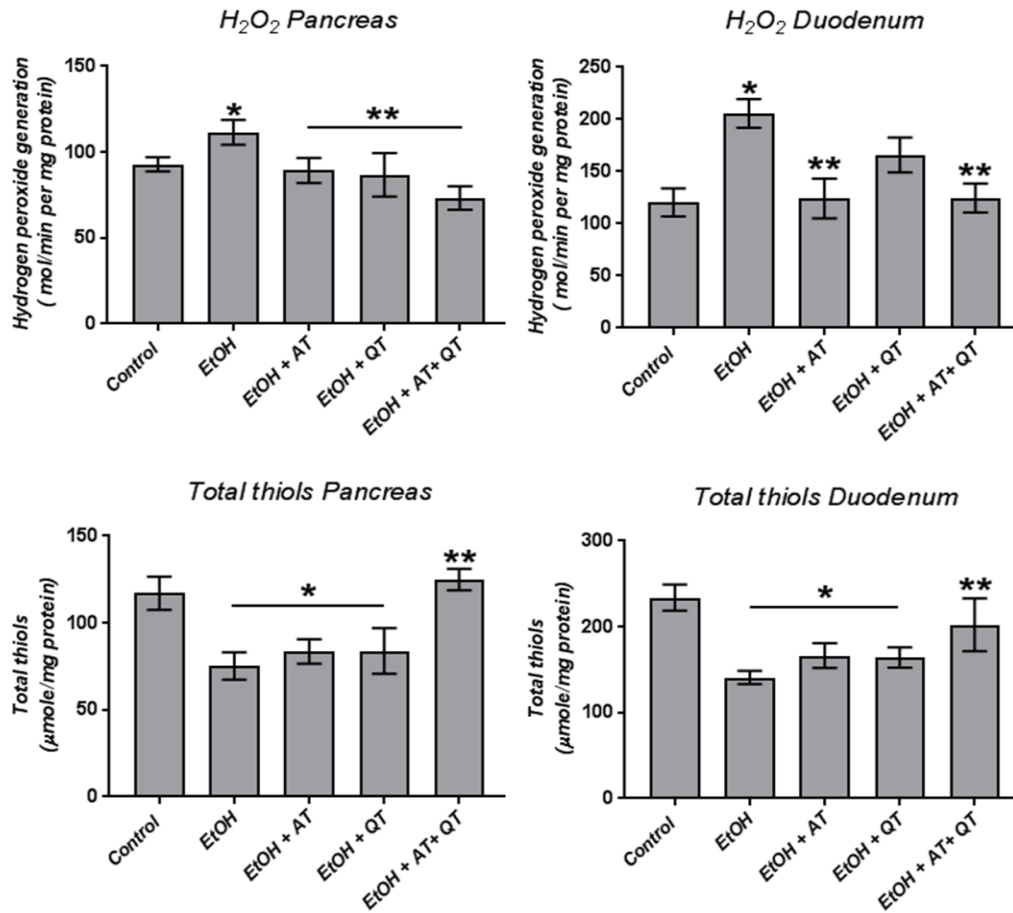
**Fig. 1: Effect of alpha-tocopherol (AT) and quercetin (QT) on blood glucose levels in ethanol-treated rats.** Data are presented as mean  $\pm$  SD of values from seven rats per group. \*indicates significant difference ( $p < 0.05$ ) when compared with control; \*\*indicates significant difference when compared with ethanol-treated rats.

### **Oxidative stress and antioxidant markers**

The concentrations of hydrogen peroxide ( $H_2O_2$ ) and thiol groups in the pancreas and duodenum of control and experimental rats are presented in Fig. 2. A significant elevation in the level of  $H_2O_2$  was observed in both the pancreas ( $P = .01$ ) and duodenum ( $P < .001$ ) of ethanol-exposed rats, when compared to control. Administration of alpha tocopherol ( $P = .002$ ), quercetin ( $P = .002$ ) or their combination ( $P < 0.0001$ ) along with ethanol caused significant reduction in pancreatic  $H_2O_2$  levels when compared with the alcohol-administered rats. In the

duodenum, either the administration of alpha tocopherol ( $P < .001$ ) or the combination of alpha tocopherol and quercetin ( $P < 0.001$ ) led to significant reduction in  $H_2O_2$  levels, compared to the rats treated with ethanol alone.

When compared with control rats, total thiol concentration in the pancreas was significantly ( $P < .0001$ ) reduced in ethanol-treated rats, as well as rats treated concurrently with either alpha-tocopherol ( $P < .0001$ ) or quercetin ( $P < .0001$ ). However, there was significant ( $P < .0001$ ) increase in thiol levels when ethanol-exposed rats were treated with a combination of alpha-tocopherol and quercetin. In the duodenum, ethanol administration also led to significant ( $P < .0001$ ) reduction in total thiol levels, compared to the control. Similar to the observation in the pancreas, total thiol concentration were only significantly ( $P < .001$ ) elevated when both alpha tocopherol and quercetin were administered to ethanol-exposed rats.

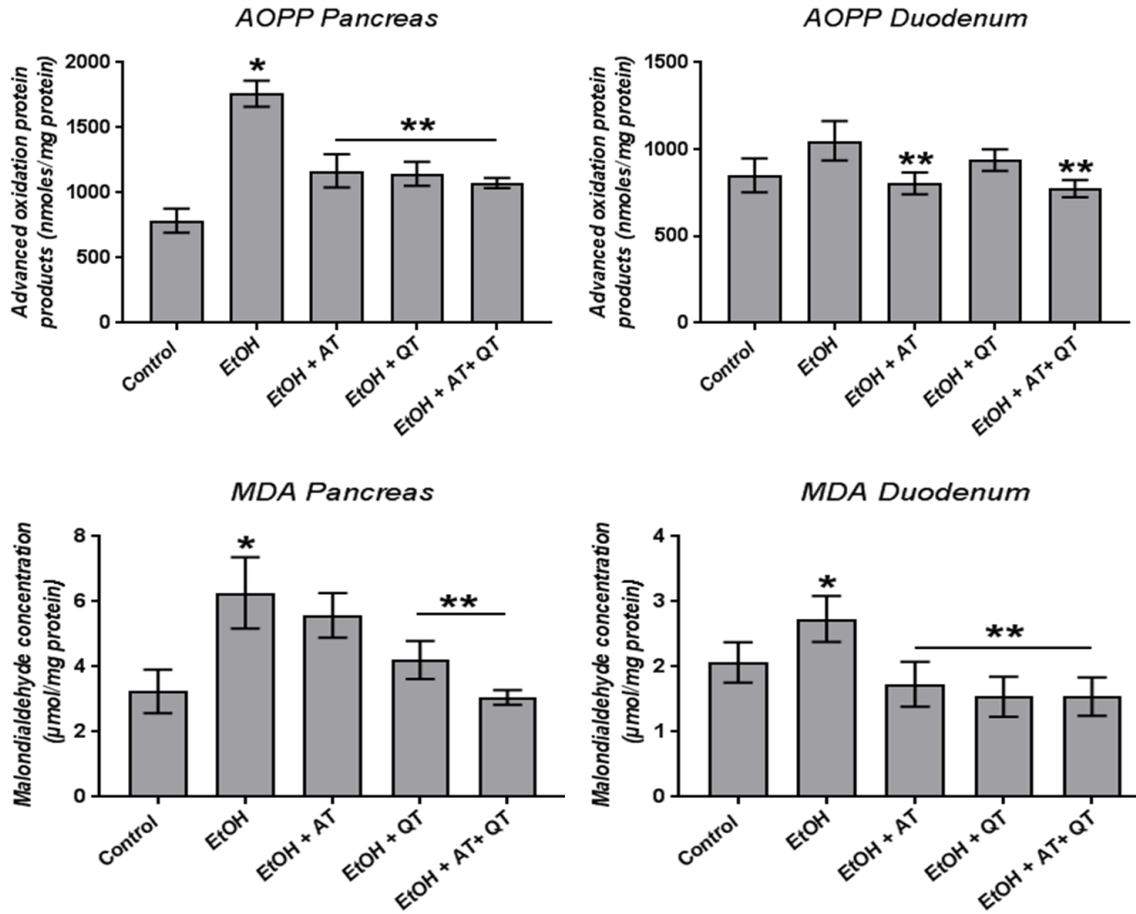


**Fig. 2: Effect of alpha-tocopherol (AT) and quercetin (QT) on pancreatic and duodenal concentrations of hydrogen peroxide (H<sub>2</sub>O<sub>2</sub>) and thiols in ethanol-treated rats.** Data are presented as mean±SD of values from seven rats per group. \*indicates significant difference ( $p < 0.05$ ) when compared with control; \*\*indicates significant difference when compared with ethanol-treated rats.

The levels of advanced oxidation protein products (AOPP) in the pancreas and duodenum are presented in Fig. 3. From the results obtained, rats administered ethanol showed significant ( $P < .0001$ ) increase in pancreatic AOPP levels, compared to the control rats. Duodenal AOPP levels were also elevated in ethanol-exposed rats, but not significantly in comparison with control. A significant ( $P < .0001$ ) decrease in pancreatic AOPP level was noted in animals treated with either alpha tocopherol or quercetin, in comparison with rats administered with ethanol

alone. The AOPP levels in the duodenum was ameliorated significantly ( $P < .01$ ) in animals treated with a combination of alpha tocopherol and quercetin, compared to those exposed to ethanol only.

In similar fashion to AOPP levels, ethanol administration led to significant elevation in malondialdehyde (MDA) levels in both pancreas ( $P < .0001$ ) and duodenum ( $P = 0.02$ ) when compared with control. In the pancreas, MDA level was significantly reduced in rats treated with quercetin ( $P < .001$ ) or alpha tocopherol+quercetin combination ( $P < .0001$ ), compared to rats exposed to ethanol alone. Furthermore, administration of alpha-tocopherol, quercetin or their combination along with ethanol decreased the levels of MDA significantly ( $P < .0001$ ) in the duodenum when compared to that of animals exposed to ethanol only.

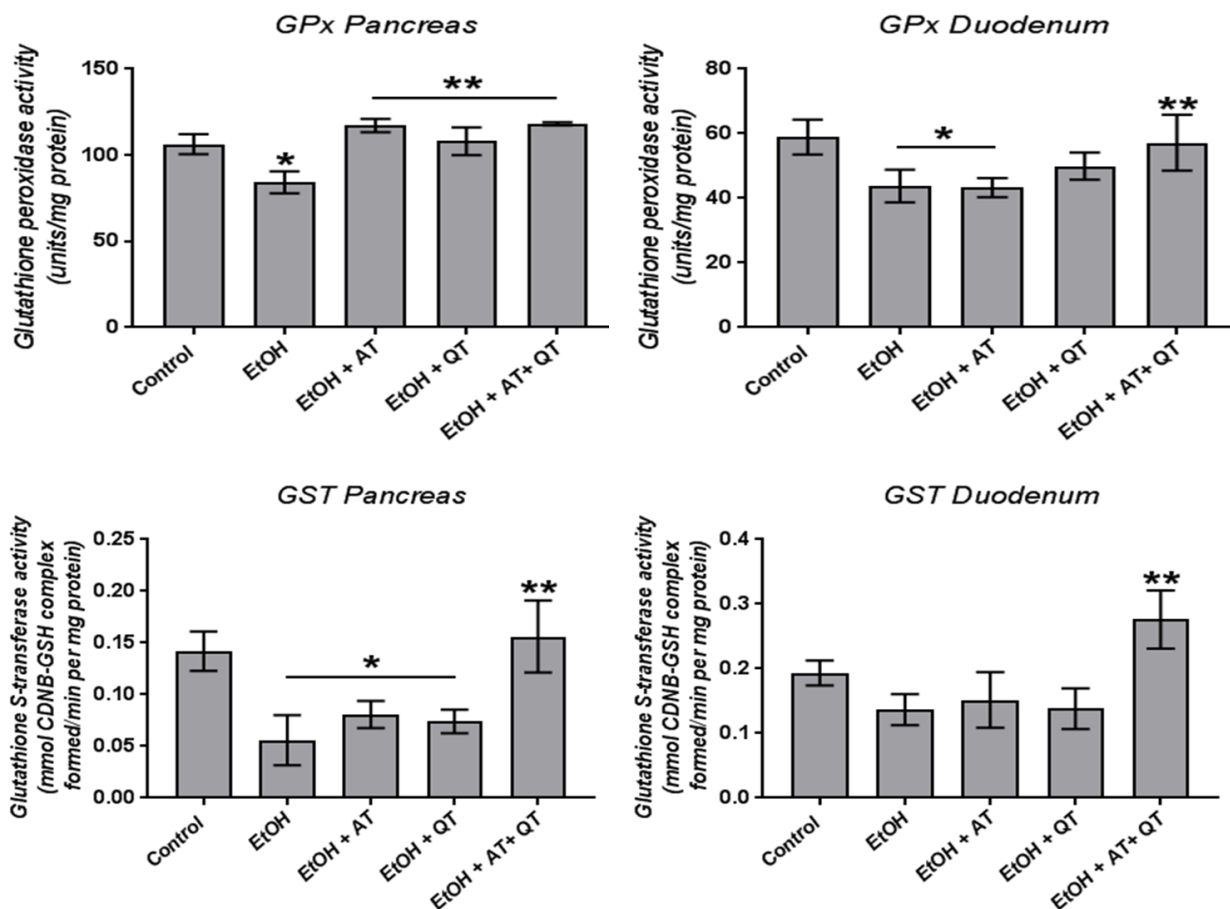


**Fig. 3: Effect of alpha-tocopherol (AT) and quercetin (QT) on pancreatic and duodenal concentrations of advanced oxidation protein products (AOPP) and malondialdehyde (MDA) in ethanol-treated rats.** Data are presented as mean  $\pm$  SD of values from seven rats per group. \*indicates significant difference ( $p < 0.05$ ) when compared with control; \*\*indicates significant difference when compared with ethanol-treated rats.

The activities of glutathione peroxidase (GPx) and glutathione S-transferase (GST) in the pancreas and duodenum are depicted in Fig. 4. The data obtained showed that ethanol exposure significantly ( $P = .01$ ) reduced GPx activity in both the pancreas and duodenum following ethanol exposure relative to control rats. In contrast, treatment of ethanol-exposed rats with alpha-tocopherol ( $P < .001$ ), quercetin ( $P < .01$ ) or their combination ( $P < .001$ ) caused

significant improvement in pancreatic GPx activity, while duodenal GPx activity was significantly ( $P = .02$ ) increased only in rats treated with a combination of alpha-tocopherol and quercetin.

Ethanol exposure caused decreases in the pancreatic GST activity when compared with the control (Fig. 4). However, GST activity in the pancreas ( $P < .0001$ ) and duodenum ( $P < .01$ ) was significantly increased in rats that underwent combined treatment with alpha-tocopherol and quercetin, when compared with ethanol-exposed rats.

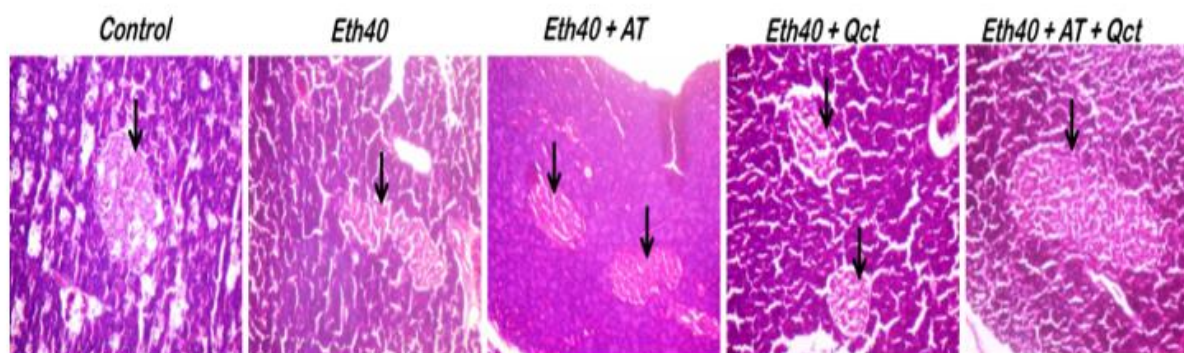


**Fig. 4:** Effect of alpha-tocopherol (AT) and quercetin (QT) on pancreatic and duodenal activities of Glutathione peroxidase (GPx) and Glutathione S-transferase (GST) in ethanol-

**treated rats.** Data are presented as mean  $\pm$  SD of values from seven rats per group. \*indicates significant difference ( $p < 0.05$ ) when compared with control; \*\*indicates significant difference when compared with ethanol-treated rats.

### Histopathological findings

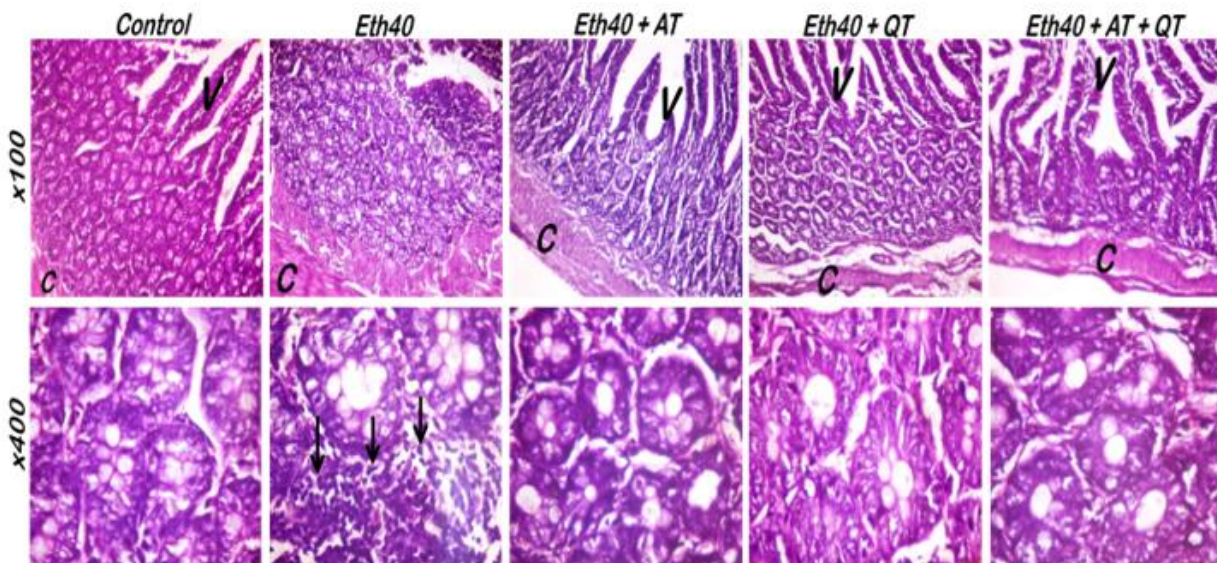
The pancreatic tissues from the control and experimental rats all had normal exocrine acini with zymogen granules and normal intra-lobular and inter-lobular ducts (Fig. 5). However, rats administered 40% ethanol showed islets of Langerhans with shrunken appearance and irregular outline, compared with control rats which had well rounded islets that appear to be normally-proliferating. Treatment of ethanol-exposed rats with alpha-tocopherol or quercetin resulted in partial recovery of the islets, while rats treated with a combination of the two compounds produced remarkable recovery of islet cells which had similar morphology to those of the control rats.



**Fig. 5: Representative photomicrographs of sections of the pancreas stained by H&E (Mag. X100):** Sections of pancreas from control rats showed normal proliferating islet of Langerhans and normal exocrine acini with zymogen granules. Rats treated with 40% ethanol (Eth40) showed islet of Langerhans that appeared shrunken with irregular outline but normal appearance of the exocrine portions. Rats exposed to ethanol concurrently with alpha-tocopherol (Eth40+AT) or quercetin (Eth40+Qct) presented partly recovered islet, while rats treated with a combination of ethanol, alpha-tocopherol and

quercetin (Eth40+AT+QT) showed normal proliferating islets and exocrine tissues similar to the control rats. Islets of Langerhans are indicated by black arrows.

The sections of the duodenum in the control and experimental rats are presented in Fig. 6. By light microscopy, the major pathological lesions observed in alcohol-treated rats were disseminated inflammatory cell infiltration into the duodenal mucosa and as well as necrosis and shedding of the mucosa presenting barely discernible villi. Control rats, on the other hand, showed normal duodenal mucosal morphology with distinct villi and epithelial surfaces. Treatment with alpha tocopherol or quercetin or their combination was able to prevent the ethanol-induced pathological changes in the duodenum as the rats in these groups had morphology which was similar to that of control rats



**Fig. 6: Representative photomicrographs of sections of the duodenal mucosa stained by H&E (Mag. Upper plates: x100; Lower plates: x400):** Sections of the duodenum from control rats presented with normal morphology of the epithelium and villi. Rats treated with 40% ethanol (Eth40)

showed eroded epithelium, loss of villi and severe inflammatory cell infiltrations of the mucosa and submucosa (black arrow). Duodenal sections from rats treated with alpha tocopherol (Eth40+AT), quercetin (Eth40+QT) or their combination (Eth40+AT+QT) showed no significant lesions with morphology similar to the control group. C – circular muscle; V - villi.

UNDER PEER REVIEW

#### 4. Discussion

There exists a well-known relationship between alcoholism and the development of pancreatic injuries (35). *In vitro* ethanol exposure of rat  $\beta$ -cell line RINm5F caused induction of oxidative stress and  $\beta$ -cell death by apoptosis (36). Several published studies have also alluded to the fact that alcohol consumption can acutely or chronically damage the intestinal mucosa (4, 37). The present research examined the protective effect of alpha tocopherol and quercetin on pancreatic and duodenal mucosal injuries caused by chronic ethanol exposure using biochemical and morphological assessments in Wistar rats.

The findings from this study demonstrated that administration of ethanol for 40 consecutive days caused: (i) increased blood glucose levels above control values; (ii) morphological alterations, such as shrunken/atrophied islets in the pancreas and pathological lesions including necrosis, mucosal shedding, inflammatory cell infiltration and loss of villi architecture in the duodenum; (iii) increased production of reactive oxygen species and oxidative stress in the pancreas and duodenum manifested by increased  $H_2O_2$ , advanced oxidation protein products (AOPP) and malondialdehyde (MDA), as well as the decreased levels of thiols and reduced activities of GPx and GST. Significantly, we found that administration of alpha-tocopherol and/or quercetin ameliorated the morphological and oxidative alterations in the duodenum and pancreas compared to the ethanol group, while also restoring blood glucose levels to levels found in the control group.

Regarding the effects of alcohol consumption on glycaemic status, previous studies in humans and pre-clinical models have described a dichotomy situation between acute and chronic exposure to alcohol. Acute administration of alcohol has been observed to often produce either a reduction or no change in blood glucose levels (38). On the other hand, studies have also suggested that chronic alcohol treatment may result in elevated blood sugar levels via pancreatic islet dysfunction (39). In fact, it has been observed that long-term alcohol use by diabetic patients can further enhance blood sugar levels and aggravate long-term diabetic complications including neuropathy, retinopathy and nephropathy (40). Mechanisms involved in elevation of blood glucose levels after chronic alcohol administration include the induction of pancreatitis, disturbances in carbohydrate metabolism, as well as its obesity-inducing effects.

In the present study, rats exposed chronically to 40% ethanol showed a tendency towards increased blood glucose levels, compared to all other groups, although the values remained within normal ranges of blood glucose (about 50 – 135 mg/dL) usually found in rats(41) with none of the values reaching 200 mg/dL at which the rats could be considered diabetic. Morphologically, these animals revealed slight shrinking of the pancreatic islets of Langerhans indicating possible loss of insulin-secreting cells which could impact on mobilization of glucose from blood. This result agrees with findings reported by Shanmugamet *al* (42) where rats given 20% alcohol for 30 days showed increased blood glucose levels compared to the normal controls. In the present study, concurrent treatment of rats with alpha tocopherol and/or Quercetin improved the morphology of the pancreatic tissues, and this appeared to reflect on the recorded blood glucose levels in these groups of rats which were similar to those of the controls. The ethanol-treated rats showed morphological alterations in the duodenum, including distorted villi, mucosal necrosis and inflammatory cell infiltration similar to observations from previous

studies (4), although these lesions were considerably ameliorated with concurrent treatment with alpha tocopherol and/or Quercetin.

The toxic effects of alcohol consumption on various organs have been attributed to either direct chemical injury or indirect pathways such as increased generation of reactive oxygen species or the release of inflammatory mediators causing oxidative stress and/or inflammation (43, 44, 45). The increase in pancreatic and duodenal levels of  $H_2O_2$ , AOPP and MDA observed in ethanol-exposed rats in this study is an indication of increased generation of ROS and chemical modification of both proteins and lipids which may lead to structural and functional alterations in these tissues. In addition, our results showed a corresponding weakening of the antioxidant defense system by ethanol administration indicated by reduction in the tissue content of sulfhydryl groups as well as the activities of GST and GPx. The decreased activities of the antioxidant enzymes GPx and GST may be directly related to a depletion of thiol groups including reduced glutathione which is utilized as a co-factor by these enzymes. In support of these results, Pushpakiran *et al* (46) had previously alluded to a decline in GSH levels when rats were treated with ethanol, leading to a corresponding decrease in the activities of glutathione-dependent antioxidant enzymes due to increased utilization of GSH, and in the present study, thiol groups, for trapping of free radicals.

The present results indicate that supplementation of ethanol-exposed rats with either alpha tocopherol or Quercetin produced alleviation of tissue oxidant stress as evidenced by reduction in  $H_2O_2$ , AOPP and MDA in both the pancreas and duodenum. More importantly, rats treated with a combination of the two compounds showed a greater degree of reversal of oxidative stress compared to their separate administrations. This synergism in the actions of alpha tocopherol and Quercetin was further demonstrated by significant improvement in the

antioxidant defense system including enzymic (GPx and GST) and non-enzymic (thiols) antioxidants. Both alpha tocopherol and Quercetin are important dietary constituents which are known to offer profound antioxidant benefits (Amevor *et al.*, 2022). Although, some studies have reported the effects of individual treatments of each compound against ethanol toxicity in the small intestine (4), the present results is the first attempt to understand whether their combination would be more beneficial against ethanol toxicity in the pancreas and duodenum. Interestingly, the combination of vitamin E and Quercetin in chickens were reported to improve reproductive endpoints including spermatogenesis and hormone secretion via promotion of antioxidant defense systems and immune response without any harmful effects (47).

## **Conclusions**

From the results of this study, it is obvious that chronic administration of ethanol induced morphological and biochemical alterations in the duodenum and pancreas. The anatomical proximity of the two organs in the upper digestive tract could be involved in the promotion of toxic effects from one organ to the other. For instance, previous studies have suggested that pancreatic dysfunction leading to reduced bicarbonate secretion could lead to failure of neutralization of gastric acid in the duodenum thereby inciting duodenum inflammation. Furthermore, alpha tocopherol or Quercetin, especially when administered as a combination can alleviate the alterations induced by chronic ethanol exposure. However, further studies are required to clarify the molecular mechanisms involved in ethanol toxicity in the context of anatomical relationship between the duodenum and pancreas as well as the mechanisms promoting the synergistic effects of alpha tocopherol and Quercetin.

## **Ethical Approval**

**Animal Ethic committee approval has been collected and preserved by the author(s)**

**Conflict of interest**

The authors declare no conflicts of interests whatsoever

UNDER PEER REVIEW

## 5. References

1. Herreros-Villanueva M, Hijona E, Bañales JM, Cosme A, Bujanda L. Alcohol consumption on pancreatic diseases. *World J Gastroenterol.* 2014; 19(5):638-47.
2. Haber PS, Kortt NC. Alcohol use disorder and the gut. *Addiction.* 2021; 116(3):658-667, doi: 10.1111/add.15147.
3. Bode C, Bode JC. Effect of alcohol consumption on the gut”, *Best Pract Res Clin Gastroenterol.* 2003; 17(4):575-92. doi: 10.1016/s1521-6918(03)00034-9.
4. Shirpoor A, Barmaki H, Khadem Ansari M, Lkhanizadeh B, Barmaki H. Protective effect of vitamin E against ethanol-induced small intestine damage in rats. *Biomed Pharmacother.* 2016; 78:150-155. doi: 10.1016/j.biopha.2016.01.015.
5. Pohl K, Moodley P, Dhanda AD. Alcohol’s Impact on the Gut and Liver. *Nutrients.* 2021; 13(9):3170. <https://doi.org/10.3390/nu13093170>
6. Starkel P, Leclercq S, de Timary P, Schnabl B. Intestinal dysbiosis and permeability: The yin and yang in alcohol dependence and alcoholic liver disease. *Clin. Sci.* 2018; 132: 199–212.

7. Lieber CS. ALCOHOL: Its metabolism and interaction with nutrients. *Annu. Rev. Nutr.* 2000;20: 395–430.
8. Li S, Gan LQ, Li SK, Zheng JC, Xu DP, Li HB. Effects of herbal infusions, tea and carbonated beverages on alcohol dehydrogenase and aldehyde dehydrogenase activity. *Food Funct.* 2014;5:42–49, (2014).doi: 10.1039/C3FO60282F.
9. Cederbaum AI, Lu Y, Wu D. Role of oxidative stress in alcohol-induced liver injury. *Arch. Toxicol.* 2009;83: 519–548.
10. Tsermpini EE, Plemenitaš Ilješ A, Dolžan V. 2022. Alcohol-Induced Oxidative Stress and the Role of Antioxidants in Alcohol Use Disorder: A Systematic Review. *Antioxidants.* 2022; 11(7):1374. <https://doi.org/10.3390/antiox11071374>
11. Wang Y, Millonig G, Nair J, Patsenker E, Stickel F, Mueller S, Bartsch H, Seitz HK. Ethanol-induced cytochrome P4502E1 causes carcinogenic etheno-DNA lesions in alcoholic liver disease. *Hepatology.* 2009; 50: 453–461.
12. Malaguarnera G, Giordano M, Nunnari G, Bertino G, Malaguarnera M. Gut microbiota in alcoholic liver disease: pathogenetic role and therapeutic perspectives. *World J Gastroenterol.* 2014; 20(44):16639-48.doi: 10.3748/wjg.v20.i44.16639.
13. Wang F, Li Y, Zhang YJ, Zhou Y, Li S, Li HB. Natural Products for the Prevention and Treatment of Hangover and Alcohol Use Disorder, *Molecules.* 2016;21(1):64, (2016).doi: 10.3390/molecules21010064.
14. Burnette EM, Nieto SJ, Grodin EN *et al.* Novel Agents for the Pharmacological Treatment of Alcohol Use Disorder, *Drugs,* 2022; 82: 251–274 (2022). <https://doi.org/10.1007/s40265-021-01670-3>

15. Singh L, Joshi T, Tewari D, Echeverría J, Mocan A, Sah AN, Parvanov E, Tzvetkov NT, Ma ZF, Lee YY, Poznański P, Huminiecki L, Sacharczuk M, Józwick A, Horbańczuk JO, Feder-Kubis J, Atanasov AG. Ethnopharmacological Applications Targeting Alcohol Abuse: Overview and Outlook, *Front. Pharmacol.* 2020;10:1593. (2020).doi: 10.3389/fphar.2019.01593
16. Helmy MM. Potential hepato-protective effect of a-tocopherol or simvastatin in aged rats”, *Pharmacol Rep.* 2012;64: 698-705.
17. Prathibha P, Rejitha S, Harikrishnan R, Das SS, Abhilash PA, Indira M. Additive effect of alpha-tocopherol and ascorbic acid in combating ethanol-induced hepatic fibrosis. *Redox Rep.* 2013; 18(1):36-46.doi: 10.1179/1351000212Y.0000000038.
18. Galli F, Bonomini M, Bartolini D, Zatini L, Reboldi G, Marcantonini G, Gentile G, Sirolli V, Di Pietro N. Vitamin E (Alpha-Tocopherol) Metabolism and Nutrition in Chronic Kidney Disease. *Antioxidants.* 2022; 11(5):989. <https://doi.org/10.3390/antiox11050989>
19. Kalender Y, Kaya S, Durak D, Uzun FG, Demir F. Protective effects of catechin and quercetin on antioxidant status, lipid peroxidation and testis-histoarchitecture induced by chlorpyrifos in male rats. *Environ ToxicolPharmacol.* 2012;33: 141-148.
20. Pingili RB, Challa SR, Pawar AK, Toleti V, Kodali T, Koppula S. A systematic review on hepatoprotective activity of quercetin against various drugs and toxic agents: Evidence from preclinical studies. *Phytother Res.* 2020; 34(1):5-32. doi: 10.1002/ptr.6503.
21. Choi GN, Kim JH, Kwak JH, Jeong CH, Jeong HR, Lee U, Heo HJ. Effect of quercetin on learning and memory performance in ICR mice under neurotoxic trimethyltin exposure. *Food Chem.*2012; 132: 1019–1024.doi: 10.1016/j.foodchem.2011.11.089.

22. Duarte J, Pérez-Palencia R, Vargas F, Ocete MA, Pérez-Vizcaino F, Zarzuelo A, Tamargo J. Antihypertensive effects of the flavonoid quercetin in spontaneously hypertensive rats, *Br. J. Pharm.* 2001;133:117–124.doi: 10.1038/sj.bjp.0704064.
23. Zhang XA, Zhang S, Yin Q, Zhang J. Quercetin induces human colon cancer cells apoptosis by inhibiting the nuclear factor-kappa B Pathway, *Pharm. Mag.* 2015;11:404–409.doi: 10.4103/0973-1296.153096.
24. Public Health Service (PHS). Public health service policy on humane care and the use of laboratory animals, Washington, DC: US Department of Health and Humane Services, 99–158, (1996).
25. Rezaee-Khorasany A, Razavi BM, Taghiabadi E, Tabatabaei Yazdi A, Hosseinzadeh H, Effect of crocin, an active saffron constituent, on ethanol toxicity in the rat: histopathological and biochemical studies.*Iranian Journal of Basic Medical Sciences*, 2020; 23(1): 51–62.
26. Wallert M, Ziegler M, Wang X, Maluenda A, Xu X, Yap ML, Witt R, Giles C, Kluge S, Hortmann M, Zhang J, Meikle P, Lorkowski S, Peter K.  $\alpha$ -Tocopherol preserves cardiac function by reducing oxidative stress and inflammation in ischemia/reperfusion injury”,*Redox Biol.* 2019; 26:101292.doi: 10.1016/j.redox.2019.101292.
27. Ajibade TO, Oyagbemi AA, Omobowale TO, Asenuga ER, Adigun KO. Quercetin and Vitamin C Mitigate Cobalt Chloride-Induced Hypertension through Reduction in Oxidative Stress and Nuclear Factor Kappa Beta (NF-Kb) Expression in Experimental Rat Model,*Biol Trace Elem Res.* 2017; 175(2): 347-359, (2017).
28. Gornal AG, Bardawill JC, David MM. Determination of serum proteins by means of Biuret reaction.*J Biol Chem.* 1949; 177: 751–766.

29. Wolff SF. Ferrous ion oxidation in the presence of ferric ion indicator xylenol orange for measurement of hydrogen peroxides. *Methods Enzymol.* 1994; 233: 182–189.
30. Ellman GL. Tissue sulfhydryl groups. *Archives of Biochemistry and Biophysics*, 1959; 82(1):70–77, [https://doi.org/10.1016/0003-9861\(59\)90090-6](https://doi.org/10.1016/0003-9861(59)90090-6)
31. Varshney R, Kale RK. Effect of calmodulin antagonists on radiation-induced lipid peroxidation in microsomes. *Int. J. Radiat Biol.* 1990; 58: 733–743.
32. Kayali R, Cakatay U, Akcay T, Altug T. Effect of alpha-lipoic acid supplementation on markers of protein oxidation in post-mitotic tissues of ageing rat. *Cell Biochem Funct.* 2006. 24: 79-85. Doi: 10.1002/cbf.1190.
33. Rotruck JT, et al. Selenium: biochemical role as a component of glutathione peroxidase”, *Science.* 1973. 179 (4073): 588– 590.
34. Habig WH, Pabst MJ. Glutathione-S-transferases. The first enzymatic step in mercapturic acid formation. *J Biol Chem.* 1974; 25: 7130–7139.
35. Vigna SR, Shahid RA, Liddle RA. Ethanol contributes to neurogenic pancreatitis by activation of TRPV1. *FASEB J.* 2014; 28(2):891-6, doi: 10.1096/fj.13-236208.
36. Dembele K, Nguyen HK, Hernandez TA, Nyomba G. Effects of ethanol on pancreatic beta-cell death: Interaction with glucose and fatty acids. *Cell Biol Toxicol.* 2009; 25(2): 141-152.
37. Bienia A, Sodolski W, Luchowska E. The effect of chronic alcohol abuse on gastric and duodenal mucosa. *Ann Univ Mariae Curie Sklodowska Med.* 2002; 57(2):570-82.
38. Carr RM, Dhir R, Yin X, Agarwal B, Ahima RS. Temporal effects of ethanol consumption on energy homeostasis, hepatic steatosis, and insulin sensitivity in mice. *Alcohol. Clin. Exp. Res.* 2013; 37: 1091–1099.

39. Yang BC, Wu SY, Leung PS. Alcohol ingestion induces pancreatic islet dysfunction and apoptosis via mediation of FGF21 resistance. *Annals of Translational Medicine*. 2020; 8(6): 310; doi: 10.21037/atm.2020.02.129.
40. Nygren K, Hammarström A, Rolandsson O. Binge drinking and total alcohol consumption from 16 to 43 years of age are associated with elevated fasting plasma glucose in women: results from the northern Swedish cohort study. *BMC Public Health*. 2017;17(1):509. doi: 10.1186/s12889-017-4437-y.
41. Hidayaturrahmah Santoso HB, Rahmi RA, Kartikasari D. Blood glucose level of white rats (*Rattus norvegicus*) after giving catfish biscuit (*Pangasius hypothalmus*). *BIO Web of Conferences* 20(1):04005, 2020. DOI: [10.1051/bioconf/20202004005](https://doi.org/10.1051/bioconf/20202004005)
42. Shanmugam KR, Mallikarjuna K, Reddy KS. Effect of alcohol on blood glucose and antioxidant enzymes in the liver and kidney of diabetic rats. *Indian J Pharmacol*. 2011;43(3):330-5. doi: 10.4103/0253-7613.81504.
43. Peres WA, Carmo MG, Zucoloto S, Iglesias AC, Braulio VB. Ethanol intake inhibits growth of the epithelium in the intestine of pregnant rats. *Alcohol* 2004;33: 83–89.
44. Kolli VK, Abraham P, Isaac B, Kasthuri N. Preclinical efficacy of melatonin to reduce methotrexate-induced oxidative stress and small intestinal damage in rats, *Dig. Dis. Sci*. 2013;58: 959–969.
45. Shirpoor A, Norouzi L, Khadem Ansari MH, Ilkhanizadeh B, Gharaaghaji R. Vasoprotective effect of vitamin E: rescue of ethanol-induced atherosclerosis and inflammatory stress in rat vascular wall, *Int. Immunopharmacol*. 2013;16: 498–504.

46. Pushpakiran G, Mahalakshmi K, Anuradha C. Taurine restores ethanol-induced depletion of antioxidants and attenuates oxidative stress in rat tissues, *Amino Acids*, 2004; **27**: 91–96. <https://doi.org/10.1007/s00726-004-0066-8>
47. Amevor FK, Cui Z, Ning Z, Shu G, Du X, Jin N, Deng X, Xu D, Tian Y, Zhang Y, Li D, Wang Y, Du X, Zhao X. Dietary quercetin and vitamin E supplementation modulates the reproductive performance and antioxidant capacity of aged male breeder chickens, *Poult Sci*. 2022; 101(6):101851, (2022). doi: 10.1016/j.psj.2022.101851.

UNDER PEER REVIEW