

EVALUATION OF THE OUTCOME OF INTERVENTIONS FOR THORACIC ENDOMETRIOSIS SYNDROME AT A TERTIARY LEVEL HEALTH INSTITUTION IN SOUTHERN NIGERIA

ABSTRACT

Background: Thoracic Endometriosis Syndrome (TES) is a clinical condition characterized by the presence of endometrial tissue within the thoracic cavity, catamenial pneumothorax, catamenial haemothorax, catamenial haemopneumothorax, catamenial haemoptysis and or endometrial nodular lung mass. The management can be challenging as treatment is fraught with recurrence.

Aim: To evaluate the outcome of interventions for Thoracic Endometriosis Syndrome.

Methods: This was a prospective cross-sectional study of 14 patients with thoracic endometriosis syndrome who were managed at the university of Port Harcourt Teaching Hospital between August 1, 2017, and July 31, 2023. A proforma was used to collect data on socio-demographic characteristics, clinical presentation, type of intervention and evidence of recurrence of chest symptoms and entered into a spread sheet. Data analysis was done with SPSS version 28. Results are presented as frequency tables and percentages.

Results: The age of the patients ranged between 20 and 44 years. Of the 14 patients, 11 (78.6%) were married, and 3 (21.4%) of the patients had established abdominal endometriosis with symptoms of thoracic endometriosis, while 4 (28.6%) had a histologic diagnosis of thoracic endometriosis. Pneumothorax was observed in 9 (64.23%) patients, 3 (21.43%) had haemopneumothorax, 2 (14.29%) with cyclical haemoptysis and haemothorax, and 4 (28.57%) of the patients had thoracic endometriotic nodules, while all the married had primary infertility. Twelve (85.7%) of the patients had closed tube thoracostomy drainage (CTTD) with chemical pleurodesis, while 4 (28.6%) had thoracotomy, decortication, bleb, and nodules resection with chemical pleurodesis. All the patients had hormonal therapy using luteinizing hormone-releasing hormone (LHRH) analogues. There was recurrence in 2 (14.3%) of the patients after a one-to-six-year period of follow-up.

Conclusion: The treatment of TES using CTTD with pleurodesis, thoracostomy, decortication, bleb resection and or hormonal therapy with appropriate patient selection is effective as only two cases of recurrences were recorded.

Key words: Endometriosis, Thoracic, Pleurodesis, Hormonal therapy, Nigeria.

1. INTRODUCTION

Endometriosis is the clinical phenomenon whereby the endometrial tissue is seen outside the normal uterine cavity. This frequently occurs in pelvic structures such as the ovary, cervix, vagina, uterine ligaments, and pelvic peritoneum [1]. It may also occur at extra pelvic sites, as it has been observed in the abdomen, lung, breasts, umbilicus, pleural cavity, and other extremities [2]. Thoracic endometriosis syndrome (TES) refers to the presence of endometrial tissue within or around the lungs [1]. TES is a spectrum of clinical presentations that are related to ectopic intrathoracic endometrial tissue, for which formal pathological identification is difficult and diagnosis is commonly made based on clinical features [3].

The pathogenesis of TES remains unclear. Although, three distinct theories have been proposed over the years [4]. The first is the coelomic metaplasia theory, which proposes the transformation of pleural epithelial cells into functional endometrial epithelial cells due to the long-term effect of the hormone oestrogen [5]. Another theory as reported by Vercellini et al [6] is that of retrograde menstruation, where there is a backflow of fluid from within the endometrium through the fallopian tubes during menstruation, thus causing the endometrial cells to be deposited on the right side of the diaphragm, which prompts diaphragmatic defects at right side of the chest cavity and ultimately leading to TES. The third theory is known as the lymphatic and haematogenous dissemination theory. This proposes the transfer of functional endometrial cells through the lymphatic vessels to the lungs following surgical procedures in the uterine cavity [7].

TES is characterized by varied clinical presentations, with majority of patients having no symptoms, while those with symptoms often present with clinical features as catamenial pneumothorax, catamenial haemothorax, catamenial haemoptysis and pulmonary nodules [8]. Some of these features could exist alone or in combination in some cases. The most common clinical entity is catamenial pneumothorax (73%), catamenial haemothorax (14%), catamenial haemoptysis (7%), and pulmonary nodules (6%) [9,10].

Catamenial pneumothorax is the occurrence of spontaneous and recurrent pneumothorax within 3 days of onset of menstruation [1]. The symptoms experienced by patients include cough, shortness of breath and pleuritic chest pain [8]. Catamenial haemothorax is characterized by acute chest pain and dyspnea, with pleural effusions ranging from 200-2000ml according to diagnostic imaging in some patients [1]. About 70% of catamenial haemothorax occurs at the right side while only 20% occurs at both sides [11].

Catamenial haemoptysis is a type of haemoptysis that occurs during menstruations due to the presence of functional parenchymal or endobronchial tissue [12]. Unlike other forms of TES, catamenial haemoptysis does not cause pleuritic chest pain, yet its symptoms can occur regularly during the patient's lifetime [1]. However, pulmonary or lung nodules are rare presentations of TES [13] They could be asymptomatic or symptomatic in patients with catamenial haemoptysis [12, 13]. Some studies have shown that lung nodules are prevalent among older women with age range of 38-39 years, unlike other clinical presentations that occur in younger ages [1].

The diagnosis of TES includes physical examinations and varying degrees of diagnostic techniques. Physical examination of a suspected patient who reports cough, dyspnea, and chest pains around her menses, could be helpful in making a diagnosis [1]. Diagnostic techniques useful in the diagnosis of TES are chest radiographs (chest x-ray), computed tomography (CT) scan, magnetic resonance imaging (MRI) and bronchoscopy [1]. Chest x-ray and CT scan are useful for diagnosing pneumothorax and haemothorax [8]. Chest MRI is useful in diagnosing diaphragmatic endometriosis, especially where CT scan was inconclusive [8,11]. Bronchoscopy as a diagnostic technique in TES is somewhat limited because major pathological characteristics of TES are present in the peripheral lungs [1]. However, the technique helps in identifying bleeding segments of the lung in catamenial haemoptysis [7]. Bronchoscopy during menstruation also improves the chances of accurately confirming the presence of endobronchial endometrial tissue [14].

Conservative and surgical treatment are both useful in the management of TES. Hormonal therapy involves the use of anti-gonadotrophic agents as non-surgical intervention, while video-assisted thorascopic surgery (VATS) is the major surgical approach [1,11]. Anti-gonadotrophic drugs cause a reduction in endogenous oestrogen production thereby weakening the endometrial tissue [1,7]. Example of such agents include periodic or routine oral contraceptive pills, dienogest, danazol, and cyproterone acetate [15,16]. Surgical approach is required for patients who do not show any improvements with hormonal therapy [1]. VATS is the major surgical intervention for TES, as it is both diagnostic and therapeutic [11]. This procedure provides an opportunity for the surgeon to confirm the presence of blebs, air leakage and other clinical presentations of TES on visceral and parietal pleurae, as well as the diaphragm [11]. Although, several studies have shown VATS to be superior to hormonal therapy alone, however the combination of both have been the most effective in curbing the recurrence of TES [1,17]. There is limited literature on the management outcomes of TES, hence the

study sought to evaluate the outcome of interventions for TES at our hospital and to create awareness regarding this rare condition.

2. MATERIALS AND METHODS

2.1 Study Site

This study was conducted at the cardiothoracic and vascular surgery unit of the University of Port Harcourt Teaching Hospital (UPTH). The University of Port Harcourt Teaching Hospital is a 988-bed hospital in Alakahia, in Obio-Akpor Local Government Area of Rivers state. It is a tertiary hospital that serves as a referral centre for all levels of healthcare in Rivers state and other neighbouring states including Bayelsa, Imo and Abia. Every week, the cardiothoracic surgery gynaecology clinic runs on Mondays, and each clinic session is led by a team of consultants. Patients with clinical and histologic diagnosis of thoracic endometriosis are evaluated at the clinic and the accident and emergency ward before they are admitted into the surgical wards for subsequent management.

2.2 Methods

This is a prospective cross-sectional study of 14 patients with clinical and histologic diagnosis of thoracic endometriosis who were managed at the University of Port Harcourt Teaching Hospital between August 1, 2017, and July 31, 2023. After obtaining informed consent, the patients' information was collected using a data collection tool and data was entered into a Microsoft excel spreadsheet in sequential order. Data obtained socio-demographic characteristics, clinical presentation, type of intervention, and evidence of recurrence of chest symptoms. Each patient was given a unique identity to ensure anonymity and ease of identification. The data collection tool was checked for accuracy and completeness for filing them.

2.3 Data Analysis

The Statistical Package for Social Sciences (SPSS) version 25 was used to analyze the data. Descriptive statistics are presented as frequencies and percentages. Results are presented in tables and figures.

3. RESULTS

The age range was 20-44 years, with 40-44 years being the most frequent (42.86%) age group, 11 (78.57%) were married while 3 (21.43%) were single. This is shown in Table 1. Table 2 shows that 10 (71.43%) of the patients had clinical diagnosis of TES while 4 (28.57%) had histologic diagnosis of

TES. Of the 14 patients, 3 (21.43%) had both abdominal endometriosis and features of thoracic endometriosis, 9 (64.23%) had pneumothorax, 3 (21.43%) had haemopneumothorax, while 2 (14.29%) had cyclical haemoptysis and haemothorax. In addition to some of these symptoms, 4 (28.57%) of the patients had thoracic endometriotic nodules, 6 (42.86%) had cyclical chest pain, while all the married patients, 11 (78.57%), had primary infertility.

Figure 1 shows the interventions received by the patients. Twelve (85.7%) of the patients had CTTD with chemical pleurodesis while four had thoracotomy, decortication, closure of right hemidiaphragmatic openings, bleb, and nodules resection with chemical pleurodesis. All the patients had hormonal therapy using luteinizing hormone-releasing hormone (LHRH) analogues. The patients have been followed up for a period ranging from 1 to 6 years and symptom recurrences was observed only in two. Of the four patients that had thoracotomy, two were primarily done while two were done following recurrent pneumothorax from failed CTTD and pleurodesis.

Figure 2 is a slide showing thoracotomy for thoracic endometriosis for one of the patients that had surgical intervention, while figure 3 shows thoracic endometriosis nodule during a surgical procedure. Figure 4 displays the outcome after surgical intervention and postoperative follow up. For recurrence of symptoms, only two cases of recurrent catamenial pneumothorax were reported during the period of follow-up which ranged between 1 to 6 years.

Table 1: Demographic Characteristics

Variables	Frequency (n)	Percent (%)
Age range (years)		
20-24	1	7.14
25-29	2	14.29

30-34	2	14.29
35-39	3	21.43
40-44	6	42.86
Marital Status		
Single	3	21.43
Married	11	78.57

Table 2: Clinical presentation

Parameters	Frequency	Percent (%)
Cyclical chest pain	6	42.86
Hemoptysis	2	14.29
Hemothorax	2	14.29
Primary infertility	11	78.57
Pneumothorax	9	64.29
Hemopneumothorax	3	21.43
Recurrent pneumothorax	2	14.29
Endometriotic Nodules	4	28.57

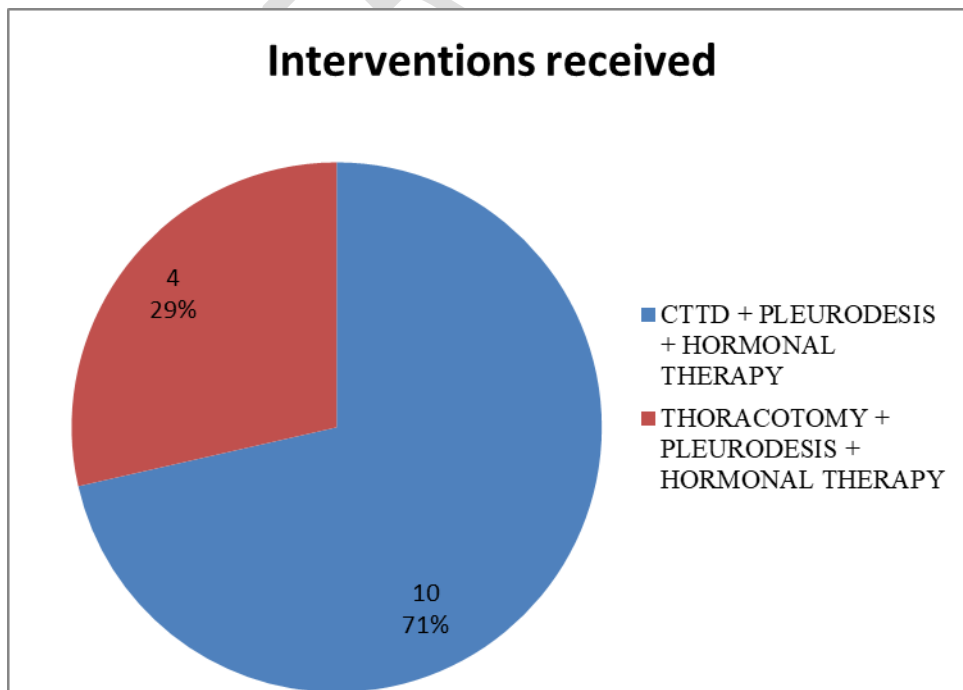


Fig 1: Type of intervention received (n=14)

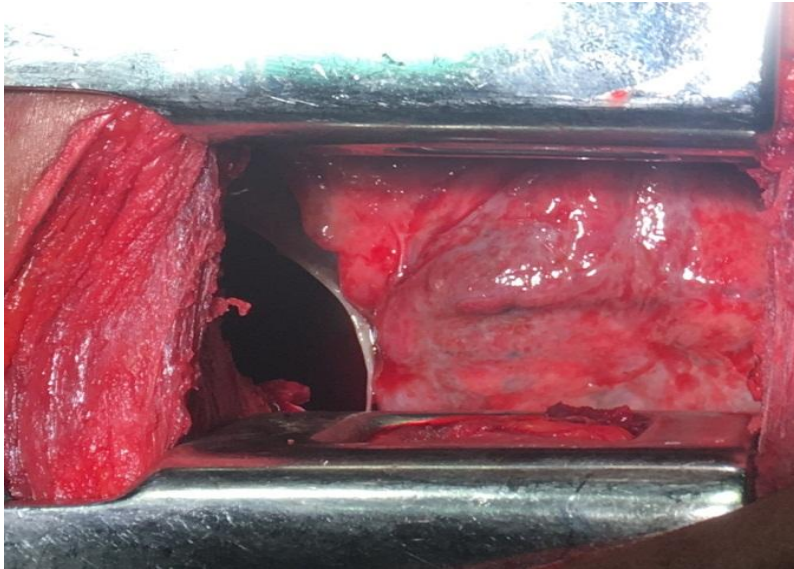


Fig 2: Thoracotomy for thoracic endometriosis

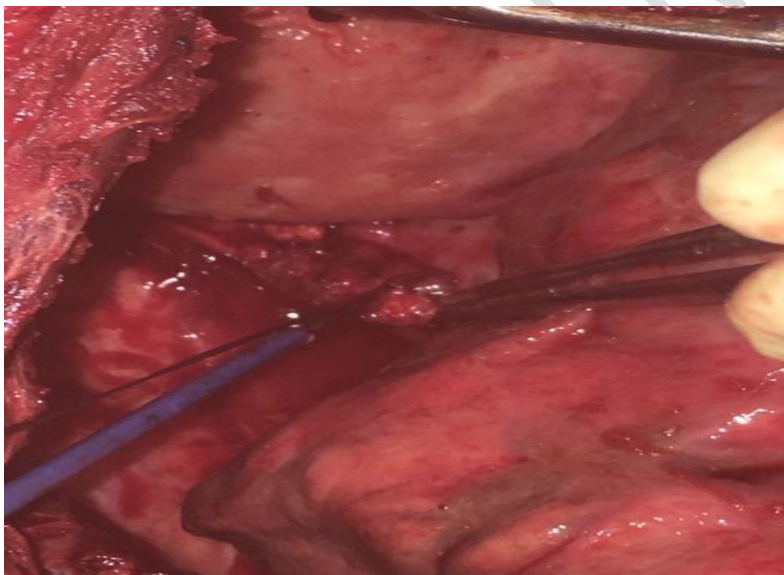


Fig 3: Thoracic endometriosis showing thoracic endometriosis nodule

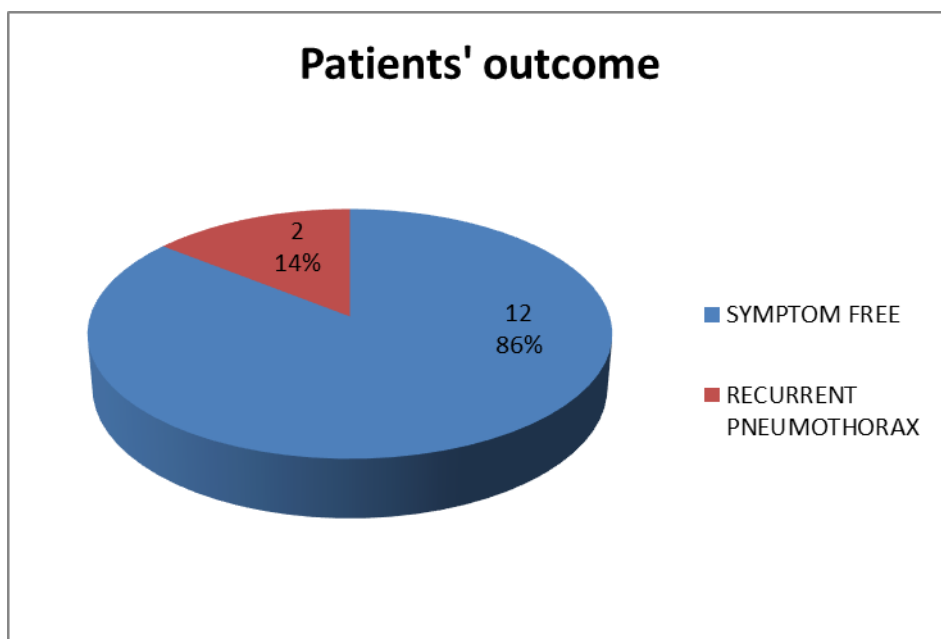


Fig 4: Outcome after surgical intervention

4. DISCUSSION

In this study, age range of the patients was from 20-44 years. This finding was at variance with two large retrospective studies that reported an age range of 30-35 years [1]. This disparity which could be due to difference in study location and population. However, the median age observed in this study was 32 years, which is similar to that of Robbio et al [3] who reported a median age of 30 years for 31 patients that were managed for TES, while Duyos et al [19] reported a median age of 34.5 years in a retrospective study done in Spain.

Regarding clinical presentation, pneumothorax was the most prevalent. This is in accordance with several studies by Joseph and Sahn [9], Channabasavaiah et al [13] and Duyos et al [19] who had reported pneumothorax as the most frequent clinical manifestation. Similarly, this study observed chest pain as the second most frequent manifestation of TES as about 42.86% of the patients had chest pain. This is not surprising because chest pain has been attributed to all clinical entities of TES, except for haemoptysis. This is like the findings of Nezhat et al [20] who reported that 40% of patients

treated for thoracic endometriosis presented with chest pains. Furthermore, primary infertility was reported in 11 of the patients, with one of them having a history of successful invitro fertilization (IVF). The connection between infertility and TES is not far-fetched because endometriosis is originally associated with pelvic structures which includes the reproductive organs. The least occurring clinical manifestation was haemothorax and haemoptysis, which occurred in two patients.

Ten of the patients had CTTD, pleurodesis and hormonal therapy while four patients had thoracotomy, pleurodesis and hormonal therapy. Pleurodesis was done when daily drainage was less than 100ml and involved injecting a solution of 2g of tetracycline, 20mls of 2% Xylocaine and 20mls of injection water into the pleural space through the CTTD, the tube clamped, and patient changed positions from sitting, to supine, right lateral, prone, left lateral after every 30 minutes, with tube unclamped and removed after 12-24 hours. Those that had thoracotomy, was open postero-lateral thoracotomy, involving decortication, closure of right hemi-diaphragmatic defects, resection of blebs and endometriotic nodules, repair of air leaks and the pleurodesis done by applying the tetracycline, injection water, and lidocaine solution directly in the inner chest wall and lung surfaces. The hormonal therapy involved injection of LHRH analogue for 6 months.

The outcome of the patients in this study was quite encouraging. The patients were followed up for 1 to 6 years. There were only two recurrent pneumothorax with 12 patients being symptom free. Out of the four patients that had thoracotomy, two were done primary because of cicatrizing atelectasis while the other two were due to recurrent pneumothorax. This success rate could be attributed to proper patient selection. As evident in this study, the occurrence of TES is not that common with only 14 cases reported within a 6-year period.

5. CONCLUSION

The treatments of TES using conservative and surgical options with appropriate patient selection seem to be effective as few recurrences have been recorded even after years of follow up. This point to a quite encouraging outcome in the management of thoracic endometriosis syndrome in our institution.

Consent

As per international standards or university standards, patient(s) written consent has been collected and preserved by the author(s).

Ethical Approval

The study was approved by the research and ethics committee of the University of Port Harcourt Teaching Hospital.

REFERENCES

1. Azizad-Pinto P, Clarke D. Thoracic endometriosis syndrome: case report and review of the literature. *Perm J*. 2014; 18 (3):61-65.
2. Augoulea A, Lambrinouadaki I, Chrsitodoulakos G. Thoracic endometriosis syndrome. *Respiration*. 2008; 75(1):113-119.
3. Bobbio A, Canny E, Mansuet Lupo A, Lococo F, Legras A, Magdeleinat P, et al. Thoracic Endometriosis Syndrome Other Than Pneumothorax: Clinical and Pathological Findings. *Ann Thorac Surg*. 2017; 104 (6):1865-1871.
4. Chen C, Zhai K, Tang Y, Qu W, Zu J, Ke X, et al. Thoracic endometriosis: a case report and review of the literature. *Ann Palliat Med*. 2021; 10 (3):3500-3503.
5. Maniglio P, Ricciardi E, Meli F, Vitale SG, Noventa M, Vitagliano A, et al. Catamenial pneumothorax caused by thoracic endometriosis. *Radiol Case Rep*. 2017; 13 (1):81-85.
6. Vercellini P, Abbiati A, Viganò P, Somigliana ED, Daguati R, Meroni F, et al. Asymmetry in distribution of diaphragmatic endometriotic lesions: evidence in favour of the menstrual reflux theory. *Hum Reprod*. 2007; 22:2359-2367.
7. Alifano M, Trisolini R, Cancellieri A, Regnard JF. Thoracic endometriosis: current knowledge. *Ann Thorac Surg*. 2006; 81:761-769.
8. Nezhat C, Lindheim SR, Backhus L, Vu M, Vang N, Nezhat A, et al. Thoracic Endometriosis Syndrome: A Review of Diagnosis and Management. *J Soc Laparoendo Surg*. 2019; 23(3): e2019.00029.
9. Joseph J, Sahn SA. Thoracic endometriosis syndrome: new observations from an analysis of 110 cases. *Am J Med*. 1996; 100 (2):164-170.
10. Rousset P, Rousset-Jablonski C, Alifano M, Mansuet-Lupo A, Buy JN, Revel MP. Thoracic endometriosis syndrome: CT and MRI features. *Clin Radiol*. 2014; 69 (3):323-330.
11. Velagapudi RK, Egan JP. Thoracic Endometriosis: a Clinical Review and Update of Current and Evolving Diagnostic and Therapeutic Techniques. *Curr Pulmonol Rep*. 2021; 10:22-29.

12. Kim CJ, Nam HS, Lee CY, Yum HK, Yang SH, Seo KH, et al. Catamenial hemoptysis: a Nationwide analysis in Korea. *Respiration*. 2010; 79 (4):296-301.
13. Channabasavaiah AD, Joseph JV. Thoracic endometriosis. *Medicine (Baltimore)*. 2010; 89 (3):183-188.
14. Wang HC, Kuo PH, Kuo SH, Luh KT. Catamenial hemoptysis from tracheobronchial endometriosis. *Chest*. 2000; 118 (4):1205-1208.
15. Fukuda S, Hirata T, Neriishi K, Nakazawa A, Takamura M, Izumi G, et al. Thoracic endometriosis syndrome: comparison between catamenial pneumothorax or endometriosis-related pneumothorax and catamenial hemoptysis. *Eur J Obstet Gynecol Reprod Biol*. 2018; 225:118-123.
16. Vercellini P, De Giorgi O, Mosconi P, Stellato G, Vicentini S, Crosignani PG. Cyproterone acetate versus a continuous monophasic oral contraceptive in the treatment of recurrent pelvic pain after conservative surgery for symptomatic endometriosis. *Fertil Steril*. 2002; 77 (1):52-61.
17. Leong AC, Coonar AS, Lang-Lazdunski L. Catamenial pneumothorax: surgical repair of the diaphragm and hormone treatment. *Ann R Coll Surg Engl*. 2006; 88 (6):547-549.
18. Fukunaga M. Paratesticular endometriosis in a man with a prolonged hormonal therapy for prostatic carcinoma. *Pathol Res Pract*. 2012; 208 (1): 59-61.
19. Duyos I, López-Carrasco A, Hernández A, Zapardiel I, de Santiago J. Management of thoracic endometriosis: single institution experience. *Eur J Obstet Gynecol Reprod Biol*. 2014; 178:56-59.
20. Nezhat C, Main J, Paka C, Nezhat A, Beygui RE. Multidisciplinary treatment for thoracic and abdominopelvic endometriosis. *J Soc Laparoendo Surg*. 2014; 18 (3): e2014.00312