

IMPACT OF RING IMPLANT SURGERIES ON THE CORNEAL TRANSPLANT QUEUE AT A REFERENCE UNIVERSITY HOSPITAL IN THE STATE OF PARÁ

ABSTRACT

Keratoconus is a progressive non-inflammatory ectatic dystrophy, characterised by thinning and curving of the cornea, with central or paracentral conical protrusion, which occurs due to a biomechanical failure of the corneal stroma that is no longer able to resist the internal and external pressures exerted. The objective of the study was to analyse the positive impact of performing ring implant surgeries on patients on the corneal transplant waiting list, at the Bettina Ferro de Souza University Hospital (HUBFS), in 2023. Of the 87 intrastromal ring implants performed in 2023, 6 patients were excluded due to lack of complete data to carry out the evaluation of this work, using the total number of patients for this research 81 (100%). It was found that 89% of patients showed an improvement in corrected visual acuity after ring implantation, with approximately half reaching 100% of their visual range, providing a visual acuity of 1.0. This study showed that of the 14 patients enrolled for corneal transplantation with keratoconus who also had an indication for ring implantation, only 4 still required corneal transplantation after the procedure. In this sphere, it was evident that the patients had an improvement in visual acuity, symptoms and postponed or canceled the corneal transplant. However, more research is needed in this field, in order to obtain advances that make this procedure even safer, minimizing the risks inherent to its placement, with a view to improving the patient's quality of life.

Keyword: keratoconus, cornea, transplant.

INTRODUCTION

Keratoconus, a non-inflammatory ectatic dystrophy, represents a significant challenge in contemporary ophthalmology, requiring advanced therapeutic interventions to preserve patients' vision and quality of life (LOPES *et al.*, 2015). Characterised by thinning and buckling of the cornea, this pathological condition imposes a progressive conical curvature, compromising

visual acuity and accentuating the need for corneal transplantation in advanced stages of the disease (AMBRÓSIO JR. *et al.*, 2012).

Keratoconus represents one of the main indications for corneal transplantation, with a significant proportion of patients dependent on this procedure to restore vision compromised by the progression of corneal ectasia (ESPERIDIÃO *et al.*, 2021).

However, the limited availability of donors and the complications associated with transplants emphasise the importance of less invasive and more accessible therapeutic approaches, such as intra-stromal ring implantation (GHOSHEH *et al.*, 2008).

And an analysis evaluating the impact of ring implant surgeries on the corneal transplant queue revealed a substantial reduction in the need for transplants in patients with keratoconus, indicating a significant change in the therapeutic paradigm for this ophthalmological condition (SANDES *et al.*, 2018).

The increasing incidence of keratoconus and the consequent demand for corneal transplants highlight the importance of innovative and effective therapeutic strategies to contain the progression of the disease and reduce dependence on invasive procedures such as transplantation (KAUFMAN *et al.*, 2000).

In this context, intrastromal ring implant surgeries emerge as a promising alternative, offering not only the stabilization of corneal ectasia, but also a substantial improvement in visual acuity in patients with keratoconus (ALZHRANI *et al.*, 2017).

Early identification of patients with an indication for ring implantation can result in better visual outcomes and a significant reduction in the progression of corneal ectasia, thus minimising the need for corneal transplants in advanced stages of the disease (KYMIONIS *et al.*, 2009).

That said, current ophthalmological literature recognises the fundamental role of the intrastromal ring implant in the management of keratoconus, highlighting its potential benefits in stabilising the cornea and preserving visual acuity in the long term (ARAUJO, 2018).

The implementation of standardised protocols and evidence-based clinical guidelines can facilitate patient access to effective therapeutic

interventions and promote more efficient management of available ophthalmic resources (Kaufman *et al.*, 2000).

The Bettina Ferro de Souza University Hospital (HUBFS), located in the state of Pará, plays a crucial role in the multidisciplinary approach to keratoconus and in providing specialised ophthalmic care to the local population. Against this backdrop, this study set out to analyse the positive impact of ring implant surgeries on the corneal transplant queue at this reference institution in 2023.

Therefore, this research attempted to demonstrate the significant impact of ring implant surgeries on the corneal transplant queue at the Bettina Ferro de Souza University Hospital, highlighting the effectiveness and safety of this procedure in the management of keratoconus. In addition, the results obtained here attempt to provide a solid basis for the adoption of less invasive and more accessible therapeutic approaches to keratoconus, thus emphasising the importance of innovation and interdisciplinary collaboration in contemporary ophthalmology.

MATERIALS AND METHODS

Research location

The research was carried out at the Bettina de Souza Ferro University Hospital, after authorisation from the hospital's management and approval from the UFPA Human Research Ethics Committee (CEP-UFPA).

Ethical precepts

This study was carried out in compliance with the rules for research involving human beings (CNS Res. 466/12) of the National Health Council after authorisation of the project by the director of the university hospital, acceptance by the supervisor and approval by the UFPA Human Research Ethics Committee.

Type of study and sample

The project is characterised as an analytical and descriptive, observational and cross-sectional study, based on data from the medical

records of the patients in question. Using a standardised form drawn up by the project's authors. Using a standard form prepared by the project authors, which contained epidemiological data (initials of name, sex, age), eye that underwent the surgical procedure, time since diagnosis of keratoconus, symptoms related to the disease), visual acuity before and after the procedure surgery, complications related to the surgical procedure, how many patients were removed from the corneal transplant list after the surgical procedure. The patients were followed up in the consultation prior to the surgical procedure and the follow-up consultation after 3 months of surgery, thanks for the following reasons.

Inclusion and exclusion criteria

This study included the medical records of keratoconus patients who underwent intra-stromal ring implantation at Bettina Hospital in the cornea department in 2023. Patients of both sexes, aged between 18 and 60, were also included. At the same time, the exclusion criteria were the observation of patient records that were filled in incorrectly or that did not provide information on all the variables to be analysed.

Data storage, consolidation and analysis

The data collected was stored in databases and later subjected to comparative statistical analysis. The results were compared with those found in the literature on the subject.

According to the nature of the variables, descriptive statistical analysis was applied and the percentage values of the analysed data were reported. The Chi-square test was used to statistically analyse the differences between the proportions, with a level of α : 0.05 (5%), using the BioEstat 5.0 software. $p < 0.05$ was accepted as a significant difference.

RESULTS

Epidemiological Profile

Of the 87 intra-stromal ring implants performed in 2023, 6 patients were excluded due to a lack of complete data to carry out the evaluation in this study, and 81 patients were included in the study (100%). Table 1 shows the distribution of patients in terms of sociodemographic characteristics. The majority of patients, 45/81 (55.6%), were male, and 36 were female (44.4%). In terms of age, there was a predominance of patients aged 23-26 (40.7%), followed by 27-31 (34.6%).

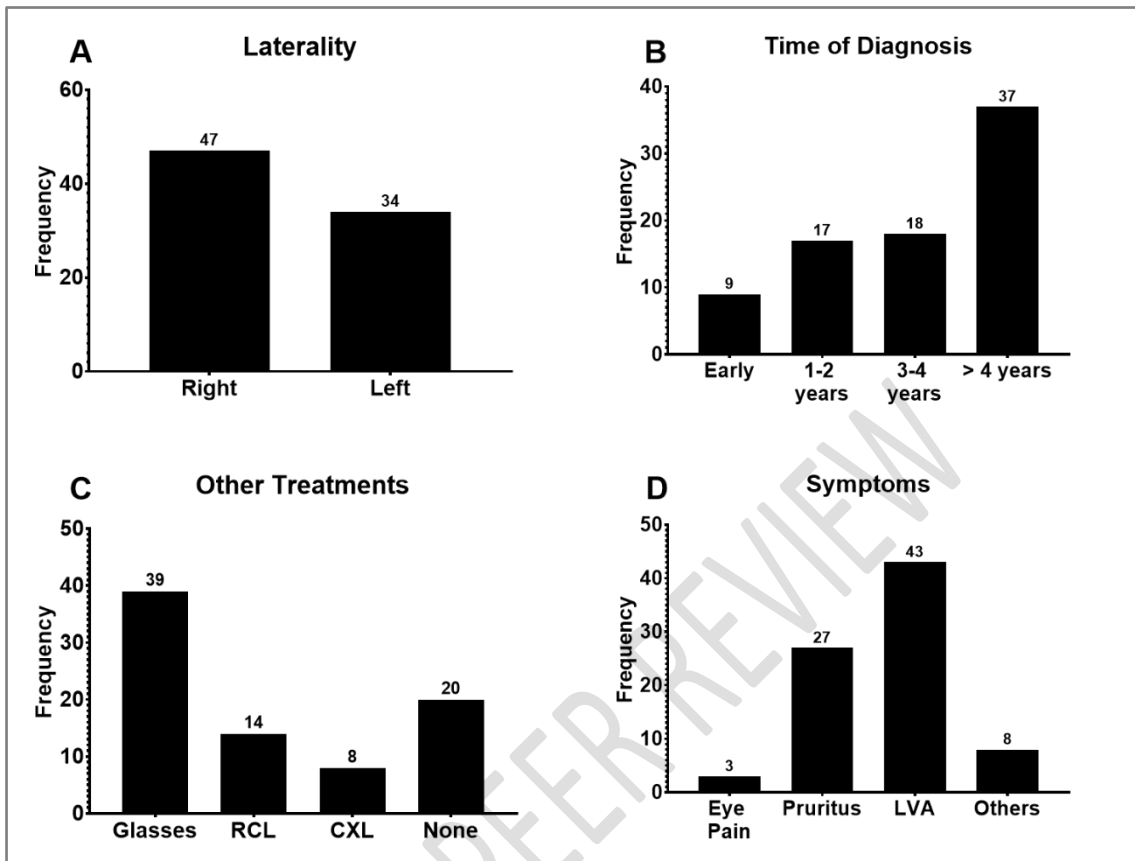
Table 1 - Sociodemographic characteristics and laterality of patients undergoing intra-stromal ring implant surgery.

Variable	Frequency	Percentage
Sex		
Male	45	55,6
Female	36	44,4
Age group		
18-22 Years	13	16,0
23-26 Years	33	40,7
27-31 Years	28	34,6
32-35 Years	7	8,6

The percentages are relative to the total number of patients (n=81).

As for the laterality of the eyes undergoing implantation, there was a predominance of the right eye (47/81, 58%), followed by the left eye (42%, Figure 1, A). As for the time of diagnosis of keratoconus, the majority (37/81, 45.7%) of patients had been diagnosed for more than 4 years, followed by 22.2% with a diagnosis of 3-4 years, and 21% with a diagnosis of around 1-2 years (Figure 1, B). As for other ophthalmological treatments before the ring implant, 48.1% (39/81) had tried glasses, followed by 24.7% who had no previous treatment, 17.3% with rigid contact lenses and 9.9% who had crosslinking (Figure 1, C). With regard to the patients' symptoms, 53.1% (43/81) reported low visual acuity, 33.3% pruritus and 9.9% other symptoms, such as a sensation of sand, tearing, among others (Figure 1, D).

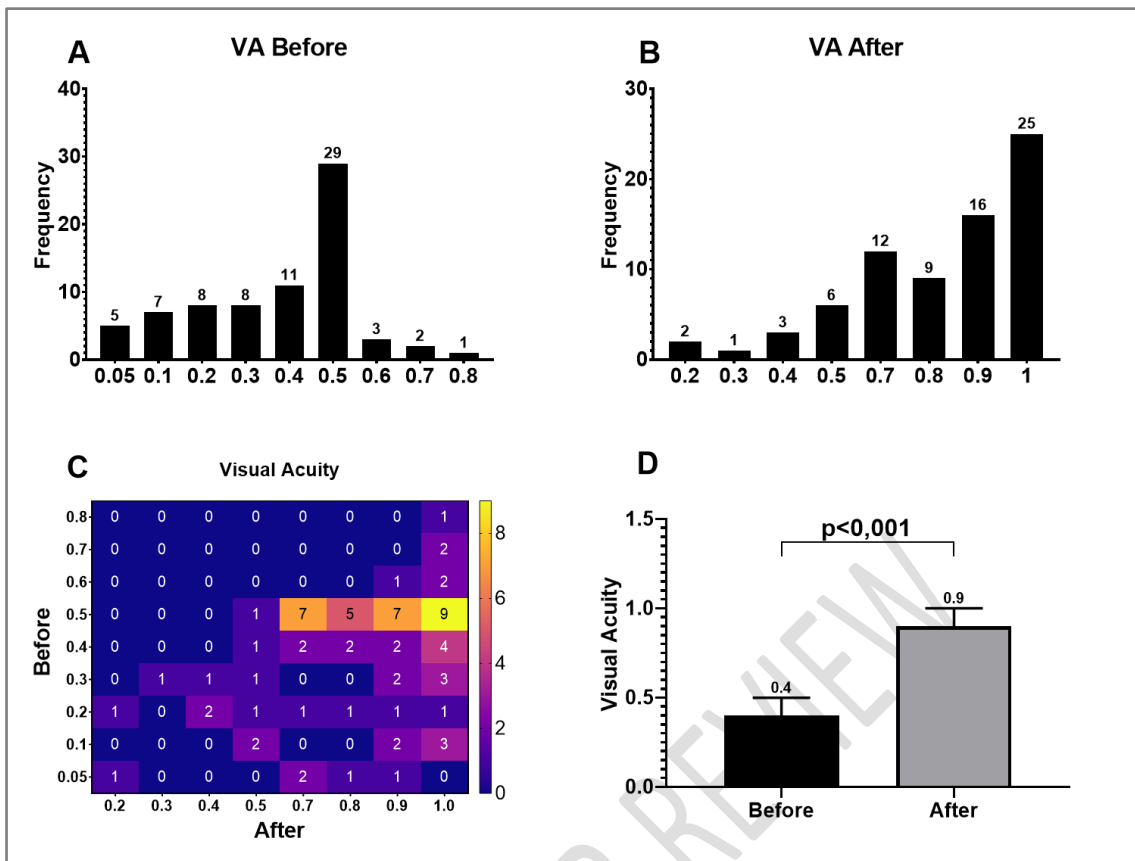
Figure 1 - Clinical characteristics of patients undergoing intra-stromal ring implant surgery.



Visual Acuity

Before surgery, of the 74 patients who underwent the procedure, 91.9% had visual acuity up to a maximum of 0.5, and a large proportion (29/74, 39.2%) had acuity of 0.5 (Figure 2, A). After the procedure, 83.8% (62/74) had VA above 0.6 (Figure 2, B). The heatmap in Figure 2 summarises the evolution of the patients' visual acuity as a result of the procedure (Figure 2, C). For example, 9 patients (12.2% of 74) had a VA of 0.5 before and 1.0 afterwards. Overall, the median VA in the sample was 0.4 before and increased to 0.9 after, a statistically significant increase ($p < 0.001$, Figure 2, D).

Figure 2 - Visual acuity before and after intra-stromal ring implant surgery.

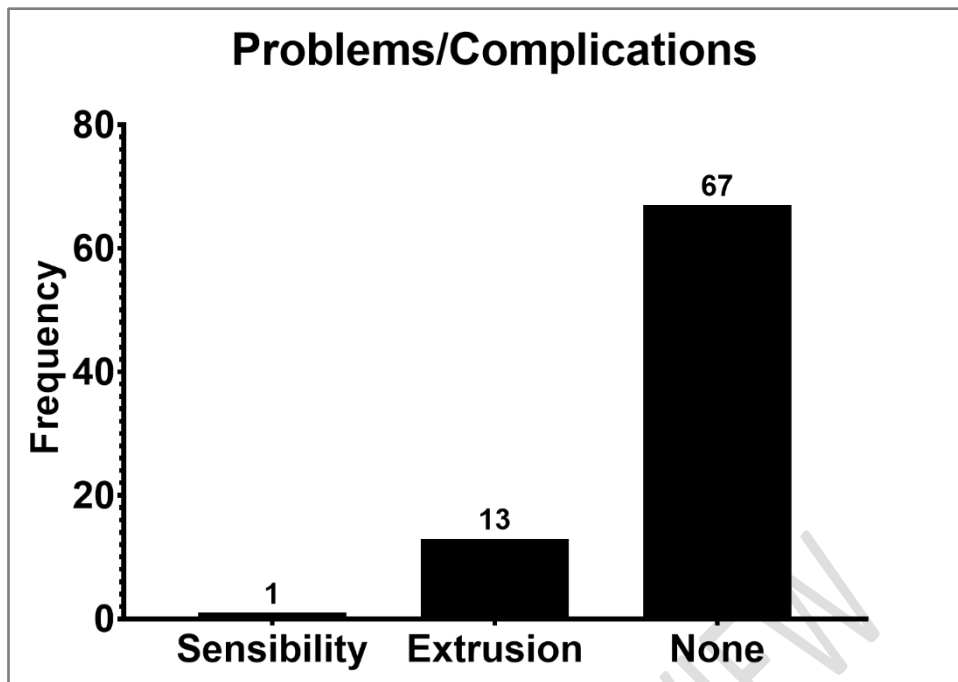


The Wilcoxon T-test was used to compare the VA before and after.

Problems or complications with ring implantation

Of the 81 patients surveyed, 14 patients (17.3%) had some kind of problem/complication with the ring implant, with 1 patient not tolerating the implant and 13 patients having extrusion (Figure 3). Of the patients who had extrusion, 10 (76.9%) re-implanted without any new problems.

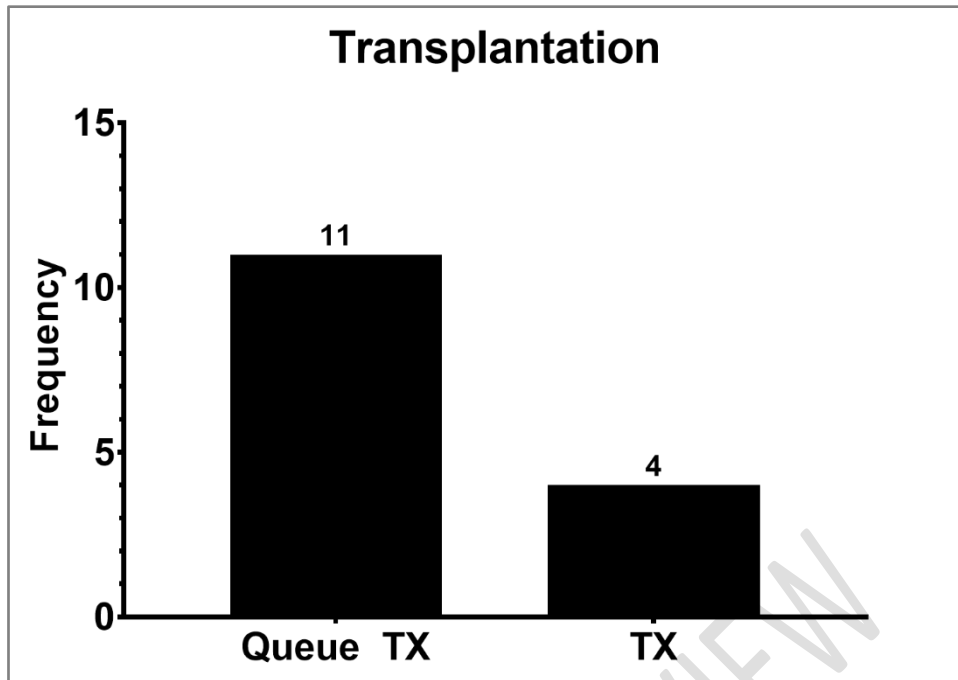
Figure 3 - Problems/complications arising from intra-stromal ring implantation.



Cornea transplant queue

Figure 4 shows the impact on reducing the need for corneal transplantation, with 11 patients (13.6%) being enrolled, and only 4 patients requiring corneal transplantation even after ring implantation (5%, 95%CI = 1.4%-12.2%). However, it is not possible to relate this real impact on the reduction in the corneal transplant queue in patients with ring implantation to absolute data, because according to the literature studied and practised at the hospital in question, the step prior to corneal transplantation would be intrastromal ring implantation.

Figure 4 - Corneal transplant queue and patients who remained in the queue.



DISCUSSION

Keratoconus is a disease of unknown etiology that causes the cornea to acquire a conical shape that generates progressive irregular astigmatism and consequent deterioration in visual acuity (SOUZA, 2019).

It is considered to be a multifactorial disease, involving genetic, environmental and behavioural factors. Keratoconus can manifest asymptotically until puberty, with the onset of symptoms characterised by decreased visual acuity, myopia, progressive irregular astigmatism and, in the most severe cases, the need for corneal transplantation. Despite several available studies, there is still no defined aetiology, and it affects both genders and all ethnicities (ALZHRANI, 2017).

Although most of the researched literature does not define a prevalent gender, this study showed a prevalence of males (55%), which is corroborated by the majority of studies, which show a slight prevalence of males or no significant difference between the sexes, which may be correlated with the aetiopathogenesis of ocular allergy in these patients.

The studies found do not show a predominance of laterality, however, in this study, 58% of ring implants were found in the right eye, given that it is a pathology characterised by affecting 85% of both eyes, but with marked asymmetry on both sides.

As for the age of those studied, most of the studies found reaffirm that the disease begins at puberty, but due to the variation in severity and definitive diagnosis, the actual onset of the disease has not yet been defined, but the marked progression of the disease in the post-puberty period is known.

Thus, the prevalence of ring implantation in this study was of patients aged 23-26 years (41%), followed by 27-31 years (34%), these data are corroborated by studies such as Fernández, *et al.* (2021), Lyra, *et al.*(2017), Renesto, *et al.* (2019), given that the inclusion criterion for patients was 18-60 years, the vast majority of patients were in the 18-35 age range, showing a similar range to most of the studies found, as this is the period of worsening visual acuity, when seeking treatment to improve visual acuity or stabilise the disease.

This is reinforced by the fact that almost 50% of the patients studied were diagnosed more than 4 years ago. Their main complaint was low visual acuity, followed by pruritus, corroborating the core of its pathophysiology in the disorganisation of the corneal structure.

Thus, the clinical indication for implantation of the intra-stromal ring can normally be made in cases where the keratoconus has high corneal distortion, intolerance to the use of contact lenses or inefficiency of the results of correction with glasses or contact lenses, leading to the suggestion of the need for surgical intervention. Surgical intervention with the ring has no curative role for keratoconus, but for some authors it has the ability to contain the progressive evolution of the disease and also not fully correct refractory problems (ESPERIDIÃO, *et al.*, 2021).

In this study, the vast majority of patients had already tried glasses to correct their vision, as well as rigid contact lenses, but without success in correcting their visual acuity, and opted for the intra-stromal ring implant in search of better results.

Thus, from the point of view of visual acuity, there is still a lot of debate, as the main aim of intra-stromal ring implantation would be to reduce corneal curvature and asymmetry, although this could improve the visual acuity of these patients. Thus, the vast majority of studies correlate it with improved visual acuity.

This study found that 89 per cent of patients showed an improvement in corrected visual acuity after implantation of the ring, with approximately half reaching 100 per cent of their visual range, giving a visual acuity of 1.0.

Similar data was found by Fernández, *et al.* (2021), Lyra, *et al.* (2017), McIntock *et al.* (2021), Moscovici, *et al.* (2021), Sandes, *et al.*(2018), Torquetti, *et*

al.(2018), reaffirming the improvement in astigmatism. As Costa, *et al.* (2021), Fernández, *et al.* (2021), Moscovici, *et al.*(2021), Warrack, *et al.*(2020) showed in their studies, the progression of the disease decreased.

Costa, *et al.* (2021) showed that the average visual acuity improved significantly over 5 years. Spherical equivalent, refractive cylinder and all topography values decreased significantly postoperatively. There was no regression in any visual or topographic parameter. Both younger and older patients showed similar and stable results up to the 5-year visit. According to Fernandez-Vegacuetto, *et al.* (2019), these results remain stable over 3 years of follow-up.

In Lisa's (2017) study, there was a significant improvement in the visual parameters of keratoconus patients, since the disease progresses over time and can lead to total blindness, so it can be concluded that the ring implant brings several benefits to keratoconus patients, whether in terms of improving visual acuity, refractive levels and corneal topography, as well as preventing progression and even interrupting the development of the disease in the long term.

However, some studies, such as Araujo's (2018), which have followed up contact lens intolerant patients over the long term, have shown that keratoconus stabilises after implantation of the ring, but their study largely included patients with keratoconus that had already stabilised, so they could not conclude that the ring has the effect of stabilising or slowing down the progression of ectasia based on these data.

Similarly, as explained by the majority of the ophthalmological literature researched, crosslinking can be a surgical alternative for stabilising the disease, according to its indications, although this procedure does not make corneal ring implantation unfeasible. As shown by McIntoc *et al.* (2021), the insertion of rings in keratoconic eyes with a history of previous crosslinking results in significant improvements in visual, refractive and tomographic results, the same was seen in the 8 patients (10%) who had already undergone previous crosslinking, all of whom had improved visual acuity.

That's why further research into stabilising the disease and improving visual acuity is of the utmost importance, in order to achieve advances that will make this intra-stromal ring implant procedure even safer, minimising the risks inherent in its placement, with a view to improving the patient's quality of life.

In this sphere, the vast majority of the literature studied showed an improvement in visual acuity and a reduction in the progression of the disease, so intra-stromal ring

implantation is taking on a new scenario in the treatment of keratoconus, with a view to its increasingly earlier implantation, clearly respecting its correct indications.

However, although corneal ring implantation is a simple method, it is not free of complications, so in this study only one patient did not tolerate the ring implant and had to have the ring removed without a new implant, and 13 patients had extrusion of the ring, but with subsequent repositioning without further complications, demonstrating a method with low complications.

Similar data was found by Sadoughi, *et al.* (2017), in which the implantation of a Ferrara-type ring led to 10% of cases with complaints such as mild postoperative discomfort, photophobia and late acuity oscillation.

When it comes to very advanced cases of keratoconus, there is no consensus about the implant and its benefits. However, there are several advantages, such as the reversibility of the procedure, making it possible to remove, exchange and adjust the implant according to need, not causing severe damage to the patient's cornea and being one of the most effective procedures in the vast majority of cases, with positive impacts on patients' quality of life (SOUSA & TORRÃO LMG, 2019).

Therefore, as intra-stromal ring implantation is a surgical procedure, there is a rare possibility that it may cause some problems, which should not be ruled out, such as: need for extrusion of the ring segment at ocular level, predisposition of the patient to infections such as keratitis, focal oedema, ring migrations, corneal neovascularisation, blurred cornea, its implantation can cause perforations in up to 5% of eyes, especially in thin and/or steep corneas in the short term and in the long term by the act of rubbing the eyes (MUKHTAR & AMBATI, 2017).

In this way, despite being a surgical treatment, ring implantation benefits from being a less invasive and reversible treatment, showing a direct interference in relation to the realisation of corneal transplantation in patients with keratoconus, as it provides good and promising results, either delaying transplantation or not requiring it.

According to the literature consulted, such as a study by Moussa (2017), only 20% of keratoconus cases progress to the stage of corneal transplantation. According to Cattani (2002), the main indications for corneal transplantation in Brazil are keratoconus, bullous keratopathy, retransplantation and corneal dystrophies. The indications for corneal transplantation have changed over the years in the United States. Before the 1970s, the main indication for transplantation was corneal scarring. In the 1970s, with the increase in cataract surgeries, the indications for bullous keratoplasty

also increased. According to Calix Netto (2006), the indications for transplantation in Brazil vary in different regions of the country, with keratoconus being the main indication for transplantation in the state of São Paulo and in the majority of Brazilian states.

In this scenario, according to the Brazilian Organ Transplant Association, keratoconus is one of the main causes of almost 13,000 corneal transplants carried out in Brazil in 2020 (SESPA, 2020).

Thus, this study showed that of the 14 patients enrolled for corneal transplantation with keratoconus who also had an indication for ring implantation, only 4 still needed corneal transplantation after the procedure.

Although the number is still small, but it is relevant, in a less invasive attempt, which would be ring implantation, it is known that in extreme cases of keratoconus and selected cases, corneal transplantation is the only viable alternative.

However, although corneal transplantation is the oldest, most common and most successful form of tissue transplantation, due to the immunological privilege of the anterior chamber, rejection continues to be the biggest cause of failure in corneal transplants, even considering non-vascularised corneas such as keratoconus (Mascaro *et al.*, 2007).

Although the literature reports the majority of successful cases following keratoplasty or penetrating corneal transplantation, the outcome of this treatment is not without its complications, which can include graft rejection, intraocular damage (iris, lens), post-operative astigmatism and recurrence of keratoconus. However, these complications have been significantly reduced in recent years due to improvements in techniques.

Much remains to be studied in relation to keratoconus, and it is hoped that in the future, new research will help to reverse the damage caused by keratoconus. In this way, we can improve visual acuity in those with poor refractive quality, thus reducing the need for penetrating keratoplasty in keratoconus.

CONCLUSION

This study sought to establish a direct and indirect relationship between intrastromal corneal ring implantation in patients with keratoconus who did not require or postponed corneal transplantation in their treatment. In this way, it was observed that much still needs to be studied, from its etiopathogenesis, as well as the basis of its

treatment, but the good results of corneal ring implantation in benefiting these patients are undeniable.

Furthermore, these patients not only benefit from not having to undergo a more invasive surgery, which is corneal transplantation, but the vast majority have had a significant improvement in their visual acuity.

In this way, it was evident that the patients had an improvement in visual acuity, symptoms and postponed or canceled the corneal transplant. However, more research is needed in this field, in order to obtain advances that make this procedure even safer, minimizing the risks inherent to its placement, with a view to improving the patient's quality of life.

REFERENCES

1. ALZHRANI K, *et al.* Corneal clarity measurements in healthy volunteers across different age groups. *Medicine*, 2017; 96(46): 1-6.
2. KEMPURAJ D; MOHAN RR. Autophagy in Extracellular Matrix and Wound Healing Modulation in the Cornea. *Biomedicines*, 2022; 10(339): 1-20.
3. NEJAD TM; FOSTER C; GONGAL D. Finite element modelling of cornea mechanics: a review. *ArqBras Oftalmol.* 2014 Jan-Feb;77(1):60-5
4. KANSKI JJ. *Clinical Ophthalmology*. 8th ed. Rio de Janeiro: Revinter, 2016.
5. KAUFMAN HE; BARRON BE; MCDONALD MB; KAUFMAN SC. Bacterial Keratitis. *Companion Handbook to the Cornea*. Butterworth, Heinemann, Boston, 2000, pp.91-141.
6. LOPES ACN; PINTO AGT; SOUSA BA. Keratoconus: a review. *Rev Med Saude Brasilia* 2015; 4(2):219-32
7. AMBRÓSIO JR R, *et al.* Implantation of stromal ring segments in keratoconus: results and correlations with preoperative corneal biomechanics. *RevBras Oftalmol.* 2012; 71 (2): 89-99
8. IMBORNONI LM, *et al.* Evolution of Keratoconus: From Diagnosis to Therapeutics Die evolution in der behandlung des keratokonus: von der diagnose zur therapie. *KlinMonblAugenheilkd*, 2018; 235(6): 680- 688.
9. SZCZOTKA LB; BARR JT; ZADNIK K. A summary of the findings from the Collaborative Longitudinal Evaluation of Keratoconus (CLEK) Study. CLEK StudyGroup. *Optometry.* 2001;72(9):574-84.

10. MOREIRA LB *et al.* Psychosocial aspects of patients with keratoconus. *ArqBras Oftalmol.* 2007; 70(2): 317-22.
11. ESPERIDIÃO AB, *et al.* Characteristics and clinical outcomes of patients diagnosed with keratoconus. *RevBras Oftalmol.*, 2021; 80(1): 49-55.
12. DAXER A; MAHMOUD H; VENKATESWARAN RS. Intracorneal continuous ring implantation for keratoconus: One-year followup. *J CataractRefractSurg.* 2010;36(8):1296-302.
13. DUQUE WP; REHDER JRCL; LEÇA RGC. Evaluation of the effectiveness of contact lens fitting in relation to visual improvement in patients with keratoconus. *RevBras Oftalmol.* 2012; 71 (5):313-6
14. GHOSHEH FR; CREMONA FA; RAPUANO CJ; COHEN EJ; AYRES BD; HAMMERSMITH KM, *et al.* Trends in penetrating keratoplasty in the United States 1980-2005. *Int Ophthalmol.* 2008;28(3):147-53.
15. KYMIONIS GD; KONTADAKIS GA; KOUNIS GA; PORTALIOU DM; KARAVITAKI AE; MAGARAKIS M, *et al.* Simultaneous topography-guided PRK followed by corneal collagen cross-linking for keratoconus. *J RefractSurg.* 2009;25(9):S807-11.
16. JANKOV II MR; HAFEZI F; BEKO M; IGNJATOVIC Z; DJUROVIC B; MARKOVIC V; SCHOR P. Ultra B2 - Corneal cross-linking in the treatment of keratoconus: preliminary results. *ArqBras Oftalmol.* 2008;71(6):813-8
17. RENESTRO AC; SARTORI M; CAMPOS M. Cross-linking and intra-stromal corneal ring segment. *ArqBras Oftalmol.* 2011; 74 (1): 67-74
18. PIÑERO DP; ALIO JL. Intracorneal ring segments in ectatic corneal disease - a review. *ClinExperimentOphthalmol.* 2010;38(2):154-67. Review.
19. JHANJI V; SHARMA N; VAJPAYEE RB. Management of keratoconus: current scenario. *Br J Ophthalmol.* 2010 Aug 7. [Epubaheadof print]
20. WHO. First world report on vision, 2019, accessed at www.paho.org/pt/noticias/8-10-2019-organizacao-mundial-da-saude-lanca-primeiro-relatorio-mundial-sobre-visao
21. SOUSA AA; TORRÃO LMG. Impact of the implantation of intra-stromal corneal ring segments on the quality of life of patients with keratoconus. *Rev. Soc. Port. Oft.*, 2019; 42(4): 1-13.
22. SESPA - corneal transplant queue data accessed at <http://www.saude.pa.gov.br/rede-sespa/cet/>, 2021

23. PINTO JLVT. Corneal collagen crosslinking in patients with keratoconus; preliminary results. Master's thesis. Federal University of Pernambuco - Recife, 2010.
24. MOUSSA, S; GRABNER, G; RUCKHOFER, J *et al.* Genetics in keratoconus - What is new? *The Open Ophthalmology Journal*, v. 11, p. 201-210, 2017.
25. FERNÁNDEZ J, *et al.* Evaluation of a new nomogram for Ferrara ring segment implantation in keratoconus. *Int J Ophthalmol.*, 2021; 14(9): 1371-1383
26. LYRA JM, *et al.* Tomographic Findings After Implantation of Ferrara Intrastromal Corneal Ring Segments in Keratoconus. *J Refract Surg*, 2017; 33(2): 110-115.
27. MOSCOVICI BK, *et al.* Evaluation of keratoconus progression and visual improvement after intrastromal corneal ring segments implantation: A retrospective study. *Eur J Ophthalmol*, 2021; 31(6): 3483-3489.
17. MCLINTOCK CA, *et al.* Ferrara Rings for Visual Rehabilitation in Eyes with Keratoconus and Previous Cross-Linking Using the Ferrara Ring Nomogram. *Vision (Basel)*, 2021; 5(4): 45
28. SANDES J, *et al.* Clinical outcomes after implantation of a new intrastromal corneal ring with 140-degree of arc in patients with corneal ectasia. *Int J Ophthalmol*, 2018; 11(5): 802-806.
29. TORQUETTI L, *et al.* Clinical Outcomes After Implantation of 320°-Arc Length Intrastromal Corneal Ring Segments in Keratoconus. *Cornea*, 2018; (10): 1299-1305
30. WARRAK EL, *et al.* Long-term follow up of intracorneal ring segment implantation in 932 keratoconus eyes. *J FrOphtalmol*, 2020; 43(10): 1020-1024
31. FERNÁNDEZ-VEGA-CUETO L, *et al.* Three-year follow-up of intrastromal corneal ring segment implantation in central keratoconus with regular astigmatism: 'Bow-tie' shape. *Eur J Ophthalmol*, 2020; 30(4): 643-649.
32. SADOUGHI M, *et al.* Femtosecond laser implantation of a 340-degree intrastromal corneal ring segment in keratoconus: short-term outcomes. *J Cataract Refract Surg*, 2017; 43(10): 1251-1256.
33. LISA C, *et al.* Clinical Outcomes of Sequential Intrastromal Corneal Ring Segments and an Extended Range of Vision Intraocular Lens Implantation in Patients with Keratoconus and Cataract. *J Ophthalmol.*, 2018; 2018: 8328134
34. ARAUJO BS. Progression of Keratoconus after Intrastromal Corneal Ring Implantation. Master's dissertation. Federal University of Rio Grande do Sul 2018.
35. SESPA, Keratoconus is one of the main causes of corneal transplantation in Brazil, 2020, accessed at: agenciapara.com.br

36. MASCARO VLD; SCARPI MJ; HOFLING-LIMA AL; SOUSA LB. Corneal transplantation in keratoconus: evaluation of results and complications obtained by experienced and training surgeons. *Arq Bras Oftalmol.* 2007;70(3):395-405.

UNDER PEER REVIEW