

## Original Research Article

### The incidence and correlation between age and tooth avulsion

#### **ABSTRACT**

Tooth avulsion is defined as the complete loss of a tooth or complete displacement of a tooth out of the alveolar bone socket as a result of an accident and represents a severe traumatic dental injury (TDI). Tooth avulsion mostly affects incisors in children and adolescents and is often associated with an unpredictable outcome and long-term treatment burden. After replantation of the tooth, the prognosis commonly remains uncertain. Replacement resorption or inflammatory resorption are probable adverse outcomes in comparison to the more favorable functional healing. Tooth resorption mostly appears in cases, where connective tissue between the root cementum surface and the alveolar bone, the periodontal ligament (PDL) is severely damaged.

The aim of the study is to compare the incidence and association of tooth avulsion and age. The retrospective study examined the records of 86,000 patients from January 2020 to April 2021 in which 10 patients who had tooth avulsion underwent treatment for it and who belonged to the age group 3 to 5 years, 6 to 11 years, 12 to 18 years at a university dental hospital in Chennai were shortlisted based on the inclusion and exclusion criteria. The data was then entered into SPSS software for statistical analysis. From this study, it was found that the incidence of tooth avulsion in the age group of 3 to 5-year-olds is 34%, 6 to 11-year-olds is 30% and 12 to 18-year-olds is 36%. From the present study, we can conclude that the incidence and association of tooth avulsion from the given sample is low and that tooth avulsion remains a severe dental injury with an unpredictable prognosis, which demands new fundamental research aiming to maintain or regenerate the PDL after tooth avulsion.

**Keywords:** Avulsion, Age, Innovative technology, Replantation, Resorption,

#### **INTRODUCTION**

“Tooth avulsion is defined as the complete loss of a tooth or complete displacement of a tooth out of the alveolar bone socket as a result of an accident and represents a severe traumatic dental

injury (TDI)”[1]. “Tooth avulsion mostly affects incisors in children and adolescents and is often associated with an unpredictable outcome and long-term treatment burden”[2]. “After replantation of the tooth, the prognosis commonly remains uncertain. Replacement resorption is an adverse outcome in comparison to the more favorable functional healing”[3]. “Tooth resorption occurs when the connective tissue between the root cementum surface, the alveolar bone, and periodontal ligament (PDL) is severely damaged by mechanical destruction due to TDI, the cells on the root surface get impaired during the extra-oral dry time of the avulsed tooth”[4][5]. “Therefore, the immediate rescue of the avulsed tooth, without inducing further mechanical stress or contamination is by placement in a tooth rescue box with a physiological storage medium before the PDL cells dry out is of the utmost importance”[6]. “The roots of undamaged teeth are protected against resorption by a tissue layer of unmineralized organic cementum”[7]. “Depending on the severity of the trauma, the number of surviving PDL cells, and the cementum’s ability to regenerate, the layer may no longer act as a sufficient barrier between the dental hard tissue and the adjacent bone, therefore not protecting the root from active clastic cells”[8]. “Consequently, the PDL and the root structure might be involved in bone remodeling processes and be replaced partially or completely by bone. In few cases, this will appear in only smaller demarcated areas for a limited period, leading to an acceptable prognosis. In severe cases, resorption continues, resulting in a complete loss of the root structure which leads to incidental loss of the remaining tooth crown. Bacterial contamination or infection and its associated toxins, necrotic cell debris, and mechanical stress may enhance the resorption process and lead to rapid tooth loss in most cases of inflammatory resorption”[9][10]. “The awareness of avulsed teeth in children among parents, and dentists, and have recommended the necessity of learning methods of management to enhance the prognosis of avulsed teeth”[11]. “The prognosis of an avulsed tooth relies on three important factors; extra-oral time, storage media, and root development”[12]. “Avulsion presents a challenge with regards to its proper emergency management”[13]. “The clinical outcome of the avulsed tooth is unduly compromised if adequate emergency treatment is not followed”[14]. “In a traumatic dental injury, the patient expects competent treatment from the dental practitioners”[15]. “The best practice recommendations include storage, replantation, and splinting of the tooth. While these guidelines are constantly revised by experts, data on the clinical efficacy of these treatment recommendations are sparse”[16]. This research is needed to obtain information on the amount

and kind of variation that is displayed by tooth avulsion and its association with age. It could be used to prevent further damage and collapse of the socket due to bone resorption. The aim of the study is to compare the incidence and association of tooth avulsion and age.

## **MATERIALS AND METHODS**

### **STUDY DESIGN AND SETTING:**

The retrospective study examined the records of 86,000 patients from January 2020 to April 2021 in which 10 patients who had tooth avulsion underwent treatment for it and who belonged to the age group 3 to 5 years, 6 to 11 years, 12 to 18 years at Saveetha dental college and hospital in Chennai were shortlisted based on the inclusion and exclusion criteria.

### **STUDY POPULATION**

The study population included patients who underwent treatment for tooth avulsion in a private dental college by the means of systematic sampling.

- Inclusion criteria- Patients who underwent treatment tooth avulsion
- Exclusion criteria- children below the age of 3 years and above the age of 18 years were excluded from the study.

### **DATA COLLECTION**

The data for this study was taken from the patient records from a private dental college in Chennai. A total sample of 86,000 patients was taken out of which only 10 patients who met the inclusion criteria were included in the study. These patients belonged to the age group 3 to 5 years, 6 to 11 years, 12 to 18 years. Repeated patient records and incomplete data were excluded. Data were reviewed by an external reviewer.

### **STATISTICAL ANALYSIS**

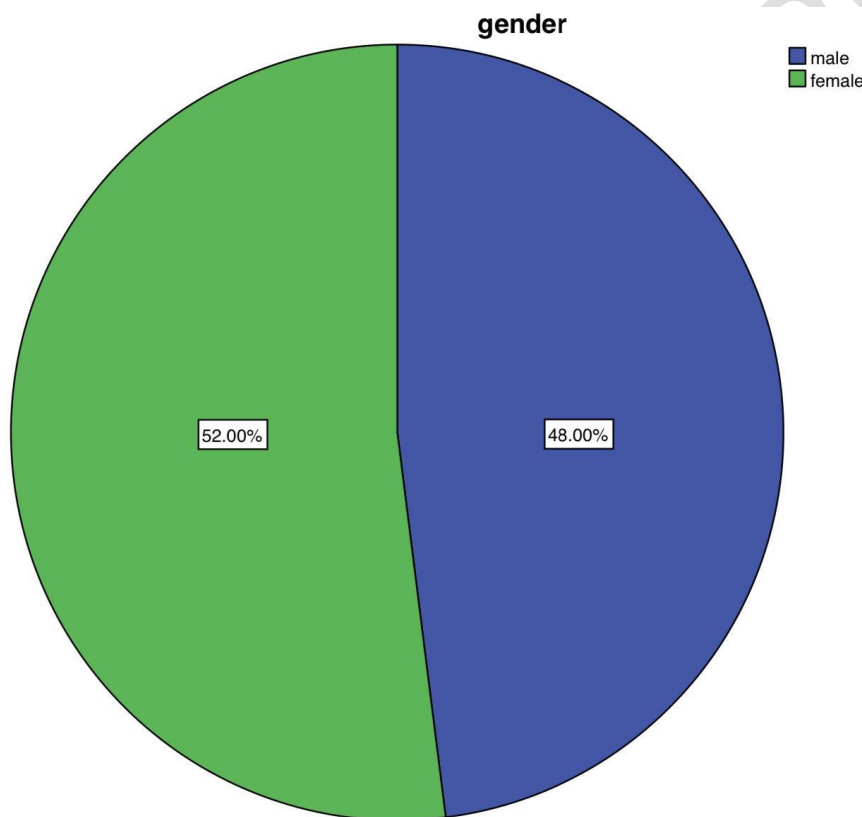
Data were recorded in Microsoft Excel 2016 (Microsoft office 10) and later exported to SPSS statistical package for social science for windows versions, 20.0, SPSS Inc, (Chicago IU, USA)

and subjected to statistical analysis. The Chi-square test was employed with a level of significance set at  $p < 0.05$ .

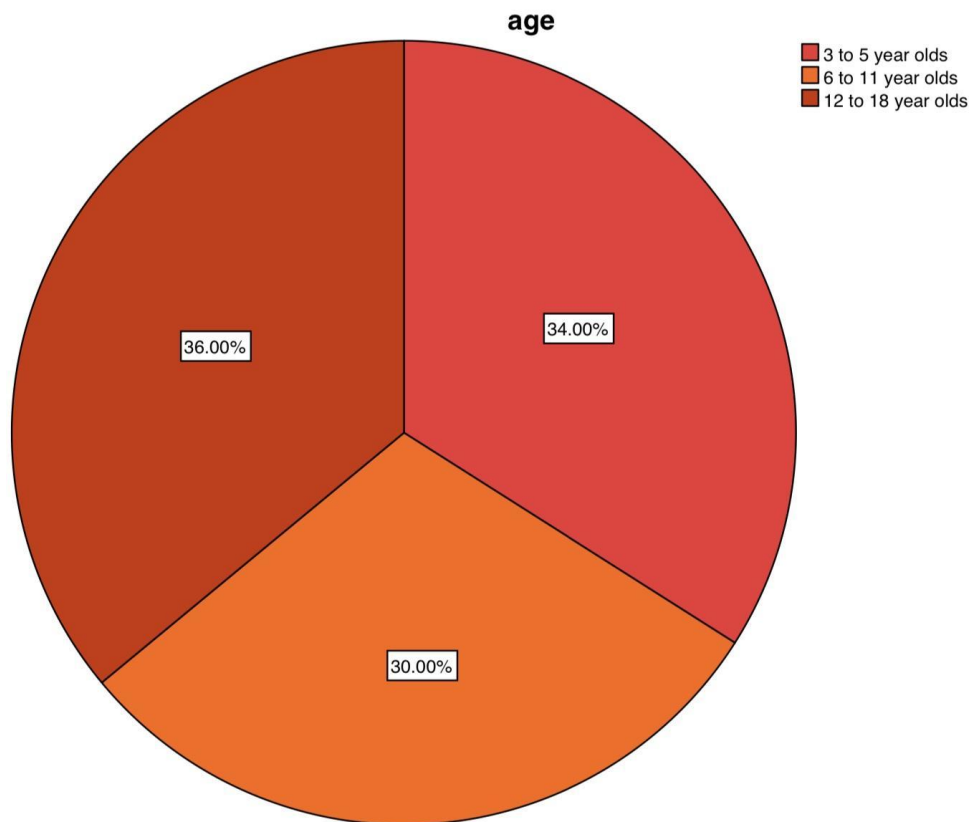
## RESULTS & DISCUSSION

“Management of avulsion of the primary and permanent dentition often presents a challenge”[17]. “The prognosis depends on the measures taken at or immediately after the time of the avulsion. Replantation is the only treatment choice, but careful assessment of the cases is of utmost importance for the avulsed tooth to be successfully replanted”. [17] Figure 1: Pie chart shows the gender distribution among the sample population. Males which is 48% and females which is 52%. Figure 2: Pie chart shows the age distribution of the given sample population. The age group 6 to 11-year-olds which is 30% and the age group 12 to 18-year-olds which is 36%. Figure 3: Barchart shows the association between type of dentition and age group. Among the primary dentition, 4% belong to 3 to 5-year-olds, 3% belong to 6 to 11-year-olds and 6% belong to 12 to 18-year-olds. Among permanent dentition, 30% belongs to 3 to 5-year-olds, 27% belongs to 6 to 11-year-olds and 30% belongs to 12 to 18-year-olds. Figure 4: Barchart shows the association between type of dentition and gender. Among primary dentition, it was more prevalent in females (9%) than males (4%). Among permanent dentition, it was more prevalent in males (44%) than females (43%). “The prompt rescue and replantation of an avulsed tooth will enhance the probability of achieving a favorable outcome after trauma. Treatment of avulsed teeth after unfavorable tooth rescue aims at delaying the onset and/or limiting the extent of replacement resorption”[6]. “It is of clinical importance to preserve the tooth and surrounding bone tissue to provide optimal, definitive, prosthodontic rehabilitation under the possibility of later treatment with dental implants. Management of avulsion of the permanent dentition often presents a challenge. The prognosis depends on the measures taken at or immediately after the time of the avulsion. Replantation is the only treatment choice, but careful assessment of the cases is of utmost importance for the avulsed tooth to be successfully replanted. In previous studies, it indicated that children’s with early childhood caries are more prone to dental trauma”[18]. Previous studies indicate that articaine has been used in tooth avulsion in order to reduce the pain post-trauma [19]. Previous studies research done by researchers on posterior space maintainers [20]. Children sustaining trauma should undergo computed tomographic (CT) examination to exclude potential complications [21](Velusamy et al. 2021). While treating

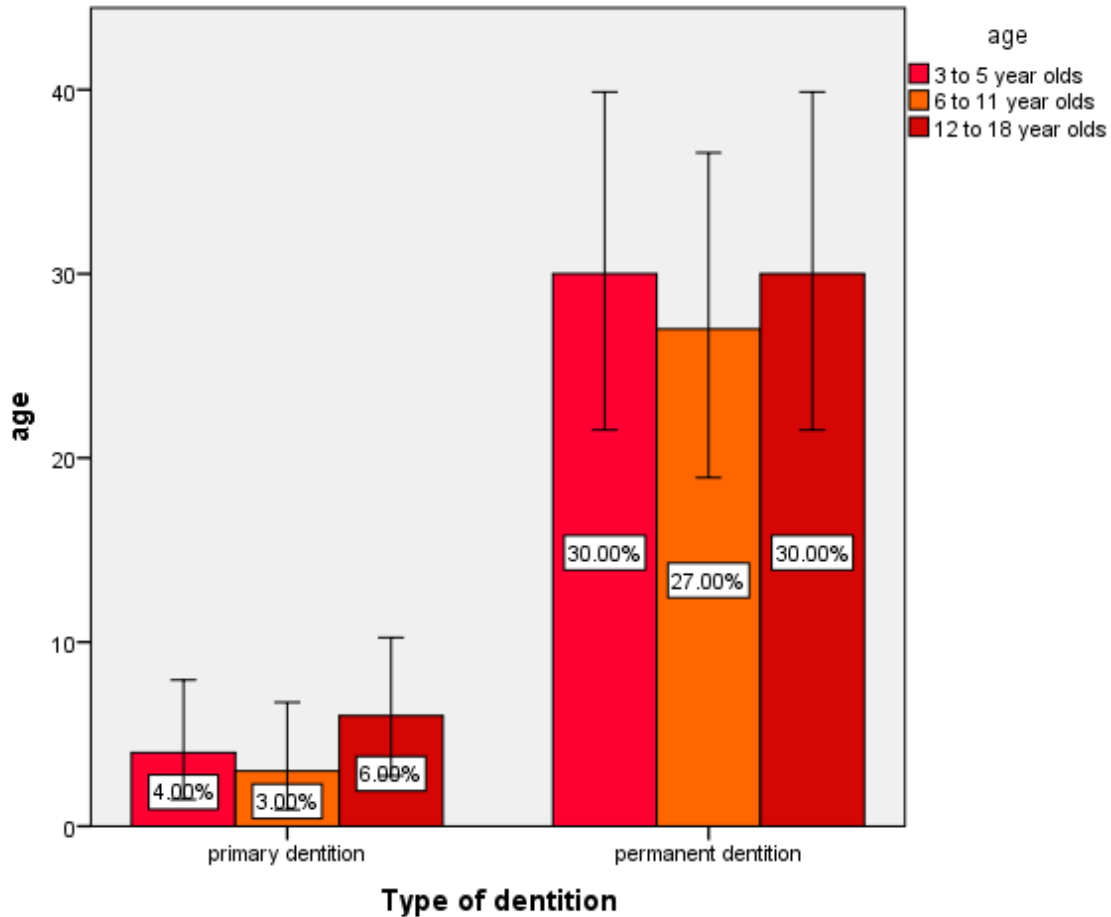
pediatric patients it's important for pedodontists to take preventive measures against covid19 as there are chances of unknown spread of the novel corona virus [22]([Aldhuwayhi et al. 2021](#)). Previous studies indicates the use of theaflavin, black tunicate, and zingerone in dental trauma reduces inflammation due to its anti-inflammatory activity [23][24][25]([Syed et al. 2021](#)). Previous studies were done by researchers on mutations, hypertension, diabetes, and biological and Clinical Relevance of microRNAs in Mitochondrial Diseases/Dysfunctions[26]([Sekar et al. 2020](#))([Bai et al. 2019](#))([Sekar 2019](#))([Sekar et al. 2019](#))([Parimelazhagan et al. 2021](#)). Previous researches have indicated that in cases of delayed replantation of the avulsed tooth which could later be followed up by implant ([Duraísamy et al. 2019](#))([Radiographic evaluation of permanent ...](#))([Menon et al. 2020](#))([Varghese et al. 2021](#)).



**Figure 1: Pie chart shows the gender distribution among the sample population. Blue color denotes male which is 48% and green color denotes female which is 52%.**

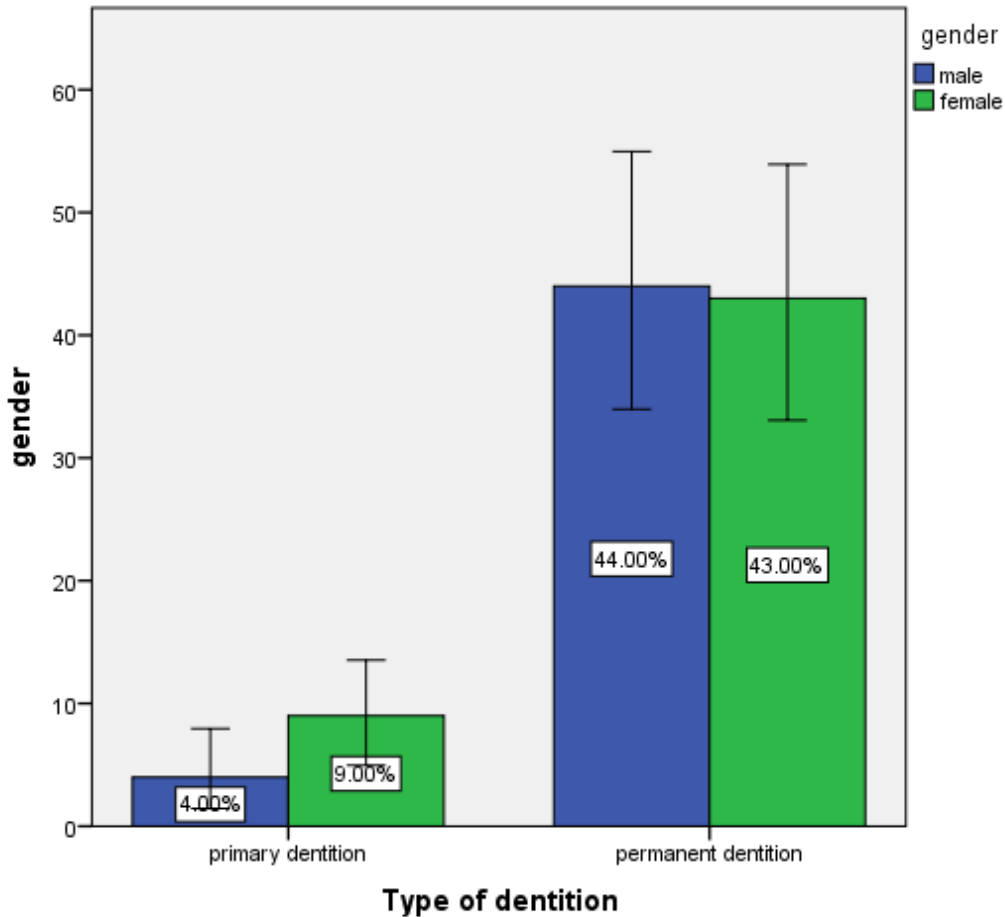


**Figure 2: Pie chart shows the age distribution of the given sample population. Red color denotes the age group of 3 to 5-year-olds which is 34%, orange color denotes the age group 6 to 11-year-olds which is 30% and brown color denotes 12 to 18-year-olds which is 36%.**



**Figure 3: Bar chart shows the association between type of dentition and age group.**

The X-axis represents the percentage of the type of dentition and the Y-axis represents the percentage of age group. Red color denotes the age group of 3 to 5-year-olds, orange color denotes the age group 6 to 11-year-olds and brown color denotes 12 to 18-year-olds. Among the primary dentition, 4% belong to 3 to 5-year-olds, 3% belong to 6 to 11-year-olds and 6% belong to 12 to 18-year-olds. Among permanent dentition, 30% belongs to 3 to 5-year-olds, 27% belongs to 6 to 11-year-olds and 30% belongs to 12 to 18-year-olds. Pearson chi-square test shows p-value is 0.03, ( $p\text{-value} > 0.05$ ). Hence, it is statistically significant. Hence proving that there was an association between age group and type of dentition.



**Figure 4: Bar chart shows the association between type of dentition and gender.**

The X-axis represents the percentage of the type of dentition and the Y-axis represents the percentage of gender. The green color denotes females and the blue color denotes males. Among primary dentition, it was more prevalent in females (9%) than males (4%). Among permanent dentition, it was more prevalent in males (44%) than females (43%). Pearson chi-square test shows p-value is 0.04, ( $p\text{-value} > 0.05$ ). Hence, it is statistically significant. Hence proving that there was an association between gender and type of dentition.

## CONCLUSION

Therefore, it could be concluded that tooth avulsion was more prevalent in females (52%) when compared to males (48%) and was more incident in permanent dentition when compared to the primary dentition. Tooth avulsion remains a severe dental injury with an unpredictable prognosis, which demands new fundamental research aiming to maintain and/or regenerate the

PDL after tooth avulsion. As general dentists form a vital link with the patient, they need to be educated on emergency management of avulsed teeth and their dilemma about some aspects of this procedure can be solved by providing required awareness and knowledge.

#### ETHICAL APPROVAL:

The ethical approval was obtained from the institutional ethics committee under the ethical approval number SDC/SIHEC/2021/DIASDATA/0619-0320/.

#### Consent

As per international standards or university standards, patient(s) written consent has been collected and preserved by the author(s).

#### REFERENCES

- [1] Addo ME. Textbook and color atlas of traumatic injuries to the teeth (4th edition). *British Dental Journal* 2007;203:615–615. <https://doi.org/10.1038/bdj.2007.1053>.
- [2] Trope M. Avulsion of permanent teeth: theory to practice. *Dent Traumatol* 2011;27:281–94. <https://doi.org/10.1111/j.1600-9657.2011.01003.x>.
- [3] Roskamp L, Trevilatto PC, Souza CM, Silva Neto UX, Carneiro E, Fariniuk LF, et al. Types of External Root Resorption of Replanted Teeth: Analysis of the Clinical Aspects and of Interleukin-4 Gene Polymorphisms Involvement. *J Endod* 2017;43:1792–6. <https://doi.org/10.1016/j.joen.2017.06.027>.
- [4] Andreasen JO, Bakland LK, Flores MT, Andreasen FM, Andersson L. *Traumatic Dental Injuries: A Manual*. John Wiley & Sons; 2011.
- [5] Andreasen JO, Borum MK, Jacobsen HL, Andreasen FM. Replantation of 400 avulsed permanent incisors. 4. Factors related to periodontal ligament healing. *Endod Dent Traumatol* 1995;11:76–89. <https://doi.org/10.1111/j.1600-9657.1995.tb00464.x>.
- [6] Andersson L, Bodin I. Avulsed human teeth replanted within 15 minutes--a long-term clinical follow-up study. *Endod Dent Traumatol* 1990;6:37–42. <https://doi.org/10.1111/j.1600-9657.1990.tb00385.x>.
- [7] Iglesias-Linares A, Hartsfield JK Jr. Cellular and Molecular Pathways Leading to External Root Resorption. *J Dent Res* 2017;96:145–52. <https://doi.org/10.1177/0022034516677539>.
- [8] Fuss Z, Tsesis I, Lin S. Root resorption--diagnosis, classification and treatment choices based on stimulation factors. *Dent Traumatol* 2003;19:175–82. <https://doi.org/10.1034/j.1600-9657.2003.00192.x>.
- [9] Trope M. Root Resorption due to Dental Trauma. *Endod Topics* 2002;1:79–100. <https://doi.org/10.1034/j.1601-1546.2002.10106.x>.
- [10] Hammarström L, Blomlöf L, Lindskog S. Dynamics of dentoalveolar ankylosis and

- associated root resorption. *Endod Dent Traumatol* 1989;5:163–75.  
<https://doi.org/10.1111/j.1600-9657.1989.tb00354.x>.
- [11] Fujita Y, Shiono Y, Maki K. Knowledge of emergency management of avulsed tooth among Japanese dental students. *BMC Oral Health* 2014;14:34.  
<https://doi.org/10.1186/1472-6831-14-34>.
- [12] Mustafa M. Awareness about Management of Tooth Avulsion among General Dental Practitioners: A Questionnaire Based Study. *Journal of Orthodontics & Endodontics* 2017;03. <https://doi.org/10.21767/2469-2980.100036>.
- [13] Abu-Dawoud M, Al-Enezi B, Andersson L. Knowledge of emergency management of avulsed teeth among young physicians and dentists. *Dent Traumatol* 2007;23:348–55.  
<https://doi.org/10.1111/j.1600-9657.2006.00477.x>.
- [14] Enabulele JE, Others. Knowledge of Hospital Emergency Unit Staff About the First-Aid Management of Traumatic Tooth Avulsion in A Tertiary Hospital in Nigeria. *EC Dental Science* 2016;5:1082–9.
- [15] Kumar S. The Status of Knowledge Related to the Emergency Management of Avulsed Tooth amongst the Medical Practitioners of Nagpur, Central India. *JOURNAL OF CLINICAL AND DIAGNOSTIC RESEARCH* 2017.  
<https://doi.org/10.7860/jcdr/2017/26422.9811>.
- [16] Flores MT, Andersson L, Andreasen JO, Bakland LK, Malmgren B, Barnett F, et al. Guidelines for the management of traumatic dental injuries. II. Avulsion of permanent teeth. *Dental Traumatology* 2007;23:130–6. <https://doi.org/10.1111/j.1600-9657.2007.00605.x>.
- [17] Zuhail K, Semra OEM, Hüseyin K. Traumatic injuries of the permanent incisors in children in southern Turkey: a retrospective study. *Dent Traumatol* 2005;21:20–5.  
<https://doi.org/10.1111/j.1600-9657.2004.00265.x>.
- [18] Subramanyam D, Gurunathan D, Gaayathri R, Vishnu Priya V. Comparative evaluation of salivary malondialdehyde levels as a marker of lipid peroxidation in early childhood caries. *Eur J Dent* 2018;12:67–70. [https://doi.org/10.4103/ejd.ejd\\_266\\_17](https://doi.org/10.4103/ejd.ejd_266_17).
- [19] Ramadurai N, Gurunathan D, Samuel AV, Subramanian E, Rodrigues SJL. Effectiveness of 2% Articaine as an anesthetic agent in children: randomized controlled trial. *Clin Oral Investig* 2019;23:3543–50. <https://doi.org/10.1007/s00784-018-2775-5>.
- [20] Ramakrishnan M, Dhanalakshmi R, Subramanian EMG. Survival rate of different fixed posterior space maintainers used in Paediatric Dentistry - A systematic review. *Saudi Dent J* 2019;31:165–72. <https://doi.org/10.1016/j.sdentj.2019.02.037>.
- [21] Jeevanandan G, Thomas E. Volumetric analysis of hand, reciprocating and rotary instrumentation techniques in primary molars using spiral computed tomography: An in vitro comparative study. *Eur J Dent* 2018;12:21–6. [https://doi.org/10.4103/ejd.ejd\\_247\\_17](https://doi.org/10.4103/ejd.ejd_247_17).
- [22] Princeton B, Santhakumar P, Prathap L. Awareness on Preventive Measures taken by Health Care Professionals Attending COVID-19 Patients among Dental Students. *European Journal of Dentistry* 2020;14:S105–9. <https://doi.org/10.1055/s-0040-1721296>.
- [23] Mathew MG, Samuel SR, Soni AJ, Roopa KB. Evaluation of adhesion of *Streptococcus mutans*, plaque accumulation on zirconia and stainless steel crowns, and surrounding gingival inflammation in primary molars: randomized controlled trial. *Clin Oral Investig* 2020;24:3275–80. <https://doi.org/10.1007/s00784-020-03204-9>.
- [24] Gothandam K, Ganesan VS, Ayyasamy T, Ramalingam S. Antioxidant potential of theaflavin ameliorates the activities of key enzymes of glucose metabolism in high fat diet and streptozotocin - induced diabetic rats. *Redox Rep* 2019;24:41–50.

<https://doi.org/10.1080/13510002.2019.1624085>.

- [25] Su P, Veeraraghavan VP, Krishna Mohan S, Lu W. A ginger derivative, zingerone-a phenolic compound-induces ROS-mediated apoptosis in colon cancer cells (HCT-116). *J Biochem Mol Toxicol* 2019;33:e22403. <https://doi.org/10.1002/jbt.22403>.
- [26] Sekar D, Johnson J, Biruntha M, Lakhmanan G, Gurunathan D, Ross K. Biological and Clinical Relevance of microRNAs in Mitochondrial Diseases/Dysfunctions. *DNA and Cell Biology* 2020;39:1379–84. <https://doi.org/10.1089/dna.2019.5013>.

UNDER PEER REVIEW