

BILATERAL TITLED OPTICS DISCS WITH POSTERIOR STAPHYLOMA IN NON-MYOPIC EYES: A CASE REPORT

ABSTRACT

Objective: To describe a case of bilateral titled optics discs with posterior staphyloma in non-myopic eyes.

Results: This was a 66-year-old woman with a history of metabolic syndrome presented to the ophthalmology clinic for a bilateral painless visual impairment evolving gradually for the last three months. Clinical examination revealed a bilateral astigmatism in both eyes: -0.75 at 93 degree on right eye and at 64 degree on left eye. The best corrected visual acuity was 20/20 in both eyes. The examination of the anterior segment was normal. The fundus examination noted an inferonasal titled optic discs associated with staphyloma. An orbito-cerebral magnetic resonance imaging was performed to document the staphyloma and exclude an optic disc hypoplasia. The MRI confirmed the bilateral eyeballs staphyloma without any other issue.

Keys-words: staphyloma, optic, titled, disc

INTRODUCTION

Staphyloma is a non-pathological anatomical condition that is common in myopes but can also be found in non-myopes, predisposing them to the same risks ¹. We report a case of an emmetropic patient with papillary diversion and posterior pole staphyloma.

Case

This was a 66-year-old woman with a history of metabolic syndrome (diabetes +hypertension) presented to the ophthalmology clinic for a bilateral painless visual impairment evolving gradually for the last three months.

Clinical examination revealed a bilateral astigmatism in both eyes: -0.75 at 93 degree on right eye and at 64 degree on left eye. The best corrected visual acuity was 20/20 in both eyes.

The examination of the anterior segment was normal.

We realized a dilated fundus examination looking for a hypertensive or diabetic retinopathy. We noted an inferonasal titled optic discs associated with astaphyloma (**figure 1**).

An orbito-cerebral magnetic resonance imaging was performed to document the staphyloma and exclude an optic disc hypoplasia. The MRI confirmed the bilateral eyeballs staphyloma without any other issue (figure 2).

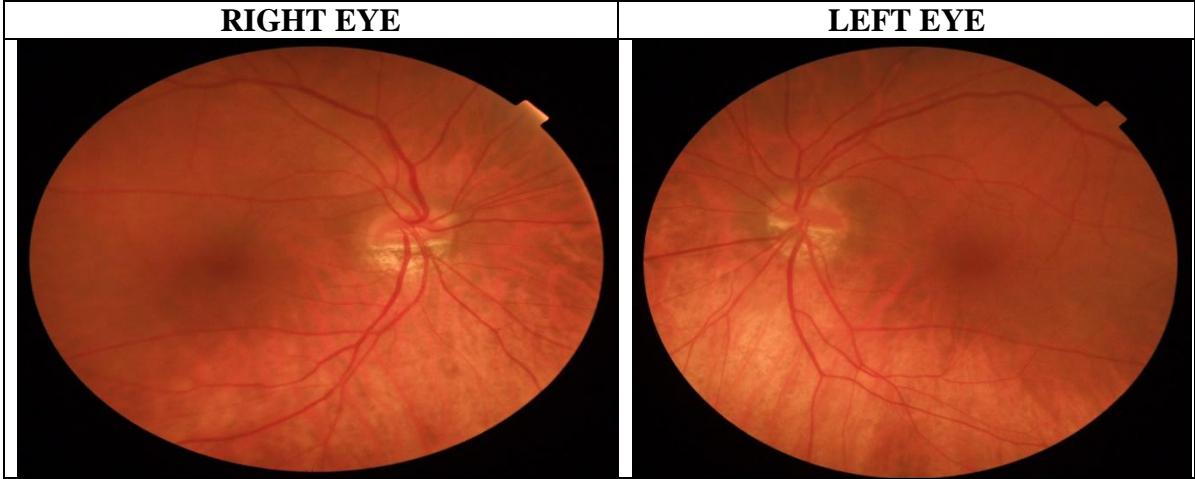

Figure 1: Retinophotography

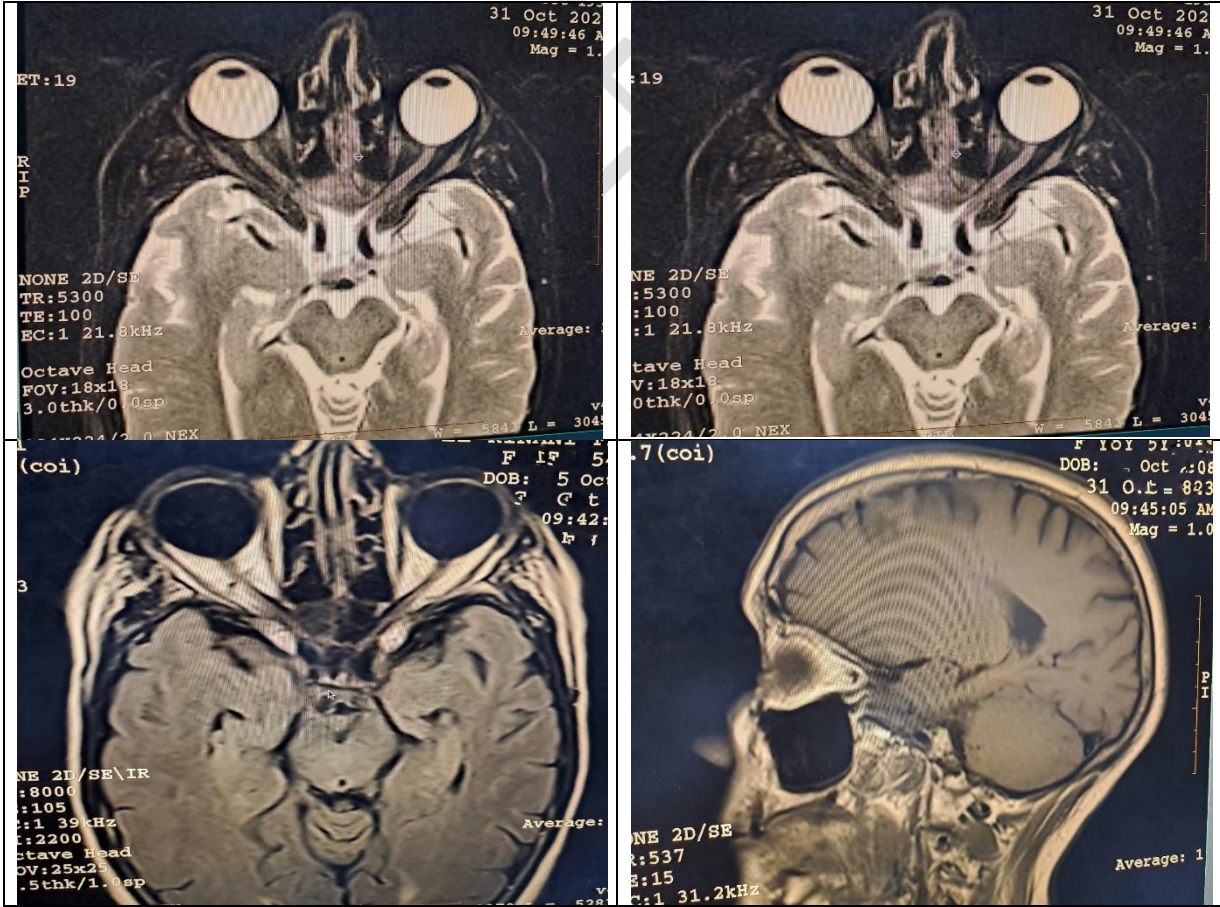


Figure 2: Orbitocerebral MRI

The objective of our work was to show that retinal changes common in strong myopes can also be observed in patients with emmetropia or myopic astigmatism.

DISCUSSION

Myopia is one of the main causes of severe visual impairment. It is on the increase, with forecasts estimating that more than 50% of the population will be affected by 2050, 10% of whom will suffer from severe myopia 2. Myopia is a factor in several anatomical and functional alterations of the posterior pole, such as retinal detachment, macular hole, posterior staphyloma, known myopia and optic neuropathy 3.

The prevalence of posterior staphyloma in myopes ranges from 10 to 92%. However, it is rare in emmetropic eyes. It is very often bilateral and roughly symmetrical. Initially, authors suggested that the thinned, weakened and more extensible sclera would protrude along weak points. These points would correspond either to areas of embryonic fissure closure, or to the local organization of collagen fibers around the ON and macula 4.

However, the occurrence of staphyloma in non-myopic eyes calls this theory into question. This is why recent analyses have suggested that the deformation of the globe leading to detachment of the sclera from the choroid is due to traction exerted by the sheaths of the sclera-inserted optic fibers 5. The thinning of the choroid would be due to the tangential component of this traction 6. Staphyloma could be classified into 10 types according to Curtin, with 05 so-called simple types (I-V) and another 05 complex types (VI-X). Recently, a simplified classification of staphyloma into 06 types 7-8-9-10 :

Type I: wide macular staphyloma whose nasal margin encompasses the nasal margin of the papilla, including the so-called combined staphylomas of Curtin's classification and more complex scleral irregularities;

Type II: narrow macular staphyloma whose nasal border merges with the nasal border of the papilla;

Type III: peripapillary staphyloma;

Type IV: nasal staphyloma;

Type V: inferior staphyloma;

Type VI: other types of staphyloma.

CONCLUSION

Staphyloma associated with tilted optic disc is a rare anomaly in non-myopic subjects. Knowledge of this situation is a good starting point for medical research.

Consent

As per international standards or university standards, patient(s) written consent has been collected and preserved by the author(s).

REFERENCES

- 1- El Matri L, Falfoul Y, El Matri K, El Euch I, Ghali H, Habibi I, Hassairi A, Chaker N, Schorderet D, Chebil A. Posterior staphylomas in non-highly myopic eyes with retinitis pigmentosa. *Int Ophthalmol*. 2020 Sep;40(9):2159-2168. doi:10.1007/s10792-020-01396-3. Epub 2020 May 2. PMID: 32358734.
- 2- Zhou LX, Shao L, Xu L, Wei WB, Wang YX, You QS. The relationship between scleral staphyloma and choroidal thinning in highly myopic eyes: the Beijing Eye Study. *Scientific representative*. 2017; 7(1):9825. PMID: 28852194; PMCID: PMC5575118. doi:10.1038/s41598-017-10660-z
- 3- Ohno-Matsui K, Jonas JB. Posterior staphyloma in pathologic myopia. *Prog Retin Eye Res*. 2019 May; 70:99-109. doi: 10.1016/j.preteyeres.2018.12.001. Epub 2018 Dec 8. PMID: 30537538.
- 4- Ohno-Matsui K, Akiba M, Modegi T et al. "Association between scleral shape and myopic retinochoroidal lesions in patients with pathological myopia". *Invest Ophthalmol Vis Sci*. 2012; 53 (10): 6046-6061. PMID: 22879412. doi: 10.1167/iovs.12-10161
- 5- emer JL. "The optic nerve sheath as a new mechanical load on the globe in ocular conduction". *Invest Ophthalmol Vis Sci*. 2016; 57 (4): 1826-1838. PMID: 27082297; PMCID: PMC4849549. doi:10.1167/iovs.15-18718
- 6- Ehongo A, Bacq N, Kisma N et al. Analysis of peripapillary intrachoroidal cavitation and myopic peripapillary distortions in polar regions by optical coherence tomography. *Clin Ophthalmol*. 2022; 16:2617-2629. PMID: 35992567; PMCID: PMC9387167. doi: 10.2147/OPHTH.S376597
- 7-Gaucher D, Erginay A, Lecleire-Collet A, et al. Dome-shaped macula in eyes with myopic posterior staphyloma, *Am J Ophthalmol* 2008; 145:909-914.
- 8-Ohno-Matsui K, Akiba M, Moriyama M, et al. Intrachoroidal cavitation in macular area of eyes with pathologic myopia, *Am J Ophthalmol* 2012; 154: 382 - 393.

9-Toranzo J, Cohen SY, Erginay A, Gaudric A, Peripapillary intrachoroidal cavitation in myopia, *Am J Ophthalmol* 2005; 140(4): 731 - 732.

10-Spaide RF, Akiba M, Ohno-Matsui K, Evaluation of peripapillary intrachoroidal cavitation with swept source and enhanced depth imaging optical coherence tomography, *Retina* 2012; 32(6): 1037 - 1044.

UNDER PEER REVIEW