

A rare case study Biliary cystadenoma- management and review of literature.

Abstract

This case reports the obstructive jaundice and cholangitis correlate with malignant disease and typically occurs with extra hepatic biliary cystadenoma. A 50 years non-alcoholic, post-menopausal female patient presented to OPD with itching all over the body for 3 months. She had colicky type of pain in upper abdomen from last 7 days.

Epithelial cells that line the gall bladder or bile ducts are the source of biliary cystadenoma. These cells are multiloculated and multiseptated. Another method is enucleation which is recommended in cases where the tumour size and positioning makes resection unachievable.

Key words- Biliary cystadenomas, tumour epithelial cells, hepatobiliary stem cells.

Abbreviations with full form- CBD-common bile duct, USG-Ultrasonogram, MRCP-magnetic resonance cholangiopancreatography, MRI-magnetic resonance imaging, LFT- liver function test, AFP- alpha fetoprotein, CEA- carcinoembryonic antigen.

Introduction- Less than 5% of liver cysts that are non-parasitic are caused by biliary cystadenoma(1). More often originate from primary biliary system or from the aberrant bile duct (1,7,8). Fewer are extra hepatic, and most are intrahepatic (85%). They sporadically appear to originate from the gallbladder. Clinically and radiologically, it is challenging to determine between biliary cystadenoma and biliary cyst adenocarcinomas, so surgery to be taken into consideration.

At the time of diagnosis, most of the patients are middle-aged women with an average age of 45. The majority of the symptoms such as Epigastric and right upper quadrant pain, jaundice, cholangitis are caused by mass effects.

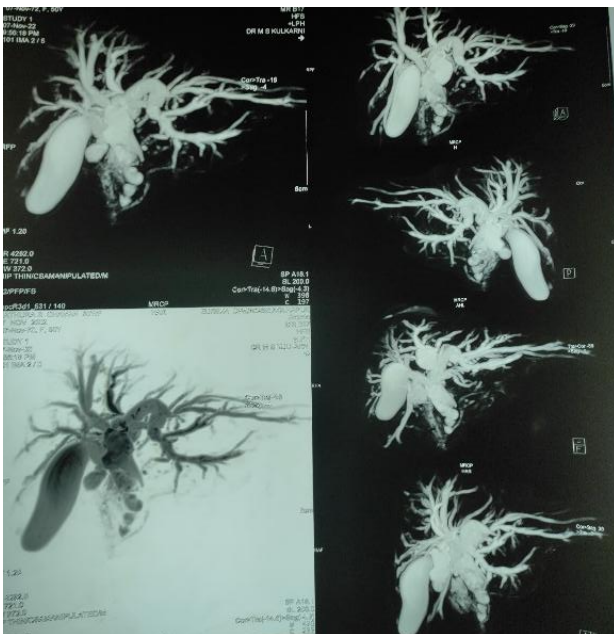Obstructive jaundice and cholangitis are uncommon, do not occur with malignant illness and are often associated with extra hepatic cystadenoma.

Case presentation-

50 years non-alcoholic, post-menopausal female patient presented to OPD with itching all over the body for 3 months she had collected type of pain in upper abdomen from last 7 days. No history of Malena, weight loss or fever.

Serum amylase, lipase and routine blood reports were normal. Serum bilirubin total: 10.2, Direct bilirubin: 8.3, Indirect bilirubin: 1.9 Alkaline phosphatase: 491.

USG suggestive of dilated intrahepatic ducts with dilated common bile duct (CBD) with hypoechoic growth within, prompting further imaging. So, contrast CT was done, suggestive of multiseptated cystic lesion in CBD, common hepatic ducts and left hepatic duct. Dilated CBD measures 12mm. Mild thickening of CBD with small focal heterogenous enhancement at papilla? infective? Neoplastic aetiology needs further correlation. so MRCP done. MRCP findings shown in figure 1.



MRCP

Figure 1: name of image: **MRCP** showing.

- Fusiform enlargement of entire CBD, more in supra-pancreatic region.
- Dilated CBD, Right and left hepatic duct.
- Multi septate, cystic morphology, filling and distending CBD as well as common hepatic duct? Possibility of cystic neoplastic lesion.

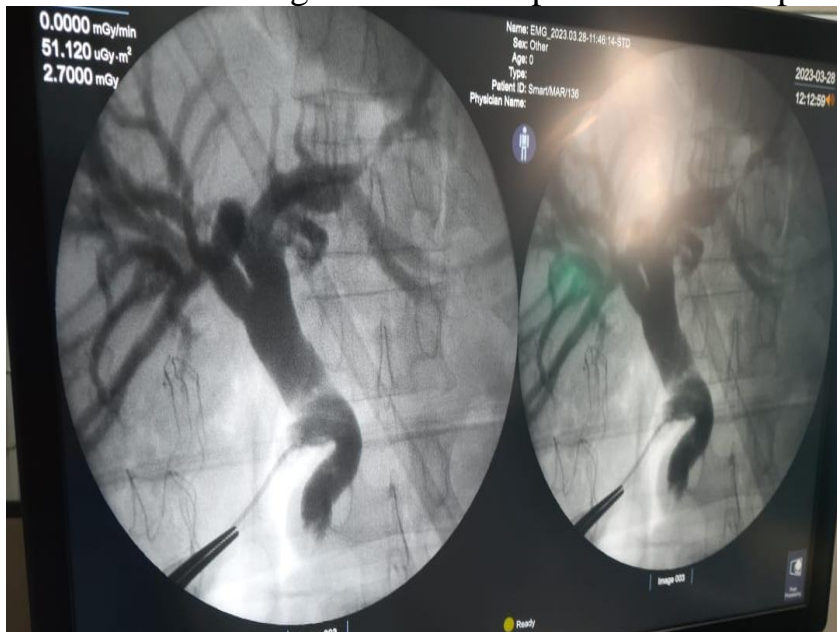
So, after consulting with GI surgeon, the first step was to perform an ERCP with stenting to relieve obstructive jaundice, followed by definitive surgery. ERCP with stenting was completed with 7 French plastic catheter.

To rule out malignancy, tumor markers CEA, AFP and CA 19-9 were sent, the results were normal, and patient was scheduled for surgery.

Intraoperative findings:

Kocher's incision was performed. Distended gall bladder noted with enlarged peri choledochal lymph nodes. Lymph nodes were sent for frozen section,

which was suggestive of reactive lymphadenitis. Cystic growth was palpable in CBD with extending to common hepatic duct. Intraoperative cholangiogram was performed to locate cystic growth (as shown in fig.2)



performed to locate cystic growth (as shown in fig.2)

Figure 2:
Intraoperative cholangiogram delineating the cystic growth extending from intra hepatic ducts to CBD with filling defect.

CBD exploration done; cystic lesion detected in CBD extending from intra hepatic ducts to second portion of CBD. Stent in CBD noted with normal distal part of CBD.

CBD EXPLORATION AND REMOVAL OF LESION:

After CBD exploration, 7*2cm cystic lesion extending from CBD to confluence of hepatic duct removed (As shown in figure 3) and send for histopathological examination. CBD patency was confirmed after removing cystic growth. CBD closure done with polyglactin 3.0. Cholecystectomy done on same setting. Excised specimen shown in figure 4. Histopathological slides shown in figure 5 and 6.

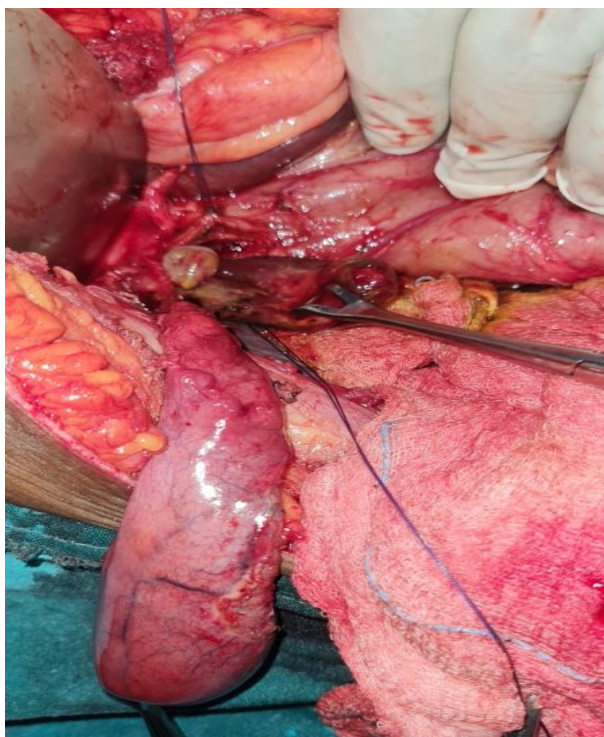


Figure 3: CBD exploration with removal of cystic lesion.

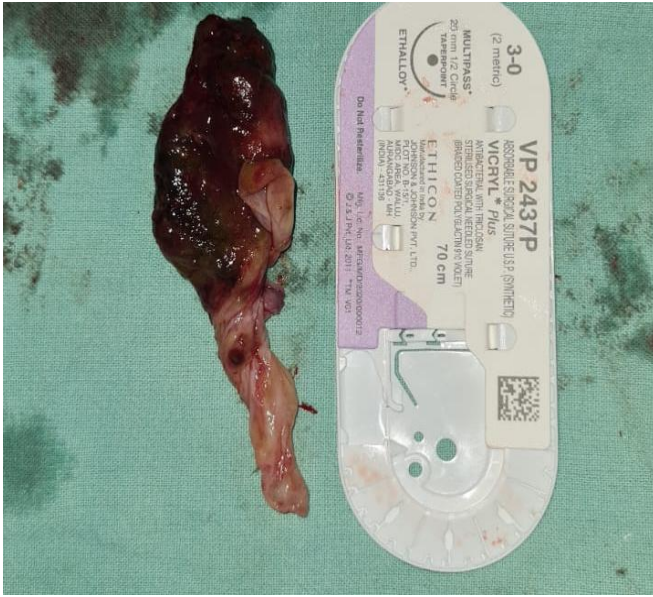

Figure 4: Excised specimen.

Histopathological slides:

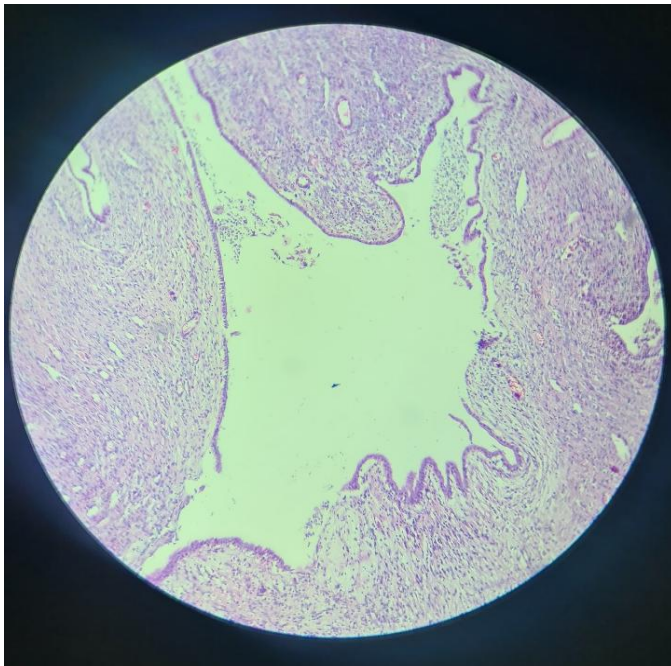


Figure.5(10x view of biliary cystadenoma)

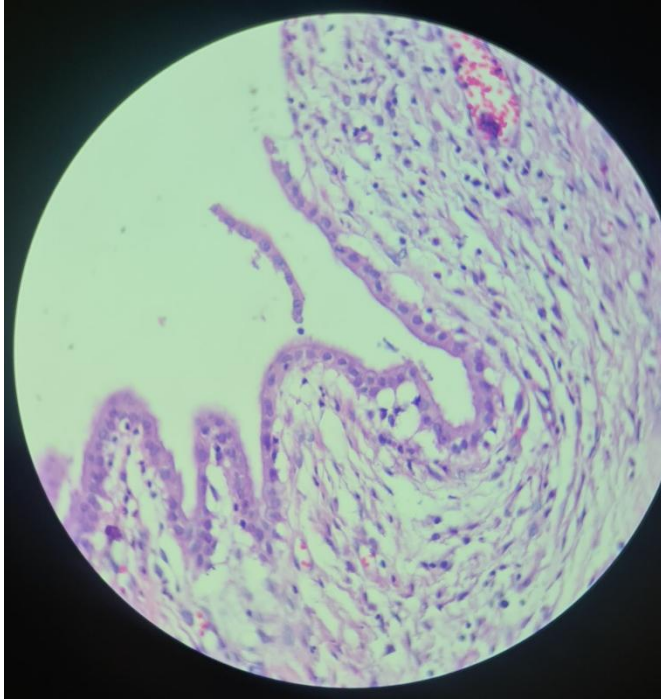


Figure.6 (40x view of biliary cystadenoma)

Post operative care: Patient Symptomatically and clinically improved, as compared to preoperatively. Drain was removed on pod 4. Repeat LFT was done, significant improvement noted in serum bilirubin levels as compared to preoperative levels. Patient was discharged and advised to follow up after 1 month for CBD stent removal.

Discussion:

Rare liver tumours referred to as biliary cystadenomas show non-specific signs and symptoms [3]. Most frequently demonstrated as asymptomatic and incidental findings result from radiological imaging [4]. In our case, patient was presented as pruritis, pain in abdomen and incidental detection of cystic growth in CBD on radiological imaging.

Pain from intracystic bleeding or cyst rupture, alongside fever from cyst infection, are common acute presenting symptoms. one of the two possible cause of jaundice is an intraluminal tumour mass or extrinsic compression of bile duct. In our case, jaundice was due to intra luminal growth in CBD.

The recommendation was for complete surgical removal of tumour. because of possibility that a biliary cystadenoma could turn into malignancy as well as the incapacity to distinguish between benign and malignant masses [5].

Multiloculated and multiseptated biliary cystadenomas originate from the epithelial cell lining the bile ducts or gall bladder. The bile ducts of right hepatic lobe usually the source of these tumours [6]. Even yet benign cystadenomas can become biliary cystadenocarcinomas if they are not completely removed. in this case also, lesion was arising from hepatic ducts and complete excision of tumour was done to prevent recurrence.

Usually, masses on MRI have low intensity on T1 pictures and high intensity on T2 imaging. The fluid component of cystadenoma can have varying blood content and protein contents, which can affect the CT attenuation and T1 and T2 images. NO diagnostic techniques ensures whether the mass is benign or malignant.

Conclusion:

Any multiloculated cystic liver lesions should be evaluated for the possibility of biliary cystadenoma, especially middle-aged female. For any suspected biliary cyst adenoma, complete resection is preferred course of treatment. It can be quite challenging to distinguish between benign and malignant tumour based on radiological scans. When total resection is not possible, another alternative is enucleation.

References:

- [1] D. A. Wheeler and H. A. Edmondson, "Cystadenoma with mesenchymal stroma (CMS) in the liver and bile ducts. A clinicopathologic study of 17 cases, 4 with malignant change," *Cancer*, vol. 56, no. 6, pp. 1434–1445, 1985.
- [2] P. Del Poggio, C. Jamoletti, B. Forloni et al., "Malignant transformation of biliary cystadenoma: a difficult diagnosis," *Digestive and Liver Disease*, vol. 32, no. 8, pp. 733–736, 2000.
- [3] J. M. L. Williamson, J. R. Rees, I. Pope, and A. Strickland, "Hepatobiliary cystadenomas," *Annals of the Royal College of Surgeons of England*, vol. 7, pp. 507–510, 2013.
- [4] P. C. Chandrasinghe, C. Liyanage, K. I. Deen, and S. R. Wijesuriya, "Obstructive jaundice caused by a biliary mucinous cystadenoma in a woman: a case report," *Journal of Medical Case Reports*, vol. 7, article 278, 2013.
- [5] A. D. Levy, L. A. Murakata, R. M. Abbott, and C. A. Rohrmann Jr., "From the archives of the AFIP: benign tumours and tumorlike lesions of the gallbladder and extrahepatic bile ducts: radiologic-pathologic correlation," *Radiographic*, vol. 22, no. 2, pp. 387–413, 2002.
- [6] K. M. Horton, D. A. Bluemke, R. H. Hruban, P. Soyer, and E. K. Fishman, "CT and MR imaging of benign hepatic and biliary tumours," *Radiographic*, vol. 19, no. 2, pp. 431–451, 1999.
- [7] W. D. Lewis, R. L. Jenkins, W. V. McDermott et al., "Surgical treatment of biliary cystadenoma. A report of 15 cases," *Archives of Surgery*, vol. 123, no. 5, pp. 563–568, 1988.] D. Soochan, V. Keough, I. Wanless, and M. Molinari, "Intra and extra-hepatic cystadenoma of the biliary duct.

Review of literature and radiological and pathological characteristics of a very rare case,” *BMJ Case Reports*, vol. 2012, pp. 1–5, 2012.

[8] C.-C. Wu, W.-L. Ho, J.-T. Chen et al., “Mesohepatectomy for centrally located hepatocellular carcinoma: an appraisal of a rare procedure,” *Journal of the American College of Surgeons*, vol. 188, no. 5, pp. 508–515, 1999.

[9] J. Qiu, H. Wu, Y. Bai et al., “Mesohepatectomy for centrally located liver tumours,” *British Journal of Surgery*, vol. 100, no. 12, pp. 1620–1626, 2013.

[10] E. Palacios, M. Shannon, C. Solomon, and M. Guzman, “Biliary cystadenoma: ultrasound, CT, and MRI,” *Gastrointestinal Radiology*, vol. 15, no. 4, pp. 313–316, 1990.

[11] M. A. Marcial, S. C. Hauser, E. S. Cibas, and J. Braver, “Intrahepatic biliary cystadenoma. Clinical, radiological, and pathological findings,” *Digestive Diseases and Sciences*, vol. 31, no. 8, pp. 884–888, 1986.

[12] K. T. Thomas, D. Welch, and W. Pinson, “Effective treatment of biliary cystadenoma,” *Annals of Surgery*, vol. 241, no. 5, pp. 769–775, 2005.