

EFFECT OF ETHANOL EXTRACT OF AVOCADO PULP (*Persea americana mill*) ON SPERM QUALITY AND HISTOLOGICAL CHANGES IN CAFFEINE INDUCED TESTICULAR INJURY IN WISTAR RATS

ABSTRACT

This study evaluated the effect of ethanol extract of *Persea americana* pulp on caffeine induced testicular damage on male wistar rats. Fifty-four (54) mature male rats were used, they were divided into six (6) groups of nine (9) rats per group. Group 1 was not induced with caffeine, Group two (2) to group six (6) were induced with 200mg/kg caffeine for two weeks. Three rats were sacrificed from each group after two weeks of induction. Semen and testes collected for total sperm count, sperm motility, sperm morphology, sperm vitality and histopathology. The rats were treated as follows for another four weeks, Group 1: no induction, no treatment. Group 2: induced with caffeine without treatment. Group 3; 100mg/kg extract. Group 4: 300mg/kg extract. Group 5: 500mg/kg extract, Group 6: 0.107mg/kg proviron. The rats were sacrificed twice after treatment: two weeks after treatment and four weeks after treatment. semen and testes were collected for sperm parameters and histopathology respectively. Different doses of *Persea americana* pulp was able to improve the sperm quality in rats induced with caffeine in a dose and time dependent manner. Histopathological examination of the testes treated with extract showed recovery from damages caused by caffeine in dose dependent manner. Ethanol extract of *Persea americana* pulp has a dose ameliorating effect on caffeine induced testicular damage on male rats.

Keywords: *Persea Americana*, antioxidant, histology, caffeine,

INTRODUCTION

The application of food in medicine was advocated by Hippocrattess (Bagchi, 2006). Since the origin of mankind, plants have been employed in the cure of different health related disorders. The use of plants for therapy has been in existence before modern medicine. In most of the developing countries, especially in rural areas, while in the developed world, alternative medicine including the use of dietary supplements are used in the treatment of ailments. Research have been carried out on plants used in traditional medicine with a multidisciplinary approach with more than 10000 plants having being studied in the past five years which results to enough scientific evidence on the pharmacological effects of these plants (Dahanuka *et al*,2000).This knowledge has relevant application in the pharmacological industry as this has led to the synthesis of many active substances isolated from the plants.

Some medicinal plants are able to regulate reproduction (Chidrewaret *al*, 2011) and sperm DNA fragmentation induction. Plant products that have low toxicity have been employed in fertility

regulation (Singh, 2008). Plants that has effect in fertility include aloe vera, ananas comosus (pineapple), celery, carica papaya, citrus limon (lemon), curcuma longa (Indian saffron), cyclamen persicum and primula vulgaris, etc. Report from studies carried out in cattle, showed that the introduction of cynodon dactylon in the diet reduced the reproduction rate (Banta *et al*, 2008). Moreso, in Mexico and Mediterranean part of Europe, ethno-botanical studies were carried out and it reported the traditional use of *Ceterrach officinarum* as reproduction enhancer. Researches were conducted with lippia graveolens extracts and it was discovered to have contraceptive effect. Lippia graveolens exhibits toxicity effect when high doses of it is taken and it has effect on reproduction when it is taken as tea (Longe, 2002). Some of the communities in Durango in Mexico use *Tagetes lucida* (yerbanis) to control reproduction but there is no scientific proof for the anti-reproductive properties of such plants.

Avocado is an energetic tropical fruit that is highly nutritious. Apart from its high fat and protein content Avocado also contains fat soluble vitamins which are absent in other fruits such as vitamins A, B, D, and E. **The high oil content of the pulp is employed in the pharmaceutical and cosmetic industries for obtaining commercial oil similar to olive oils because of similar fatty acid composition.** Also the fruit has lots of health benefits because of compounds contained in its lipid fraction such as omega fatty acids, tocopherols, phytosterols and squalene (Santos *et al*, 2014).

Caffeine is a psychoactive compound which intake is on the high side (Best, 1999). The food substances that contain caffeine include: beverages, like coffee, tea, energy drinks, carbonated beverage products containing cocoa or chocolate. When caffeine is taken in low concentration, it can lead to alertness and positive effects in the heart but when caffeine is taken in high concentration, it can cause a wide range of undesirable mental and physical conditions such as nervousness, restlessness, irritability, insomnia, headache and heart palpitation after caffeine intake (Lanchetal., 2007). Intake of caffeine has connection with delayed conception, reproductive and developmental challenges (Christain and Brent, 2001) and high level of sperm aneuploidy (Robbins *et al*, 1997).

Persea americana pulp has been used in folk medicine to treat issues involving male fertility but there is no detailed study on the administration of the extract in caffeine induced testicular injury. This study evaluates the therapeutic effect of ethanolic extract of avocado pulp (*persea americana mill*) on sperm quality and histological changes in caffeine induced testicular injury on wistar rats.

Materials and Methods

Preparation of plant extract. Fresh fruits of *Persea americana* were bought from oil Mill market in Port Harcourt Rivers State of Nigeria. The avocado fruits were washed and peeled to remove the epidermal layer and the pulp was used for the crude ethanol extraction using Bligh and Dyer method (1959).

Procurement of caffeine standard drug (proviron)

Nescafe which contains 80% caffeine was purchased from Eddys supermarket, Rumuokoro, Port Harcourt, Rivers State. Proviron was purchased from Chimes pharmaceutical shop, Rumuokoro, Port Harcourt, Rivers State.

Animal handling and experimental design

Fifty-four (54) male rats were divided into six (6) groups of nine rats each based on their body weights. The rats were subjected to one week acclimatization before the commencement of the study. Group 2-6 received 200mg/kg body weight of caffeine for two weeks (14 days) after which group 3 received 100mg/kg body weight of *Persea Americana* extract, group 4 received 300mg/kg body weight of *Persea Americana* extract, group 5 received 500mg/kg body weight of *Persea Americana* extract, group 6 received 0.107 mg/kg body weight proviron. The treatment lasted for forty-two (42) days, three animals were killed from each group on day 14, 28 and 42. The rats were sacrificed under the chloroform anesthesia. The epididymis and the testes were dissected out. The epididymis were processed for sperm motility, viability, sperm count, sperm morphology (% abnormality), semen PH and sperm motility. The testes were used for histopathological examination.

Determination of sperm parameters

Estimation of total sperm count: Total sperm count was estimated using The **Neubauer cytometer** the method described by (Ekaluo et al ,2008). the result was expressed as million/ml of suspension.

Estimation of sperm vitality

The determination of Sperm vitality was done using Eosin-Nigrosin one step staining technique (Ekaluo, 2009).

$$\% \text{ Sperm viability} = \frac{\text{number of live cells} \times 100}{\text{Total number of sperm cells observed}}$$

Estimation of sperm motility

Sperm motility was determined using the method according to (Ekaluo, 2009)

$$\% \text{ SPERM MOTILITY} = \frac{\text{Number of progressively motile cells} \times 100}{\text{Total number of spermatozoa counted}}$$

Determination of sperm morphology (%abnormality)

The percentage sperm abnormality was determined using the method described by (Ekaluo et al, 2009)

Histopathological examination

After 24 h fixation period in Bouin's solution, the tissues were routinely dehydrated through graded alcohol series (70%, 80%, 90%, 95% and absolute alcohol), cleared in xylene and embedded in paraffin wax. Five slides were prepared from each animal, with tissue sections of 5- μ m thickness. The sections were stained with haematoxylin and eosin and observed under a light microscope (Labomed) for histological examination of the testis.

Results

The total sperm count, sperm motility, and sperm vitality was significantly ($p < 0.05$) decreased in the caffeine group when compared with the normal control. The sperm morphology (% abnormality) significantly ($p < 0.05$) increased in the caffeine group when compared with the normal control. There was no significant difference in the semen Ph of the caffeine induced group when compared with the normal control.

Table 1: Effect of *Persea americana* pulp on sperm parameters in rats induced with caffeine on day Fourteen (14)

Groups	Group description	Total sperm count ($10^6/ml$)	Sperm motility (%)	Sperm morphology (% abnormality)	Sperm vitality (%)	Semen p^H					
1	control	39.25 \pm 4.98 ^a	82.00 \pm 7.28 ^a	4.87 \pm 2.28 ^a	89.48 \pm 2.16 ^a	6.98 \pm 0.16 ^a					
2	caffeine	8.48 \pm 0.89 ^b	19.82 \pm 2.02 ^b	38.73 \pm 2.13 ^b	21.22 \pm 2.05 ^b	7.00 \pm 0.10 ^a					
3	100 mg /kg PAP	9.70 \pm 0.35 ^b	16.19 \pm 2.59 ^b	42.60 \pm 3.17 ^b	17.74 \pm 6.27 ^b	6.98 \pm 0.09 ^a					
4	300 mg/kg PAP	11.17 \pm 0.35 ^b	28.59 \pm 4.41 ^{bc}	45.07 \pm 5.21 ^b	42.70 \pm 2.40 ^c	7.01 \pm 0.03 ^a					
5	500 mg/kg PAP	10.47 \pm 0.98 ^b	32.92 \pm 5.06 ^c	35.90 \pm 4.45 ^b	61.04 \pm 6.10 ^d	6.96 \pm 0.06 ^a					
6	0.107 mg / kg Proviron	9.47 \pm 0.95 ^c	37.88 \pm 8.94 ^c	38.43 \pm 2.58 ^b	39.68 \pm 6.23 ^c	6.97 \pm 0.03 ^a					

*Values are shown in means of triplicate analysis \pm Standard Deviation. Values bearing different alphabetical superscript are significantly different ($p < 0.05$) from each other down the same column. BW = Body weight, mg=milligram ; kg = kilogram. PAP = *Persea americana* pulp

The total sperm count, sperm motility and sperm vitality of the groups treated with extract increased significantly ($p < 0.05$) when compared with the group induced with caffeine without treatment (positive control) but the increase is not comparable to the group treated with standard drug. There was a significant ($p < 0.05$) decrease in sperm morphology (% abnormality) of the group treated with extract when compared with the normal control.

Table 2; Effect of *Persea americana* pulp on sperm parameters in rats induced with caffeine on day Twenty eight (28).

Groups	Group description	Total sperm count ($10^6/ml$)	Sperm motility (%)	Sperm morphology (% abnormality)	Sperm vitality (%)	Semen pH
1	control	36.84 ± 2.06^a	85.75 ± 3.96^a	5.07 ± 0.76^a	90.76 ± 2.44^a	7.01 ± 0.06^a
2	caffeine	10.15 ± 0.58^b	22.12 ± 1.92^b	35.50 ± 3.67^b	21.63 ± 5.59^b	7.07 ± 0.08^a
3	100 mg /kg PAP	15.95 ± 2.05^d	38.27 ± 4.57^c	27.87 ± 1.84^d	29.70 ± 4.62^b	6.93 ± 0.07^a
4	300 mg/kg PAP	19.71 ± 0.71^d	12.57 ± 7.26^d	21.64 ± 4.02^{cd}	59.70 ± 10.71^d	6.99 ± 0.07^a
5	500 mg/kg PAP	22.70 ± 0.56^d	70.70 ± 3.29^a	19.48 ± 1.32^c	72.13 ± 3.76^c	7.09 ± 0.06^a
6	0.107 mg / kg Proviron	30.27 ± 1.11^c	82.63 ± 3.64^a	16.54 ± 2.25^c	83.85 ± 2.30^a	6.96 ± 0.04^a

*Values are shown in means of triplicate analysis \pm Standard Deviation. Values bearing different alphabetical superscript are significantly different ($p < 0.05$) from each other down the same column.

LEGEND: BW = Body weight, mg=milligram ; kg = kilogram. PAP = *Persea americana* pulp

Effect of different concentrations of Avocado fruit pulp extract and proviron on sperm parameters of rats induced with caffeine. The total sperm count, sperm motility, and sperm vitality of the groups treated with caffeine increased while sperm morphology (% abnormality) decreased significantly ($p < 0.05$) when compared with the group induced with caffeine without treatment (positive control).

Table 3 Effect of *Persea americana* pulp on sperm parameters in rats induced with caffeine on day forty two (42)

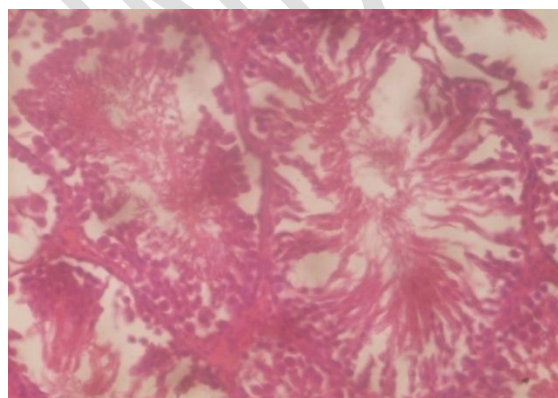
Groups	Group description	Total sperm count ($10^6/ml$)	Sperm motility (%)	Sperm morphology (%)	Sperm vitality (%)	Semen p ^H
--------	-------------------	------------------------------------	--------------------	----------------------	--------------------	----------------------

				abnormality)		
1	control	51.51±2.55 ^a	92.27 ± 1.76 ^a	4.67 ± 1.41 ^a	93.33±2.22 ^a	7.01 ± 0.06 ^a
2	caffeine	11.27 ± 0.57 ^b	21.49±2.72 ^b	37.03±6.52 ^c	23.33 ± 6.88 ^b	7.07 ± 0.08 ^a
3	100 mg /kg PAP	21.62 ± 2.86 ^c	45.24 ± 7.61 ^d	22.10 ± 2.02 ^d	64.03 ± 4.70 ^c	6.93 ± 0.07 ^a
4	300 mg/kg PAP	23.32 ± 3.01 ^c	68.32 ± 7.89 ^c	17.18 ± 4.3 ^b	72.47 ± 10.34 ^c	6.99 ± 0.07 ^a
5	500 mg/kg PAP	29.84 ± 0.87 ^c	85.91 ± 3.34 ^a	13.77 ± 2.10 ^b	83.07 ± 6.44 ^a	7.09 ± 0.06 ^a
6	0.107 mg / kg Proviron	43.70 ± 6.56 ^a	89.24 ± 2.31 ^a	9.91 ± 1.48 ^b	88.77 ± 4.79 ^a	6.96 ± 0.04 ^a

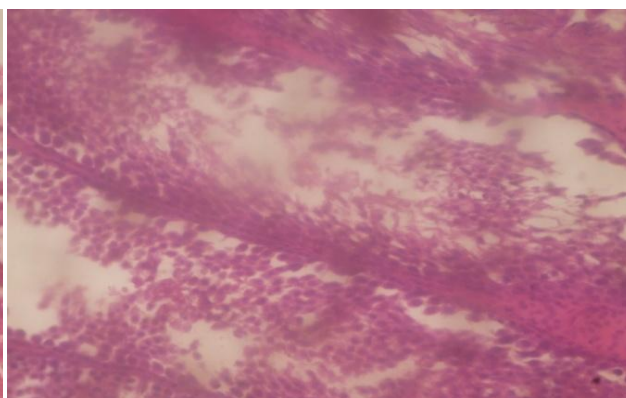
*Values are shown in means of triplicate analysis ± Standard Deviation. Values bearing different alphabetical superscript are significantly different (p<0.05) from each other down the same column.

LEGEND: BW = Body weight, mg=milligram ; kg = kilogram

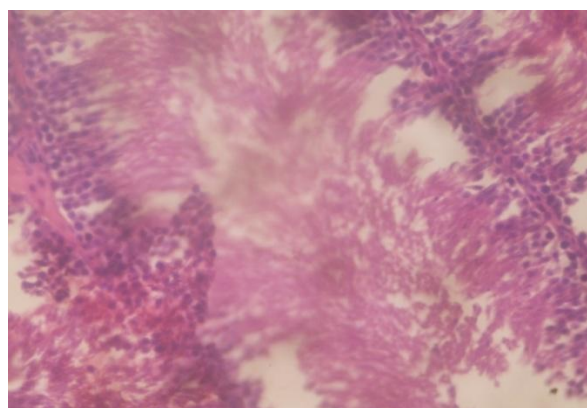
Histopathology results



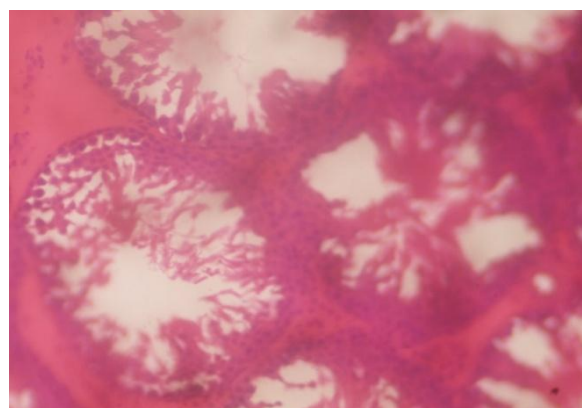
CONTROL



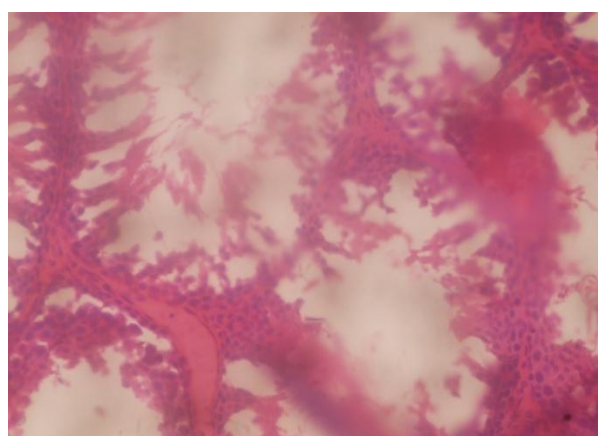
CAFFEINE



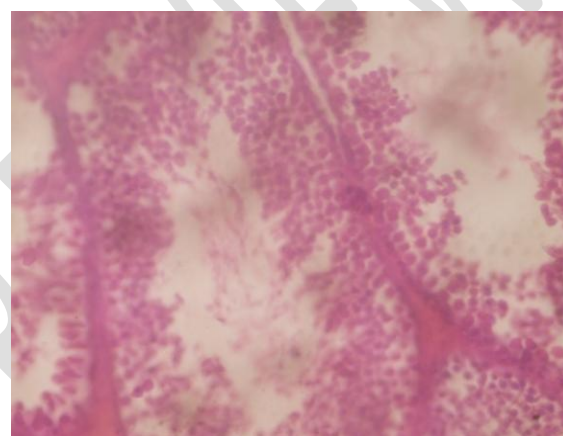
100Mg/Kg PAP



300Mg/Kg PAP



500Mg/Kg PAP

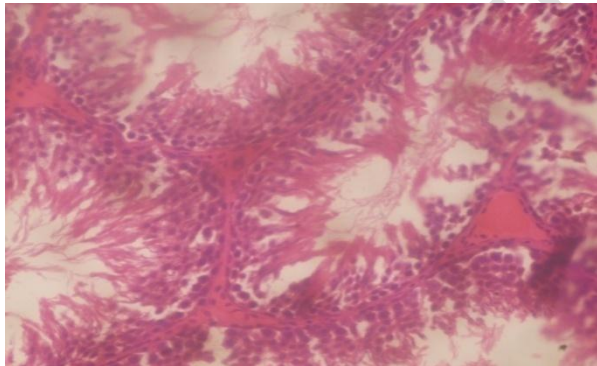


POVIRON

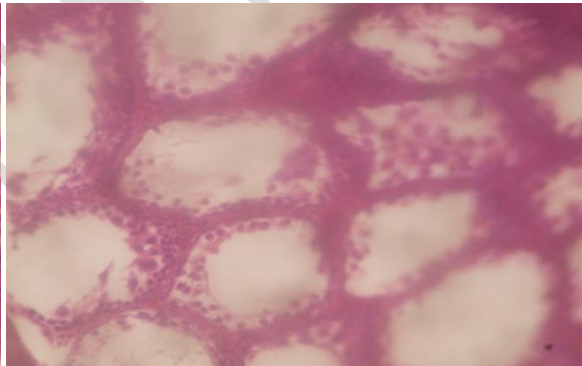
Fig. 1: Micrograph of the testes of animals on day 14 of induction

Micrograph of the testes of animals at 14 day caffeine induction showed that the control group that were not induced showed normal structure of seminiferous tubules (ST) containing spermatids. The caffeine group showed vacuolar degeneration (VD) and ballooning degeneration (BD) of seminiferous tubules(ST). Animals in 100mg/kg body weight of *Persea americana* pulp group showed distorted seminiferous tubules (ST) showing loss of elongating spermatids from all stages of spermatogenic cycles with hydropic or vacuolar degeneration (VD) and ballooning degeneration (BD). Animals in 300mg/kg body weight of *Persea americana* pulp group showed generalised seminiferous tubules oedema with hydropic or vacuolar degeneration (VD) and ballooning degeneration (BD). Animals in 500mg/kg body weight of *Persea americana* pulp group showed generalized degeneration of the Germ Cell Epithelium (GCE) and loss of elongating spermatids from all stages of spermatogenic cycles. Animals in proviron group showed severely enlarged and oedematous Seminiferous tubules (ST) with diffuse vacuolar degeneration.

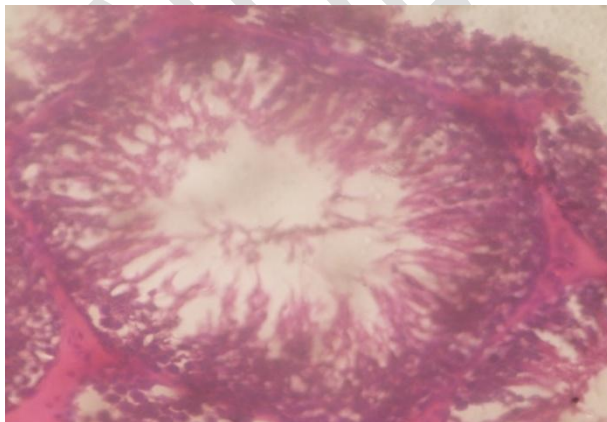
ACCEPTED REVIEW



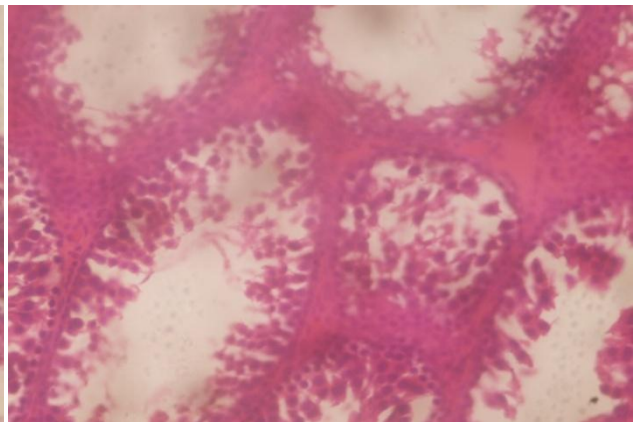
CONTROL



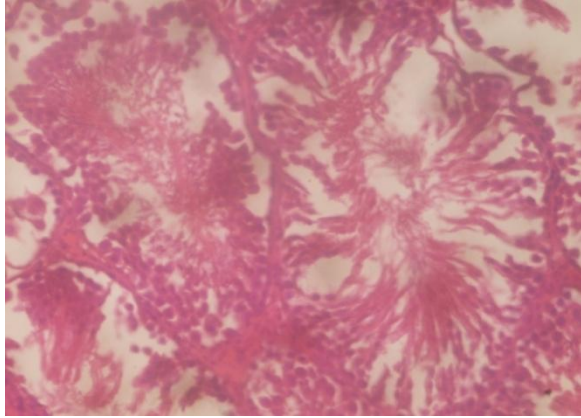
CAFFEINE



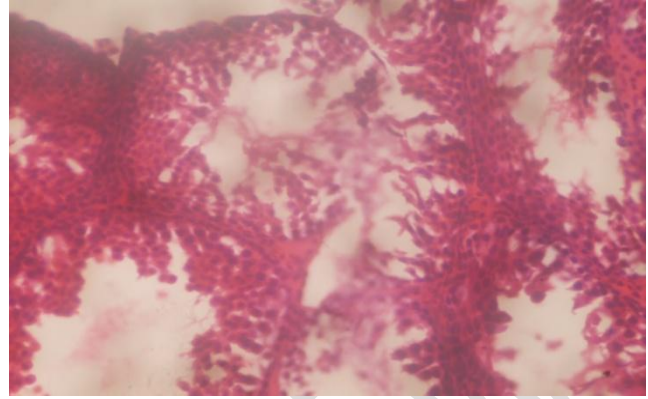
100Mg/Kg



300Mg/Kg



500Mg/Kg



PROVIRON

Fig. 2: Micrograph of the testes of the animal at 28 days (14 days treatment).

Animals in the control group showed normal seminiferous tubules (ST) containing different types of spermatogenic cells. Animals in the caffeine group after 14 days treatment showed generalized degeneration of germ cell epithelium (GCE) and loss of elongating spermatids from all stages of the spermatogenic cycle accompanied by atrophy of the leydig cells. Animals treated with 100mg/kg body weight of *Persea americana* pulp showed mild seminiferous tubules oedema with vacuolar degeneration (VD) and mature sperm cells (SC) in the lumen of the ST. At the interstitium, there is coagulative degeneration (CD) of the interstitial (leydig) cell. Animals treated with 300mg/kg body weight of *Persea americana* pulp showed generalized degeneration of Germ Cell Epithelium (GCE) and round spermatids layers of Germ Cell Epithelium. Animals treated with 500mg/kg body weight of *Persea americana* pulp showed the Germ Cell epithelium is mostly normal. At the intersitium, there is coagulative Degeneration (CD) of leydig cell. Animals treated with 0.107mg/kg body weight proviron showed moderately enlarged seminiferous Tubules. The Germ Cell Epithelium is mostly normal.

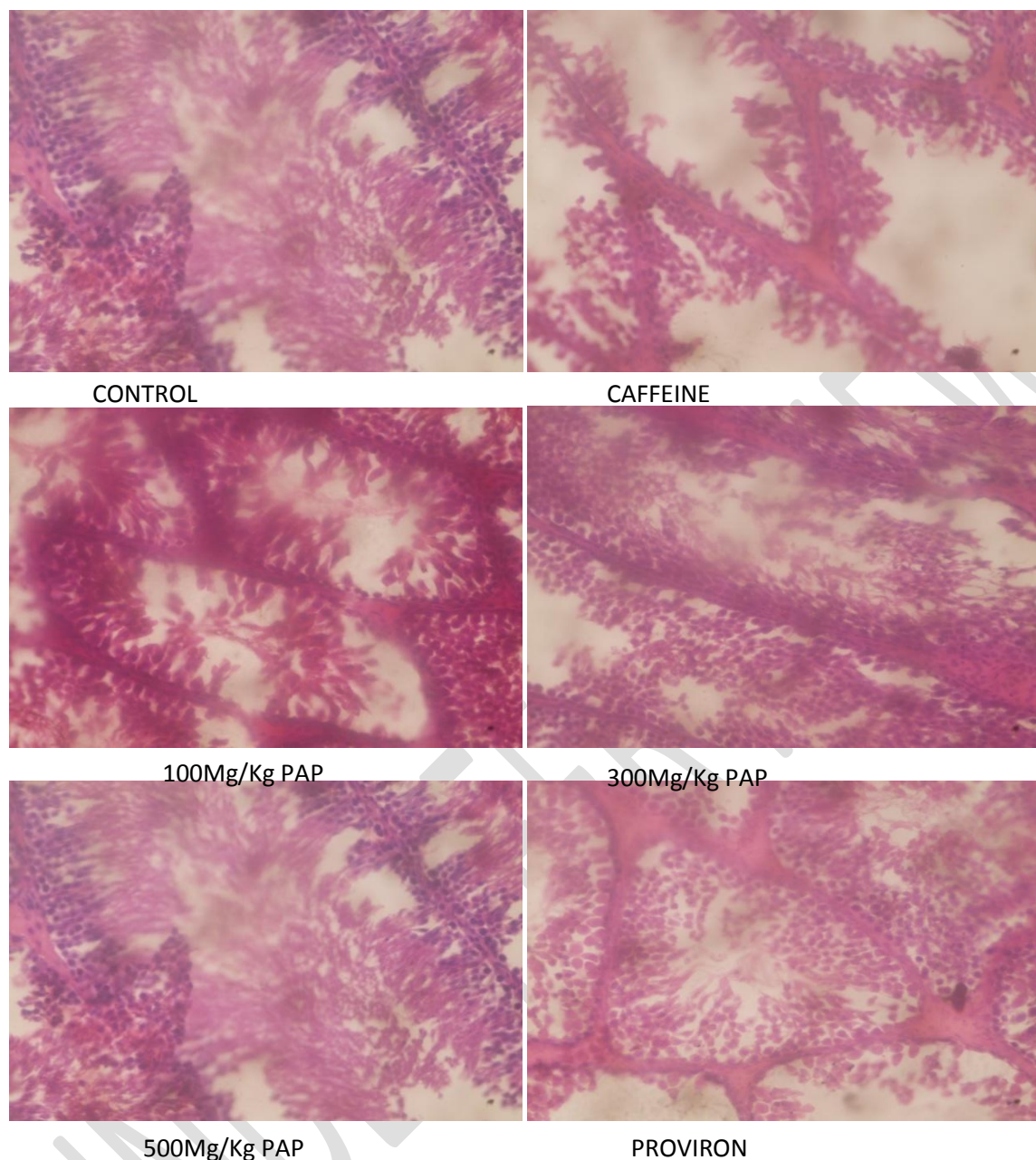


Fig. 3: Micrograph of the testes of the animals at 42 days (28 days treatment).

Animals in the control group showed better stratification of pachytene spermatocytes and round spermatids layers of germ cell epithelium. Those in caffeine group without treatment showed severely enlarged and oedematous seminiferous tubules (ST) with diffuse vacuolar degeneration. Animals treated with 100mg/kg body weight of *Persea americana* pulp showed moderately enlarged seminiferous tubules. There is moderate depletion of pachytene spermatocyte and round spermatids layers of germ cell epithelium. Animals treated with 300mg/kg body weight of *Persea americana* pulp showed moderately enlarged seminiferous tubules. The Germ Cell Epithelium is normal. Animals treated with 500mg/kg body weight of *Persea americana* pulp showed normal

seminiferous tubules containing elongating spermatids. There is better stratification of the pachytene spermatocytes. Animals treated with 0.107mg/kg body weight proviron showed normal seminiferous tubules.

DISCUSSION

There is a great concern about the rising case of infertility. Caffeine has been shown to have harmful effects on the sperm cells and also affects architectural integrity of the testes (Bassey *et al*, 2011, Ekaluo *et al*, 2014). Results from this study showed that rats induced with caffeine had significant decrease ($p < 0.05$) in sperm count and sperm motility which agrees with Ekaluo *et al* (2005, 2009). There was equally a significant increase in sperm morphology (% abnormalities) that agrees with Robbins *et al*, (2005, 2009). When sperm cells are exposed to chemical substances, it could cause pituitary hypothalamic or sex hormonal effects which consequently affects sperm production. Also exposure of sperm cells to chemicals could cause abnormalities in seminal fluid which leads to functional or structural impairment of sperm cells. Deformity in the structure of sperm cells could also arise as a consequence of naturally occurring mistakes in the spermatozoan differentiating process during spermatogenesis (Ekaluo, *et al.*, 2005). *Persea americana* pulp extract at tested doses mitigated caffeine induced toxicity on total sperm count, sperm motility, sperm vitality and sperm morphology. The mitigating effect of *persea americana* pulp extract could be attributed to its rich vitamin C content which agrees with the protective role of vitamin C (Karawya, 2006).

The results obtained from histopathological examination showed that caffeine significantly affects the histology of the testes which was evidenced in the alteration of the normal architecture and integrity of the testes of the caffeine induced rats thereby resulting in the necrosis of spermatogenic cells (sertoli cells and the leydig cells). This is in agreement with the findings of Ezim and Abarikwu 2022, they reported that CAFF decreased seminiferous epithelia thickness and spermatogenesis score index and increased the number of tubules with abnormal histological features, This is in agreement with the findings of Bassey *et al*, (2011) and Ekaluo *et al*, (2014). The sertoli cells plays important roles in the overall development of the testes while the leydig cells are responsible for testosterone production and spermatogenesis. (Souvix *et al*, 2013). The degenerative changes that occurred in the histology of rats induced with caffeine could be the cause of distorted spermatogenesis (Mann, 1974) which consequently resulted in a significant decrease in the sperm count, sperm motility, sperm vitality, recorded in rats administered with caffeine. According to the report of Glover and Assinder (2006) and Ekaluo (2011), disruption on fertility in male animals has direct connection with the disruption of spermatogenesis. According to report of Makker *et al*, (2009). *Persea americana* pulp extract at different doses mitigated the caffeine induced toxicity on the histology of the testes. This is evidenced in the restoration of the spermatogenic cell to their normal architecture and integrity which was dose dependent. 500mg/kg dose had the best effect.

CONCLUSION

This study reveals that ethanol extract of *Persea americana* pulp caused significant increase in total sperm count, sperm motility, sperm morphology, sperm vitality, sperm morphology in caffeine induced rats in dose and duration dependent manner. *Peasea americana* pulp extract also militigated the caffeine induced toxicity on the histology of the testes.

REFERENCES

Bagchi, D. (2006) Nutraceutical and Functional Food Regulation in the united States and around the world. *Toxicity*.22(1): 1-3

BasseyR.B.,Yama O.E. , Osinubu, A.A., Noroha C.C. and Okanlawon A.(2011).Effects of TanitianNowt Dietary Supplement on Caffeine Induced Testicular Histopathological Alterations in Adult Sprague-Dawley rats. *Middle East Fertility Society Journal* 16:61-66

Best B.(1999). Is caffeine a health hazard? *American Journal.Psychiatry*(156):223-228.

Bligher, F.G. and Dyer, W.J.(1959). A Rapid Methof of Total Lipid Extraction and Purification..*Journal of Biochemistry and Physiology*.37(4): 911-917

Chidrawar V.R.,Chitme H.R., Patel K.N., and Vadalia K.R.(2011).Effects of Cynodondactylon on Stress Induced Infertility in Male Rats. *Journal of Young Pharmacology* 3(1):26-35

Dahanuka, S.A., Kulkam, R.A., and Ree N.N.(2000).Pharmacology of Medicinal Plants and Natural Products. *Indian Journal of Pharmacology*.32:81-118.

Christian M.S. and Brent R.L.(2001).Evaluation of the Reproductive and Developmental Risks of Caffeine. *Teratelog*,64:51-78..

Ekalu U.B. ,Udokpo A.G., Udofia U. U. and Ajang R. O.(2005). Comparative toxicity of five commonly used analgesics in sperm count and sperm head abnormalities. *Global Journal of Pure and AplliedSciences* . 11:81-84.

Ekalu U. B., Udokpo A. G.And Ikpeme E. U.,(2008).Effect of Chloroquine on sperm count and weight of testes in male rats..*Journal of Pure and Apllied Science*. 14:175-177

Ekalu U.B., Ikpeme E.V., Etta, S.E. ,Eren, F.A. and Daniel I.O.(2014) Effect of soursopAnnonamuricata fruit extract on sperm toxicity induced by caffeine in albino rats..*Journal of Medical Science* 13(1):67-71.

Ekalu U.B.,Ikpeme E.V., and Udokpo A.E.(2009).Sperm Head Abnormality and Mutagenic Effects of Asprin,Paracetamol, and Caffeine Containing analgelsics in rats . *The internet Journal of Toxicology* 7(1):1-9

Ezim, O.Eand Abarikwu, S.O. (2022). Fluted pumpkin seeds protect the spermatogenesis score index and testicular histology of caffeine treated rats. *Andrologia* DOI: [10.1111/and.14578](https://doi.org/10.1111/and.14578)

Glover A. and Assinder S.J.(2006). Acute Exposure of Adult Male Rats to Dietary Phytoestrogens Reduces Fecundity and alters Epididymal Steroid Hormone Receptor Expression. *Journal of Endocrinology* 189:565-573

Karawya, F.S..(2006). The Protective Effect Of Vitamin C on Azothioprine Induced Seminiferous Tubules Structural and Cytogenetic Toxicity in Albino Rats. *Cancer Therapy* 4:125-134.

Launch, I.A., Oimer, R.D., and Srous T. (2007). Caffenism: History Clinical Features, Diagnosis and Treatment. IN: Caffeine and Activation Theory: Effects in Health and Behaviour. *C.R.S Press, Bocaratom p. 33-34.*

Longe J.L.(2002)The Gale Encyclopeddia of Alternative Medicine. Thompson-Gale .p.521.

Lopez L.M., Grimes, D.A., and Schuz, K.F.(2006) on-Hormonal Drugs for Contraception in Men: A Systematic Review. *Obstet. Gynecology*.60:746-752.

Longe J.L.(2002)The Gale Encyclopeddia of Alternative Medicine. *Thompson-Gale .p.521.*

Mann T.(1974). Secretion Function of the Prostate of the Seminal Vesicle and other Male Accesory Organs of Reproduction and Fertility. *37:179-188.*

Markker, K., Agarwal, A., and Sharma, K. (2009).Oxidative Stress and Male Fertility. *Indian Journal Of Medical Research. 129:357-367*

Mann T.(1974). Secretion Function of the Prostate of the Seminal Vesicle and other Male Accesory Organs of Reproduction and Fertility.*37:179-188.*

Robbins W. A., Vine M. F., TroungK.Y.,and Everson R.B.(1997).Use of flouresenceInsituHybridisation to access effects of smoking , caffeine and alcohol on aneuploidy load in sperm of healthy mem . *Environmental Molecular Mutagenesis*.30:175-183

Salgueiro, L.R., Caleleiro, C., Goncalves, M.J. and Proenca C.A.(2003).Anti-microbial Activity and Chemical Compositionof the Essential Oils of the Lippiagraveolensfrom Gautonala. *Plant Medicine*69(1):80-83.

Santos M.A. ,Benai B.V. , Solvia R.C. andBortuny R.C.(2014).Profile of bioactive compounds in avocado oil:Inflence of dehydration, temperature and extraction method. *Journal of the American oil Chemical Society . 91:19-27*

Singh A., (2008).Reversible Anti-fertility Effects of Aqueous Leaf Extract of Allandacathartica L. in Male Laboratory Mice. *Journal of Andrology*.40:337-345

Souvix R., Noorjama R., Faiqa A., Satyajit M., and Santanu S. (2013). Naringenin Attenuates Testicular Damage Germ Cell Death and Oxidative Stress in Streptocin induced Diabetic Rats. *Journal of Applied Biomedicine* 11:195-208.

Talwar, .P., Raghuvanshi, P., Misra, R., Mukherjee S., and Shan S. (1997) Plant Immunomodulators for Termination of unwanted Prenancy and for Contraception and Reproductive Health. *Immunological Cell Biology*. 75:190-192

Tripath K.D. (2005) Essentials of Medical Pharmacology. Jaypee Brothers Medical Publishers, India.

UNDER PEER REVIEW