

Case study

Colon Cancer With Mediastinal Metastasis

ABSTRACT :

Background :the patient had a CAF(complete atrial fibrillation) as a comorbidity

Objectif :

The most common sites of colon cancer metastasis are the regional lymph nodes, liver, lung, bone and brain

The patient was 65 years old and had CAF as a comorbidity. She was consulted for a recent dyspnea evolving in a context of altered general state without any digestive sign. A thoracic scan showed a medial mass measuring 53*56*60mm. The lung biopsy revealed a muscular adenocarcinoma of colorectal origin with immunohistochemical expression of cytokeratin 7 (CK7), 20 and cytokeratin (CK) AE1/AE3, CDX2. The Pet Scan confirmed the existence of a hypermetabolic left anterosuperior medial mass in addition to a focal digestive hypermetabolism of the right colonic wall.

A colonoscopy was performed and showed a tumor process in the right colon with a histological and immunohistochemical profile compatible with that of the mediastinal metastasis. The tumor was MSS (microsatellite stable), RAS (rat sarcoma) and BRAF(v-raf murine sarcoma viral oncogene homolog B1) wild type. The patient received a 3-month folfox-panitimumab combination with good tolerance and a partial response of about 50% on the metastasis.

Conclusions:this case report provide a highly unusual instance of colon adenocarcinoma with extensive mediastinal lymph nodes metastasis.

1)KEYWORDS:colon cancer ,chemotherapy ,mediastinal metastasis, colon adenocarcinoma,mediastinal mass,thoracic scan

INTRODUCTION

“Colorectal cancer is a common cancer 2nd leading cause of cancer death after lung cancer in the world with 935,000 deaths in 2020” [1].

“The most likely sites of metastasis are regional lymph nodes, liver, lung, bone and brain” [2].

“Colorectal carcinoma is the second biggest cancer responsible for mortality. Lung metastasis is the commonest, following the liver. It is not uncommon to perform pulmonary metastasectomy and identify mediastinal metastasis” [3].

In this study, an extremely rare case of colon adenocarcinoma with extensive metastasis to the mediastinal lymph nodes without any other organ involvement is presented.

2)CASE PRESENTATION :

“Colorectal cancer (CRC) is the second most common type of cancer in women and the third most common in men worldwide” [4]

“It is also the second leading cause of cancer-related death in the United States” [5]. “About one-third of patients who develop CRC succumb to the disease” [5]. “CRC is diagnosed in the majority of patients after the onset of symptoms such as rectal bleeding, change in bowel habits, bowel obstruction, and weight loss, or after the identification of occult bleeding” [6,7].

“However, implementation of CRC screening guidelines has improved detection of premalignant polyps and asymptomatic CRC at an early stage, and thus improved disease outcomes” [6,7].

“The most common sites of metastasis are regional lymph nodes, liver, lung, bone, and brain” [8]. This study presents an extremely rare case of colonic adenocarcinoma with extensive metastasis to multiple mediastinal lymph nodes without any other organ involvement.

The patient was 65 years old and had ACFA as a comorbidity. She was consulted for a recent dyspnea evolving in a context of altered general state without any digestive sign. A thoracic scan showed a medial mass measuring 53*56*60mm. **Figure 1,2,3**

The lung biopsy revealed a muscular adenocarcinoma of colorectal origin with immunohistochemical expression of cytokeratin 7 (CK7), 20 and cytokeratin (CK) AE1/AE3, CDX2

Figure 5,6,7

The patient did not have undergone colonoscopy previously. The Pet Scan confirmed the existence of a hypermetabolic left anterosuperior medial mass in addition to a focal digestive hypermetabolism of the right colonic wall.

Figure ,3,4

A colonoscopy was performed and showed a tumor process in the right colon with a histological and immunohistochemical profile compatible with that of the mediastinal metastasis. The tumor was MSS, RAS and BRAF wild type. The patient received a 3-month folfox-panitimumab combination with good tolerance and a partial response of about 50% on the metastasis.

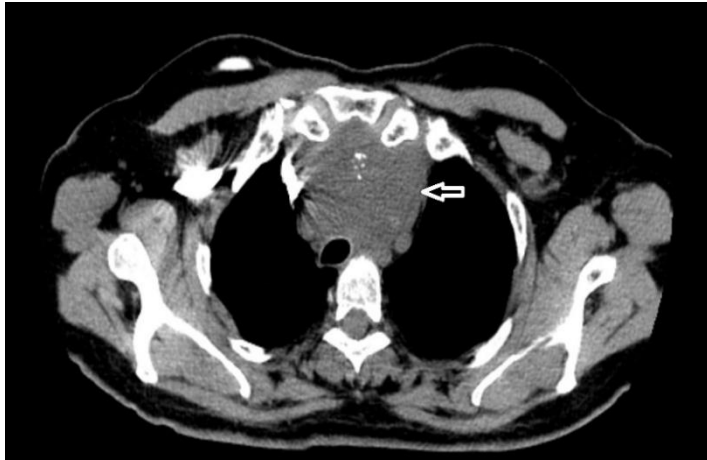

Figure1 : : mediastinal mass (53*56*60mm)

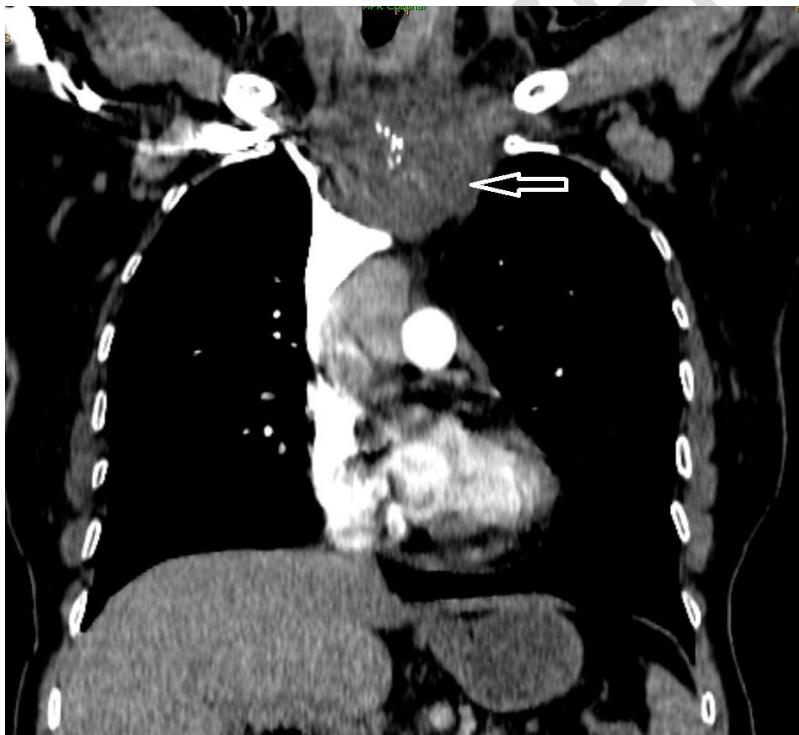


Figure2 : : mediastinal mass (53*56*60mm)

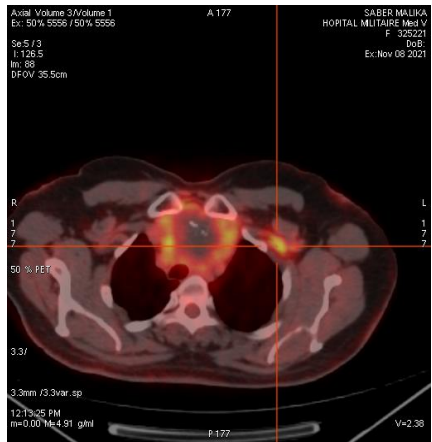


Figure3 : a left anterosuperior mediastinal mass of heterogeneous fixation marked at its periphery measuring 66*64mm of transverse axis and extending over a height of 67 mm without apparent invasion of the regional mediastinal structures

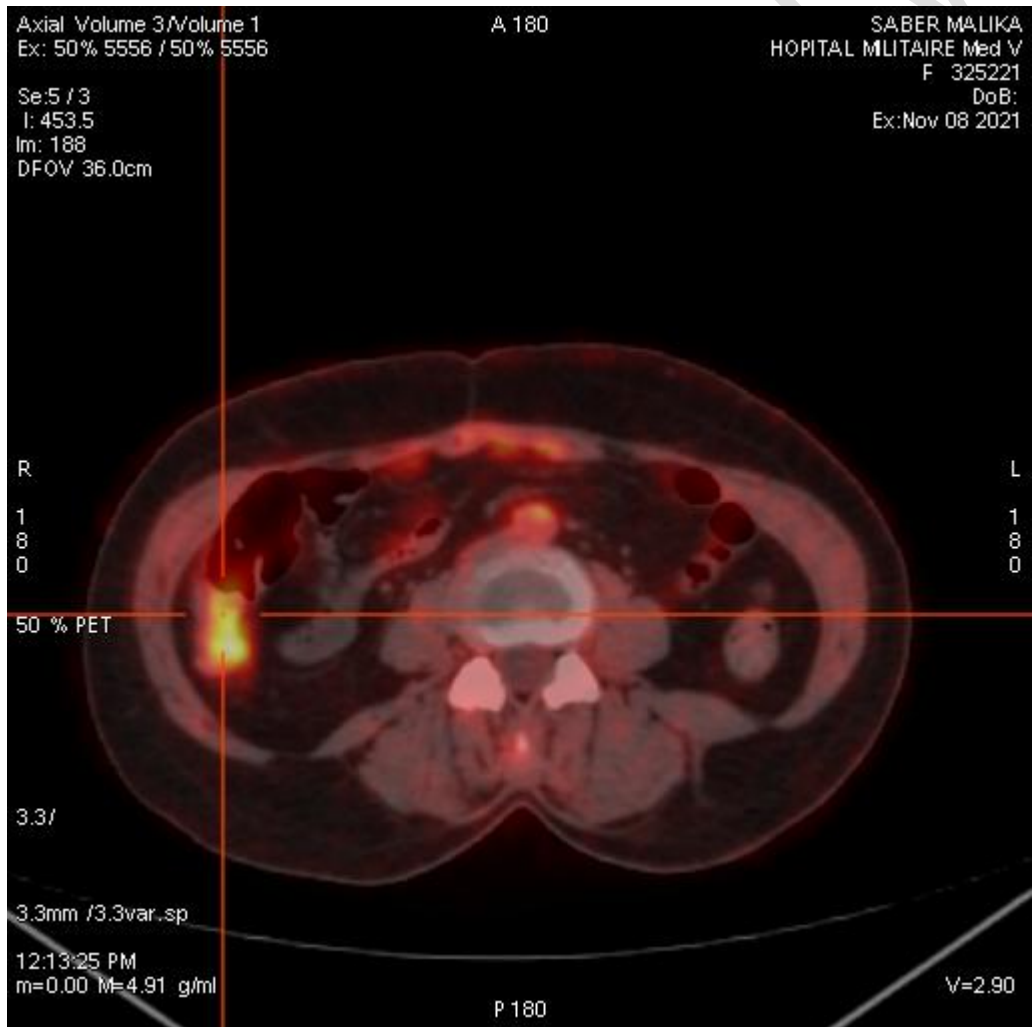


Figure4 : Focal digestive hypermetabolic of the right colonic wall

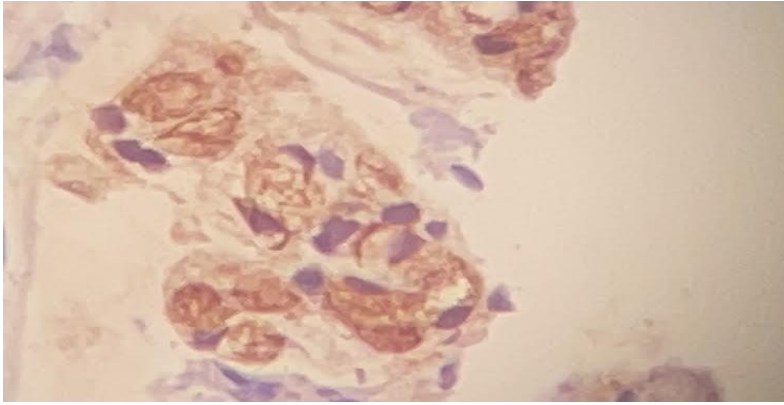


Figure 5: Mucosecreting independent cell proliferation in (Chestnut ring)

CK 20 +(cytokeratine)

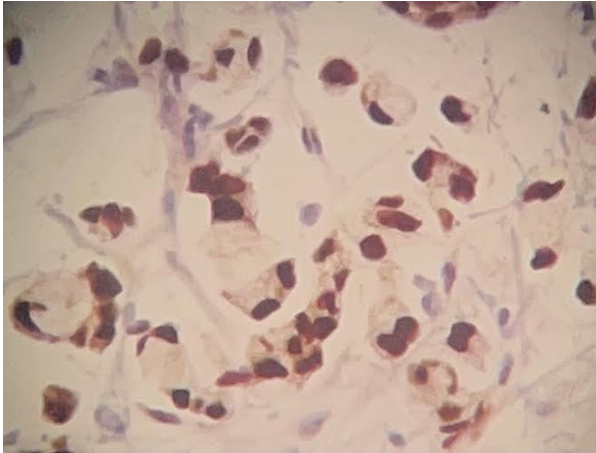


Figure6: Mucosecreting independent cell proliferation in (Chestnut ring)

CDX2+

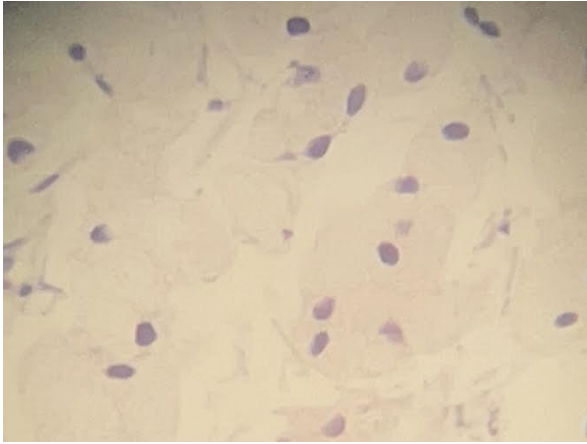


Figure 7: Mucosecreting independent cell proliferation in (Chestnut ring) CK7 (cytokeratine)– RE –TTF1 –(thyroid transcription factor 1)

Biological exams were normal

LDH 179ui/l

hemoglobin 12g/dl

Thyroglobulin:48.12 ng/ml

Ca 15-3:15.8 iu/l

Ca 125 6.3 ui/l

Ca 19-9 <2.060ui/ml CEA:12.65 ng/ml

DISCUSSION :

Our case presented a mediastinal process that the biopsy revealed a mucinous adenocarcinoma of digestive origin. Mediastinal metastasis of colorectal origin without hepatic metastasis is extremely rare. “Only 12 cases of mediastinal metastasis from colorectal cancer have been reported in the English literature table 1” [9,10]

Table 1. Comparative overview of 12 cases of mediastinal metastasis

<i>Case number</i>	<i>Reference</i>	<i>Year published</i>	<i>Age</i>	<i>Sex</i>	<i>Primary location</i>	<i>Primary stage</i>	<i>Adjuvant chemotherapy</i>	<i>Time after Primary resection(months)</i>	<i>Metastasis location</i>
1	Vetto et al. [3]	1991	60	M	Hepatic flexure	IIIb	Not listed	12	Right lobe liver, mediastinum
2	Kuba et al. [4]	1999	60	F	Sigmoid	IIIb	Not listed	33	Left ovary, mediastinum
3	Musullam et al. [5]	2008	67	M	Rectosigmoid	IIIb	Yes	26	Mediastinum
4	Yavaş et al. [6]	2009	57	M	Ascending	IIIa	5-Fluorouracil	Not listed	Mediastinum
5	Sano et al. [7]	2011	29	M	Ascending	IVa	5-Fluorouracil	24	Liver, mediastinum
6	Iwata et al. [8]	2012	75	M	Ascending and transverse	IIIa	Capecitabine	42	Liver, mediastinum
7	Matsuda et al. [9]	2014	65	M	Sigmoid	IIIc	Tegafur-uracil	101	Mediastinum

8	<i>Matsuda et al. [9]</i>	2014	50	<i>M</i>	<i>Rectum</i>	<i>IIIc</i>	<i>No</i>	96	<i>Mediastinum</i>
9	<i>Halabi et al. [10]</i>	2014	44	<i>M</i>	<i>Ascending</i>	<i>IIIa</i>	<i>Folinic acid, fluorouracil, oxaliplatin, bevacizumab</i>	22	<i>Mediastinum</i>
10	<i>Shirakawa et al. [11]</i>	2015	65	<i>M</i>	<i>Rectum</i>	<i>IIIa</i>	<i>Tegafur-uracil, 5-fluorouracil, leucovorin and oxaliplatin</i>	55	<i>Liver, mediastinum</i>
11	<i>Rodríguez-López et al. [12]</i>	2016	45	<i>M</i>	<i>Rectum</i>	<i>IVa</i>	<i>Folinic acid, fluorouracil and oxaliplatin, bevacizumab</i>	–	<i>Mediastinum</i>
12	<i>Toda et al. [13]</i>	2017	59	<i>M</i>	<i>Ascending</i>	<i>IIIb</i>	<i>Yes</i>	32	<i>Mediastinum</i>

“Re-metastasis of colon cancer to mediastinal lymph nodes from a lung metastasis is rare; however, it has been reported in a small number of studies”[11]“Re-metastasis from the liver to lymph nodes draining the liver is even rarer, but has also been reported in the literature” [12].

However, in the present case, due to the large mediastinal mass, these were not surgically resected and chemotherapy+ targeted therapy was administered instead with net clinical benefit.

3)CONCLUSIONS:

this case report provide a highly unusual instance of colon adenocarcinoma with extensive mediastinal lymph nodes metastasis. **treatment** involving a three months folfox panitumumab combination yielded a favorable partial response of approximately 50% on the metastasis, demonstrating a promising therapeutic outcome in this atypical presentation.

4)LIST OF ABBREVIATIONS:

CAF:complete atrial fibrillation

MSS: microsatellite stable

RAS :rat sarcoma

BRAF:v-raf murine sarcoma viral oncogene homolog B1

CEA :carcinoembryonic antigen

5)DECLARATIONS :

Ethics approval and consent to participate :

UNIVERSITY Mohammed V souissi RABAT Morocco faculty of medecine approved the study

Consent for publication :

The patient consent the publication of the personnal data

Availability of data and material :

Medical oncology departement of the Military Hospital RABAT Morocco

5)REFERENCES:

- [1].<https://www.who.int/fr/news-room/fact-sheets/detail/cancer>
- [2]. El-Halabi MM, Chaaban SA, Meouchy J, Page S, Salyers Jr WJ. Colon cancer metastasis to mediastinal lymph nodes without liver or lung involvement: a case report. *Oncology letters*. 2014 Nov 1;8(5):2221-4.
- [3]. Habib AM, Kassianides X, Chan S, Loubani M, Qadri S. Colorectal Cancer Presenting as Single Pulmonary Hilar Lymph Node Metastasis. *Case Reports in Surgery*. 2018 Jan 18;2018.
- [4]. Jemal A, Bray F, Center MM, Ferlay J, Ward E et Forman D : Global cancer statistics. *CA Cancer J Clin* 61 : 69 90, 2011.
- [5]. Siegel R, Ma J, Zou Z et Jemal A : Statistiques sur le cancer, 2014. *CA Cancer J Clin* 64 : 9 29, 2014.
- [6]. Levin B, Lieberman DA, McFarland B, et al ;groupeconsultatif sur le cancer colorectal de l'American Cancer Society ; groupe de travail multisociétéaméricain ; comité du cancer du côlon de l'American College of Radiology : Screening and surveillance for the early detection of colorectal cancer and adenomatous polyps, 2008 : a joint guideline from the American Cancer Society, the US Multi Society Task Force on Colorectal Cancer, and the American College of Radiology. *CA Cancer J Clin* 58 : 130 160, 2008.
- [7]. U.S. Preventive Services TaskForce: Screening for colorectal cancer: U.S. Preventive Services Task Force RecommendationStatement. *Ann Intern Med* 149:627637, 2008.
- [8]. Hess KR, Varadhachary GR, Taylor SH, Wei W, Raber MN, Lenzi R et Abbruzzese JL : Metastatic patterns in adenocarcinoma. *Cancer* 106 : 1624 1633, 2006
- [9]. Vetto JT, Cohen AM. Isolated spread of hepatic metastatic disease to a mediastinal lymph node. Report of a case and review of pertinent anatomy and literature. *Dis Colon Rectum* 1991;34:1128–1130.
- [10]. Toda K, Kawada K, Sakai Y, Izum H. Metachronous mediastinal lymph node metastasis from ascending colon cancer: a case report and literature review. *Int J Surg Case Rep* 2017;41:336–339.
- [11]. Szöke T, Kortner A, Neu R, Grosser C, Szilkvari Z, Wiebe K and Hofmann HS : Is the mediastinal lymphadenectomy during pulmonary metastasectomy of colorectal cancer necessary ? *Interact Cardiovasc Thorac Surg* 10 : 694 698, 2010.
- [12]. August DA, Sugarbaker PH et Schneider PD : Lymphatic dissemination of hepatic metastases. Implications pour le suivi et le traitement des patients atteints de cancer colorectal. *Cancer* 55 : 1490 1494, 1985.