

DETECTING DENTAL CARIES THROUGH CAPTURED IMAGES USING THE MACHINE LEARNING TECHNOLOGY TEACHABLE MACHINE.

SUMMARY

Objective:The objective is to utilize open-source artificial intelligence tool Teachable Machine to detect dental caries.**Subjects and research methods:**cross-sectional description.The research involved analyzing a total of 2,063 digital images, comprising 1,563 images showing dental caries and 500 images depicting teeth without any signs of dental caries. **Results:**Among the 1,563 images featuring dental caries, the recognition tool accurately identified 1,512 images (96%), while 51 images remained undetected, representing 4% of the total.Among the entire set of 2,063 images, encompassing both those with and without dental caries, 1,512 images were accurately identified (73.3%), while 551 images (26.7%) were not detected to have dental caries. **Conclusion:**The study on 1,563 images with dental caries using the Teachable Machine learning tool yielded promising results, achieving a high accuracy rate of 96%. However, when applied to the mixed dataset of 2,063 images, the accuracy rate for identifying images with dental caries dropped to only 73.3. The variance is ascribed to the initial stages of dental caries, which closely resemble the color of healthy tooth enamel. Therefore, the research team proposes the necessity for additional data on this form of decay to enhance classification and identification accuracy.

Keywords:*artificial intelligence; machine learning; dental caries; teachable machine.*

I. INTRODUCTION

In modern times, the notion of Artificial Intelligence (AI) is commonplace. First termed by Arther Samuel in the 1950s, AI has gained notable momentum, particularly with Google's launch of Machine Learning (ML) systems in 2014.Machine Learning, a subset of AI, involves the research and construction of data repositories enabling systems to autonomously "learn" from the data provided, thus performing tasks previously exclusive to human capability. AI is being applied and supported across various domains including manufacturing, services, transportation, healthcare, entertainment, and information technology[1], [2], [3]. In Dentistry and Maxillofacial fields, AI is increasingly utilized to support oral disease consultations, dental caries diagnoses, treatment plan simulations for implant surgery, and outcome predictions post-orthodontic treatment. This contributes to improving the efficiency of examinations and treatments while simultaneously enhancing the quality of care provided.To accomplish this goal, it's crucial to create comprehensive datasets that allow machine learning systems to offer highly accurate diagnostic recommendations, ultimately saving time, effort, and improving workflow efficiency.Worldwide, researchers such as Srivastava have investigated and utilized machine learning tools to aid in the automated diagnosis of oral diseases using X-ray images[4]. Berdouses and colleagues also conducted research in 2015 on diagnosing dental caries using a machine learning tool on 103 images[5]. In Vietnam, author Vo Truong Nhu Ngoc has also published research on the method of automatically diagnosing complications of wisdom teeth based on X-ray images[6]. However, the accessibility and proficiency in the AI domain for healthcare professionals continue to be intricate, often

relying heavily on the expertise of information technology teams. Hence, the authors conducted research on utilizing the open-source tool Teachable Machine[7] to generate a dataset on dental caries pathology. The objective is to train machine learning models that can support healthcare professionals and aid in their initial diagnostic procedures.

II. SUBJECTS AND METHODS

2.1. Research Subjects:

Intraoral images diagnosed with dental caries.

Selection Criteria: Digital images diagnosed by clinicians with clinical evidence of dental caries lesions, clearly showing details such as color changes like yellow, brown, black spots, and deep cavities exposing dentin.

Exclusion Criteria: Images that do not meet standards (noisy images, blurry images, images with unclear lesions, images in incorrect formats) and do not meet the selection criteria mentioned above.

2.2. Research Methodology:

2.2.1. Study Period: From April 2023 to January 2024.

2.2.2. Study Location: The research was conducted at Becamex International Hospital, Binh Duong Province, Vietnam

2.2.3. Methodology: cross-sectional description. We performed purposive sampling and assembled a dataset comprising 1,563 images displaying dental caries lesions. These images were clinically diagnosed by dentists who identified dental caries lesions during examinations, confirming their presence based on the images. Furthermore, we included 500 images of healthy teeth for comparative analysis. The characteristics of the imaging angles for dental caries lesions were: buccal, lingual, mesial, distal, occlusal.

2.2.4. Research Instruments: Intra-Oral Digital Camera GX-C300; Intraoral mirrors; Standard dental examination kit.



Figure 1. Intra-Oral Digital Camera GX-C300 (A); Intraoral mirror set (B).

The computer connected to the network utilizes the open-source platform Teachable Machine (TM) to train machine learning models with basic training parameters (epochs 50, Batch size 16; Learning rate 0.001). TM will utilize a pre-trained image recognition network named MobileNet to accurately identify patterns previously trained using the provided dataset [8].

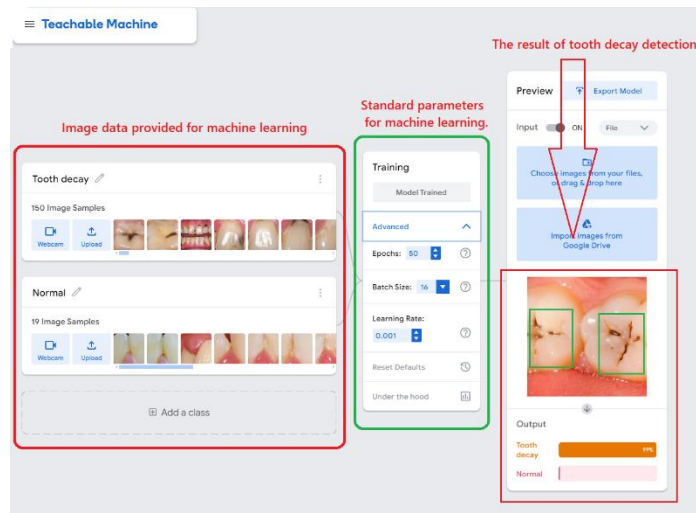


Figure 2. Model training process and results on Teachable Machine.

2.2.5. Data processing: SPSS 20.0 software and various statistical algorithms were utilized.

2.2.6. The ethical approval for the study from the Institutional Ethics Committee of Becamex International Hospital was granted on **March 12, 2023**

III. RESULTS:

3.1 Study sample: In this study, we conducted research with 1,563 images exhibiting dental caries lesions and 500 images of healthy teeth (for comparison).

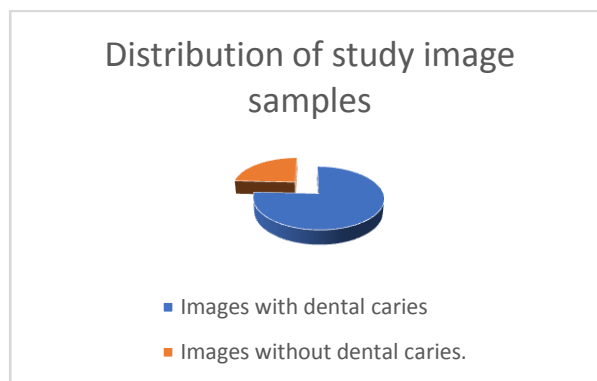


Chart 1. Distribution of the research sample.

3.2. Dental Caries Detection Rates Based on the Caries-Identified Dataset (n=1,563)

N=1563	Dental Caries	No Dental Caries
	1,512 (96%)	51 (4%)

Table 1. Detection rates of images with dental caries and without dental caries.

Among the 1,563 images featuring dental caries lesions, the Teachable Machine recognition tool accurately identified 1,512 images as having such lesions, constituting 96% of the dataset. However, 51 images were not detected to have dental caries lesions, making up 4% of the total.

3.3. Dental Caries Detection Rates Based on the Mixed Dataset (n=2,063)

N=2063	Dental Caries	No Dental Caries
	1,512 (73,3%)	551 (26.7%)

Table 2. Detection rates of images with dental caries and without dental caries.

In the combined dataset of 2,063 images, including both those with and without dental caries lesions, the Teachable Machine recognition tool accurately identified 1512 images as having such lesions, making up 73.3% of the dataset. However, 551 images were not detected to have dental caries lesions, representing 26.7% of the total.

IV. DISCUSSION:

The application of artificial intelligence remains a relatively nascent and challenging domain for healthcare practitioners. The Teachable Machine machine learning toolkit, known for its simplicity and accessibility, offers a convenient solution for medical personnel to easily engage with and deploy effectively. With a remarkable accuracy rate of 96% in correctly identifying deep dental caries, this tool's effectiveness exceeds that of a study conducted by Hyunja Jeong in 2020, which achieved an accuracy rate of 92.1% in distinguishing between toothed and toothless tongues using Teachable Machine[9]. In the Vietnamese context, Tran Sinh Bien has successfully applied Teachable Machine to real-time facial recognition, achieving a flawless recognition rate of 100%[10]. These findings underscore the robust reliability of Teachable Machine in the identification of bodily features overall, and dental pathologies in particular, thereby paving the way for preliminary explorations of its application across various medical domains.

V. CONCLUSION:

The research outcomes from analyzing 1,563 images featuring dental caries lesions with the Teachable Machine machine learning tool reveal promising results, achieving a detection accuracy rate of 96%. In the combined dataset of 2,063 images encompassing both images with and without dental caries lesions, the accuracy rate for detecting images with dental caries lesions stands at 73.3%. This difference is attributed to the presence of early-stage dental caries lesions, where the lesion color resembles that of normal tooth enamel. Therefore, the research team suggests the need for additional data on this type of lesion to improve classification and detection accuracy.

REFERENCES

- [1] P. López-Úbeda, M. C. Díaz-Galiano, T. Martín-Noguerol, A. Ureña-López, M.-T. Martín-Valdivia, and A. Luna, "Detection of unexpected findings in radiology reports: A comparative study of machine learning approaches," *Expert Systems with Applications*, vol. 160, p. 113647, 2020/12/01/ 2020, doi: <https://doi.org/10.1016/j.eswa.2020.113647>.
- [2] C. Chamunyonga, C. Edwards, P. Caldwell, P. Rutledge, and J. Burbery, "The Impact of Artificial Intelligence and Machine Learning in Radiation Therapy: Considerations for Future Curriculum Enhancement," *Journal of Medical Imaging and Radiation Sciences*, vol. 51, no. 2, pp. 214-220, 2020, doi: 10.1016/j.jmir.2020.01.008.
- [3] R. Abdalla-Aslan, T. Yeshua, D. Kabla, I. Leichter, and C. Nadler, "An artificial intelligence system using machine-learning for automatic detection and classification of dental restorations in panoramic radiography," *Oral Surgery, Oral*

Medicine, Oral Pathology and Oral Radiology, vol. 130, no. 5, pp. 593-602, 2020, doi: 10.1016/j.oooo.2020.05.012.

- [4] M. M. Srivastava, P. Kumar, L. Pradhan, and S. Varadarajan, "Detection of tooth caries in bitewing radiographs using deep learning," *arXiv preprint arXiv:1711.07312*, 2017.
- [5] E. D. Berdouses, G. D. Koutsouri, E. E. Tripoliti, G. K. Matsopoulos, C. J. Oulis, and D. I. Fotiadis, "A computer-aided automated methodology for the detection and classification of occlusal caries from photographic color images," (in eng), *Comput Biol Med*, vol. 62, pp. 119-35, Jul 2015, doi: 10.1016/j.compbiomed.2015.04.016.
- [6] V. T. N. Ngoc *et al.*, "The Combination of Adaptive Convolutional Neural Network and Bag of Visual Words in Automatic Diagnosis of Third Molar Complications on Dental X-Ray Images," (in eng), *Diagnostics (Basel)*, vol. 10, no. 4, Apr 9 2020, doi: 10.3390/diagnostics10040209.
- [7] M. Carney *et al.*, "Teachable Machine: Approachable Web-Based Tool for Exploring Machine Learning Classification," presented at the Extended Abstracts of the 2020 CHI Conference on Human Factors in Computing Systems, Honolulu, 2020. [Online]. Available: <https://doi.org/10.1145/3334480.3382839>.
- [8] H. Pan, Z. Pang, Y. Wang, Y. Wang, and L. Chen, "A New Image Recognition and Classification Method Combining Transfer Learning Algorithm and MobileNet Model for Welding Defects," *IEEE Access*, vol. 8, pp. 119951-119960, 2020, doi: 10.1109/ACCESS.2020.3005450.
- [9] H. Jeong, "Feasibility study of google's teachable machine in diagnosis of tooth-marked tongue," *Journal of Dental Hygiene Science*, vol. 20, no. 4, pp. 206-212, 2020, doi: <https://doi.org/10.17135/jdhs.2020.20.4.206>.
- [10] T. S. Biên and Đ. T. Chang, "Application of teachable machine in real-time face recognition," *Journal of Science and Technology*, vol. 59, no. 1, p. 51, 2023.