

DETECTING DENTAL CARIES THROUGH CAPTURED IMAGES USING THE MACHINE LEARNING TECHNOLOGY TEACHABLE MACHINE.

Abstract :

Objective: The aim is to apply artificial intelligence to identify deep tooth decay using the open-source tool Teachable Machine. **Subjects and research methods:** The study was conducted on 2063 digital images, including 1563 images with deep tooth decay and 500 images without deep tooth decay. **Results:** Out of the total 1563 images with deep tooth decay, when using the recognition tool, 1512 images were correctly identified (96%), and 51 images went undetected, accounting for 4%. Out of the total 2063 images, including both images with and without deep tooth decay, 1512 images were correctly identified (73.3%), and 551 images (26.7%) were not detected to have tooth decay. **Conclusion:** Through the study on 1563 images with deep tooth decay using the Teachable Machine learning tool, the results were promising with a high accuracy rate of 96%. However, on the mixed dataset of 2063 images, the accuracy rate for identifying images with tooth decay was only 73.3%. The difference is attributed to the early appearance of tooth decay, as its color closely correlates with normal tooth enamel. Therefore, the research team suggests the need for more data on this type of decay to enable more accurate classification and identification.

Keywords: *artificial intelligence; machine learning; tooth decay; teachable machine.*

I. INTRODUCTION

In the present era, the concept of Artificial Intelligence (AI) is no longer unfamiliar to us. Coined by Arther Samuel in the 1950s, AI has gained significant traction since Google initiated the development of Machine Learning (ML) systems in 2014. Machine Learning, a subset of AI, involves the research and construction of data repositories enabling systems to autonomously "learn" from the data provided, thus performing tasks previously exclusive to human capability. AI is being applied and supported across various domains including manufacturing, services, transportation, healthcare, entertainment, and information technology^{[1],[2],[3]}. In the field of Dentistry and Maxillofacial, AI is gradually being employed to assist in the consultation of oral diseases, diagnosis of dental caries, simulation of treatment plans in implant surgery, and prediction of outcomes after orthodontic treatment. This aids in enhancing the efficiency of examination and treatment procedures, concurrently elevating the quality of care. However, to achieve this, it is imperative to establish rich datasets to enable machine learning systems to provide the most accurate diagnostic suggestions, thereby saving time, effort, and achieving higher efficacy in the workflow. Globally, researchers like Srivastava have explored and applied machine learning tools to support automated diagnosis of oral diseases based on X-ray images^[4]. Berdouses and colleagues also conducted research in 2015 on diagnosing dental caries using a machine learning tool on 103 images^[5]. In Vietnam, author Vo Truong Nhu Ngoc has also published research on the method of automatically diagnosing complications of wisdom teeth based on X-ray images^[6]. Nevertheless, accessing and mastering the AI field for healthcare professionals remains complex and heavily reliant on the information technology team. For this reason, the authors conducted research on the application of the open-source tool Teachable Machine to create a dataset on dental caries pathology, aiming to train machine learning models to empower healthcare professionals and assist in their initial diagnostic process.

II. SUBJECTS AND METHODS

2.1. Research Subjects:

Intraoral images diagnosed with dental caries.

Selection Criteria: Digital images diagnosed by clinicians with clinical evidence of dental caries lesions, clearly showing details such as color changes like yellow, brown, black spots, and deep cavities exposing dentin.

Exclusion Criteria: Images that do not meet standards (noisy images, blurry images, images with unclear lesions, images in incorrect formats) and do not meet the selection criteria mentioned above.

2.2. Research Methodology:

2.2.1. Study Period: From April 2023 to January 2024.

2.2.2. Study Location: The research was conducted at Becamex International Hospital, Binh Duong Province, Vietnam

2.2.3. Sample Size: Purposive sampling was conducted, and in this study, we constructed a dataset consisting of 1563 images with dental caries lesions. These images were clinically diagnosed by dentists with dental caries lesions during clinical examination, and the dentists also concluded the presence of dental caries lesions based on the images. Additionally, 500 images of healthy teeth were included for comparison. The characteristics of the imaging angles for dental caries lesions were: buccal, lingual, mesial, distal, occlusal.

2.2.4. Research Instruments: Intra-Oral Digital Camera GX-C300; Intraoral mirrors; Standard dental examination kit.



Figure 1. Intra-Oral Digital Camera GX-C300 (A); Intraoral mirror set (B).

The computer connected to the network utilizes the open-source platform Teachable Machine (TM) to train machine learning models with basic training parameters (epochs 50, Batch size 16; Learning rate 0.001). TM will rely on a pre-trained image recognition network called MobileNet to accurately recognize patterns that have been previously trained through the provided dataset [8].

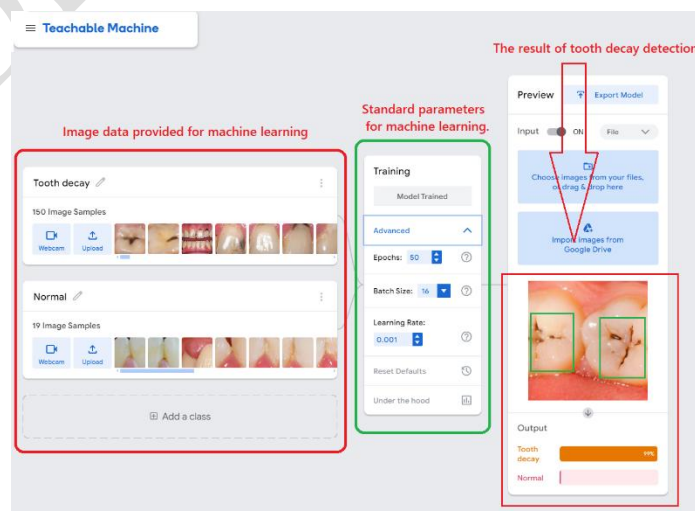


Figure 2. Model training process and results on Teachable Machine.

2.2.5. Data processing: SPSS 20.0 software and various statistical algorithms were utilized.

2.2.6. The study was approved and endorsed by the scientific and medical council of Becamex International Hospital, Binh Duong Province, Vietnam.

III. RESEARCH RESULTS:

3.1 Study sample: In this study, we conducted research with 1563 images exhibiting dental caries lesions and 500 images of healthy teeth (for comparison).

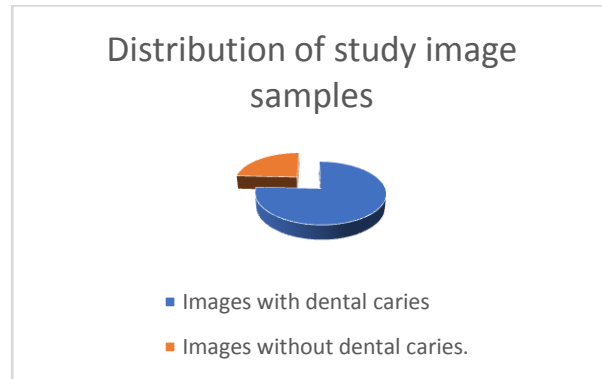


Chart 1. Distribution of the research sample.

3.2. Dental Caries Detection Rates Based on the Caries-Identified Dataset (n=1563)

N=1563	Dental Caries Detected	No Dental Caries Detected
	1512 (96%)	51 (4%)

Table 1. Detection rates of images with dental caries and without dental caries.

Out of the total of 1563 images with dental caries lesions, when using the Teachable Machine recognition tool, 1512 images were accurately identified as having dental caries lesions, accounting for 96% of the dataset, while 51 images were not detected to have dental caries lesions, representing 4%.

3.2. Dental Caries Detection Rates Based on the Mixed Dataset (n=2063)

N=2063	Dental Caries Detected	No Dental Caries Detected
	1512 (73,3%)	551 (26.7%)

Table 2. Detection rates of images with dental caries and without dental caries.

Out of the total of 2063 images in the mixed dataset comprising images with and without dental caries lesions, when using the Teachable Machine recognition tool, 1512 images were accurately identified as having dental caries lesions, accounting for 73.3% of the dataset, while 551 images were not detected to have dental caries lesions, representing 26.7%.

IV. DISCUSSION:

The application of artificial intelligence remains a relatively new and challenging field for healthcare professionals. The Teachable Machine machine learning toolkit, with its simple and accessible interface, facilitates easy access and utilization for healthcare teams. Based on our research results from 2063 digital images, including 1563 images with dental caries lesions and 500 images without dental caries lesions, the accuracy of dental caries lesion detection reached 96% in the dataset of 1563 images with dental caries lesions. However, in the mixed dataset of 2063 images, this detection rate decreased to 73.3% due to the presence of early-stage dental caries lesions, which exhibit color similarity with normal teeth. To address this issue, additional research data on early-

stage dental caries lesions are required to train machine learning models, thus providing more accurate data.

V. CONCLUSION:

The research results on 1563 images with dental caries lesions using the Teachable Machine machine learning tool demonstrate promising outcomes with a 96% detection accuracy rate. In the mixed dataset of 2063 images with and without dental caries lesions, the accuracy rate for detecting images with dental caries lesions is 73.3%. This difference is attributed to the presence of early-stage dental caries lesions, where the lesion color resembles that of normal tooth enamel. Therefore, the research team suggests the need for additional data on this type of lesion to improve classification and detection accuracy.

REFERENCES.

1. López-Úbeda P, Díaz-Galiano MC, Martín-Noguerol T, Ureña-López A, Martín-Valdivia MT, Luna A: Detection of unexpected findings in radiology reports: a comparative study of machine learning approaches. *Expert Syst Appl* 160: 113647, 2020. <https://doi.org/10.1016/j.eswa.2020.113647>
2. Chamunyonga C, Edwards C, Caldwell P, Rutledge P, Burberry J: The impact of artificial intelligence and machine learning in radiation therapy: considerations for future curriculum enhancement. *J Med Imaging Radiat Sci* 51: 214-220, 2020. <https://doi.org/10.1016/j.jmir.2020.01.008>
3. Abdalla-Aslan R, Yeshua T, Kabla D, Leichter I, Nadler C: An artificial intelligence system using machine-learning for automatic detection and classification of dental restorations in panoramic radiography. *Oral Surg Oral Med Oral Pathol Oral Radiol* 130: 593-602, 2020. <https://doi.org/10.1016/j.oooo.2020.05.012>.
4. Srivastava MM, Kumar P, Pradhan L, Varadarajan S . Detection of tooth caries in bitewingradiographsusingdeeplearning.arXiv preprint arXiv: 2017; 1711. 07312),Vinayahalingam (VinayahalingamS,XiT,BergéS,et al. Automated detection of third molars and mandibular nerve by deep learning. *Scientific reports*. 2019; 9(1), 1 – 7).
5. Berdouses ED, Koutsouri GD, Tripoliti EE, et al. A computer-aided automated methodology for the detection and classification of occlusal caries from photographic color images. *Computers in biology and medicine*. 2015; 62, 119 - 135.).
6. Ngoc VTN,AgwuAC, Son LH, et al. The Combination of Adaptive Convolutional Neural NetworkandBagofVisualWordsinAutomatic Diagnosis of Third Molar Complications on Dental X-Ray Images. *Diagnostics*. 2020; 10(4), 209.)
7. Teachable machine: Train a computer to recognize your own images, sounds, & poses. Retrieved September 30, 2020, from <https://teachablemachine.withgoogle.com#> Google(2019, November 1)
8. H. Pan, Z. Pang, Y. Wang, Y. Wang, L. Chen, 2020. A New Image Recognition and Classification Method Combining Transfer Learning Algorithm and MobileNet Model for Welding Defects. in *IEEE Access*, vol. 8, pp. 119951-119960, doi:10.1109/ACCESS.2020.3005450.]