

Seeded Trouble: A Case Report of Sigmoid Colon Perforation Due to Rambutan Seed

Author's contributions

This work was carried out in collaboration among all authors. all authors read and approved the final manuscript.

ABSTRACT

Introduction: Rambutan (*Nephelium lappaceum*), a tropical fruit indigenous to Southeast Asia, is popularly consumed for its sweet-sour pulp, however, it poses a significant risk when its seeds are ingested, especially in the elderly population as there is a probability of developing gastrointestinal obstruction or perforation. Perforation of the gastrointestinal tract attributed to foreign body ingestion is rare and it poses a significant challenge in emergency surgical care.

Case Report: We present a case of sigmoid colon perforation by rambutan seeds in a 71-year-old gentleman. Imaging investigations revealed the presence of foreign bodies with evidence of colonic perforation. Subsequently, a Hartmann's Procedure was performed and the patient was discharged after 9 days of hospital stay.

Discussion: Gastrointestinal perforation by foreign body ingestion is rare and typically involves sharp items such as toothpicks, needles, poultry or fish bones, and fruit seeds. Symptoms vary but often include severe abdominal pain, nausea, and vomiting often necessitating careful clinical evaluation. Imaging modalities such as CT scans aid in identifying the site of perforation hence playing an important role in guiding treatment decisions. Treatment approaches are often than not tailored to each patient and these options may include abscess drainage, antibiotic therapy, or surgical interventions such as bowel resection.

Conclusion: This case highlights the rare possibility of bowel perforation in the absence of obstructive symptoms, due to the ingestion of multiple non-sharp seeds. It also emphasizes the importance of prompt surgical intervention to achieve a favorable clinical outcome.

Keywords: Rambutan, Sigmoid colon, Perforation, Complication, Surgical intervention

1. INTRODUCTION

Rambutan is a tropical fruit native to Southeast Asia, particularly Malaysia, Indonesia, Thailand, and the Philippines. The name "rambutan" comes from the Malay word "rambut," which means "hair," referring to the spiky outer skin of the fruit. The fruit is small, oval-shaped, and covered with red or yellowish spiky hairs and is usually consumed by villagers due to their sweet-sour pulp. Most individuals refrain from consuming the seeds of the rambutan fruit, however, there is a certain number that do, particularly in extreme age groups. Ingesting the seeds, especially in significant amounts, can lead to gastrointestinal complications such as intestinal obstruction or perforation, which can result in fatality. This often occurs due to a delay in diagnosis and surgical intervention.

2. CASE PRESENTATION

A 71 years old gentleman, presented with no bowel opening and left lower abdominal pain for 4 days. Upon further questioning, he claimed to have eaten rambutan fruits with their seeds prior to having the symptoms. His past medical history includes well-controlled hypertension and dyslipidemia. The vital signs at admission showed normal blood pressure with tachycardia. Upon clinical examination, his abdomen was tender over the left iliac fossa on deep palpation without signs of peritonitis. Digital rectal examination was unremarkable. Blood parameters showed a raised total white cell of $15.3 \times 10^3/\text{mm}^3$ while other blood investigations were unremarkable. His abdominal x-ray revealed multiple radio-opaque foreign bodies in the descending and sigmoid colon, with no evidence of dilated bowels or pneumoperitoneum (Figure 1). The computed tomography (CT) scan revealed the presence of multiple ovoid structures within the lumen of the proximal sigmoid and descending colon (Figure 2). Additionally, there was focal eccentric thickening of the sigmoid colon wall, complicated by perforation and inflammatory changes in the surrounding area.

Initial management includes fluid resuscitation, commencement of analgesia, and broad-spectrum antibiotics. Subsequently, the patient underwent exploratory laparotomy which revealed a sigmoid colon perforation and localized pus collection (Figure 3-5). Upon examining the rest of the colon, multiple seeds were felt along the descending and sigmoid colon. Due to an iatrogenic perforation at the splenic flexure of the colon, we proceeded with a left hemicolectomy and end transverse colostomy. The patient had an uneventful postoperative recovery and was discharged home on postoperative day 8 with knowledge of colostomy care.

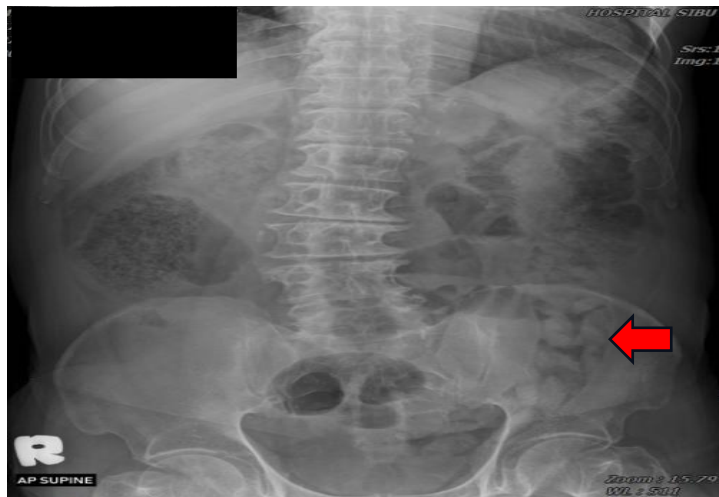


Figure 1: Abdominal X-ray showing multiple radio-opaque foreign bodies in the descending and sigmoid colon

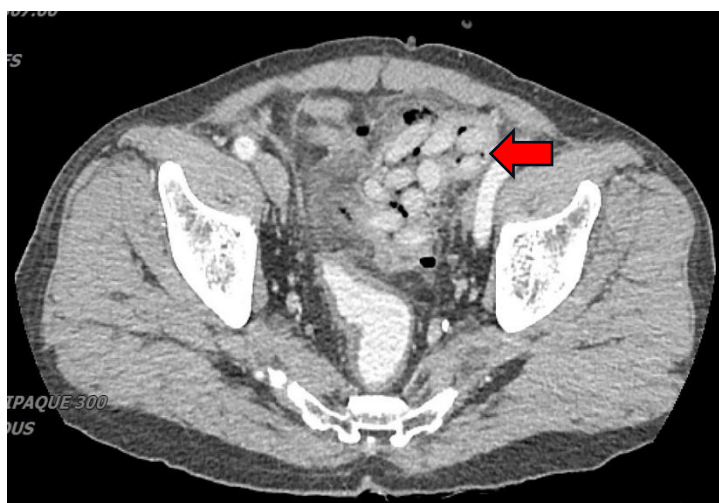

Figure 2: CT showing multiple ovoid structures within the lumen of the proximal sigmoid and descending colon

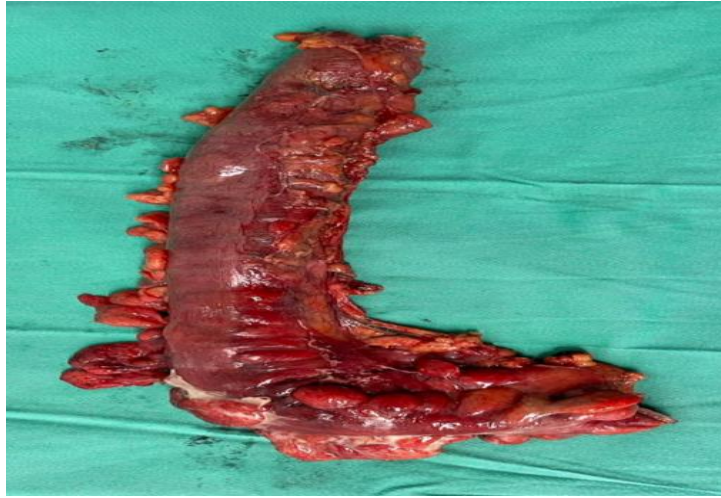


Figure 3: Resected left hemicolectomy specimen

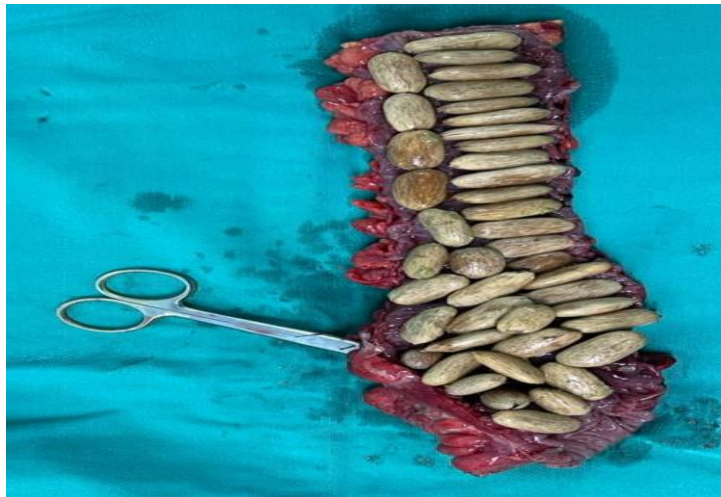

Figure 4: Resected left hemicolectomy specimen with the rambutan seeds and scissor pointing to the point of perforation

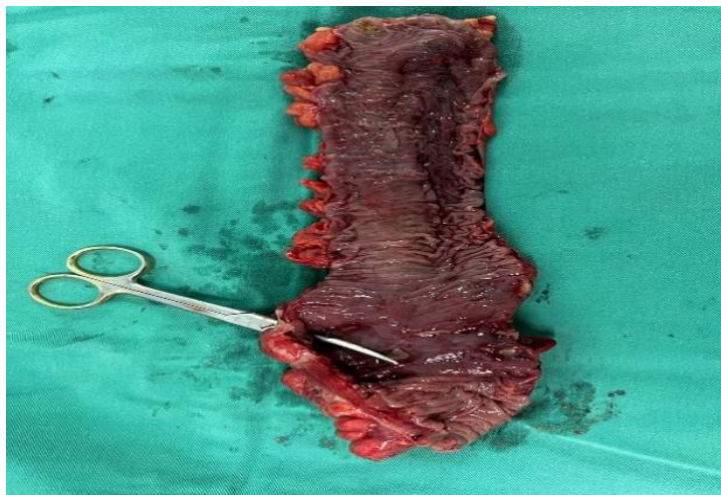


Figure 5: Resected left hemicolectomy specimen with scissor pointing to the point of perforation

3. DISCUSSION

While perforation of the gastrointestinal tract by foreign bodies is rare, it typically occurs due to the ingestion of sharp objects, and this accounts for 1% of cases of foreign body ingestion[1]. Examples of items capable of causing perforations include toothpicks, needles, poultry, fish bones, and fruit seeds. While many ingested foreign bodies pass through the gastrointestinal tract without issue, when they become impacted, they can lead to obstruction, perforation, or fistula formation [2]. Common areas that are usually affected include the esophagus, duodenum, colon, and rectum. Within the colon, these perforations commonly arise at transition sites from intraperitoneal locations to fixed retroperitoneal positions[3,4]. In this case, forty-two seeds with elliptical ends were intraoperatively removed, likely causing compression of the sigmoid colon wall due to impaction.

The clinical presentation of individuals with intestinal perforation varies, whereby it typically begins with mild, gradually worsening pain due to foreign body impaction, followed by a sudden escalation in pain, along with nausea and vomiting [5]. These symptoms eventually lead to peritoneal irritation and hence peritonitis.

Laboratory tests typically lack specificity, but often show leucocytosis with neutrophilia, alongside a non-specific elevation in CRP and ESR levels. As for imaging examinations, in cases of obstructive conditions, the standard abdominal radiograph remains invaluable for identifying signs suggestive of intestinal obstruction and perforation. In cases where perforation is suspected, computed tomography (CT) serves as the gold standard due to its ability to pinpoint the site of perforation by, contrast extravasation, detecting colonic wall thickening and adjacent mesenteric fat changes, which assists in surgical planning[6-8].

Treatment will invariably involve a personalized intervention for each individual, depending on various factors such as the location of the perforation, characteristics of the intestinal lesion, duration of symptoms, extent of contamination, patient's age and underlying comorbidities as well as the surgeon's expertise. Standard approaches to treating foreign-body perforation include abscess drainage and antibiotic therapy, with or without bowel resection [9]. In cases of colonic perforation, colostomy is often recommended due to the common occurrence of abdominal cavity contamination and diffuse peritonitis[10]. In this case, the colonic perforation led to intra-abdominal contamination, hence local resection, colostomy, and abscess drainage were deemed as an appropriate intervention for this patient.

4. CONCLUSION

In conclusion, this case highlights the potential dangers associated with ingesting rambutan fruit seeds, particularly among the older population. Prompt recognition of symptoms and appropriate resuscitation and surgical intervention are crucial in reducing morbidity and mortality. Overall, this case highlights the importance of awareness, early intervention, and personalized care in managing gastrointestinal perforations caused by foreign bodies.

As per international standards or university standards, patient(s) written has been collected and preserved by the author(s).

ETHICAL APPROVAL

As per international standards or university standards written ethical approval has been collected and preserved by the author(s).

REFERENCES

1. Ravindra RK, Das A, Chew GL, Daniel E. Small bowel obstruction with multiple perforations post chestnut ingestion. *BMJ Case Rep.* 2019;12(2).
<https://doi.org/10.1136/bcr-2018-227999>
PMCID: PMC6366892
2. Lohn JW, Austin RC, Winslet MC. Unusual causes of small bowel obstruction. *J R Soc Med.* 2000;93(7):365-8.
<https://doi.org/10.1177/014107680009300707>
PMCID: PMC1298061
3. Ram RN, Vishnu M, Mohd YK, Nil AMK, Wan KWK, Andee DZ. Rectal Perforation Caused By Santol Fruit Seeds. *SurgChron* 2020; 25 (3): 284-285.
4. Goh BK, Chow PK, Quah HM, Ong HS, Eu KW, Ooi LL, Wong WK. Perforation of the gastrointestinal tract secondary to ingestion of foreign bodies. *World J Surg.* 2006;30(3):372-7.
<https://doi.org/10.1007/s00268-005-0490-2>
PMID: 16479337
5. Noh HM, Chew FS. Small bowel perforation by a foreign body. *AJR Am J Roentgenol.* 1998;171(4):1002.
<https://doi.org/10.2214/ajr.171.4.9762984>
PMID: 9762984
6. Nicolodi GC, Trippia CR, Caboclo MF, de Castro FG, Miller WP, de Lima RR, Tazima L, Geraldo J. Intestinal perforation by an ingested foreign body. *Radiol Bras.* 2016;49(5):295-9.
<https://doi.org/10.1590/0100-3984.2015.0127>
PMCID: PMC5094817
7. Goh BK, Tan YM, Lin SE, Chow PK, Cheah FK, Ooi LL, Wong WK. CT in the preoperative diagnosis of fish bone perforation of the gastrointestinal tract. *AJR Am J Roentgenol.* 2006;187(3):710-4.
<https://doi.org/10.2214/AJR.05.0178>
PMID: 16928935
8. Hainaux B, Agneessens E, Bertinotti R, De Maertelaer V, Rubesova E, Capelluto E, Moschopoulos C. Accuracy of MDCT in predicting site of gastrointestinal tract perforation. *AJR Am J Roentgenol.* 2006;187(5):1179-83.
<https://doi.org/10.2214/AJR.05.1179>
PMID: 17056902
9. Yamamoto M., Yamamoto K., Sasaki T., Fukumori D., Yamamoto F., Igimi H., Yamamoto H., Yamashita Y. Successfully Treated Intra-Abdominal Abscess Caused by Fish Bone With Perforation of Ascending Colon: A Case Report. *IntSurg* 2015; 100: 428-430.
<https://doi.org/10.9738/INTSURG-D-14-00163.1>
PMCID: PMC4370530
10. Rodriguez-Hermosa JI, Codina-Cazador A, Sirvent JM, Martin A, Girones J, Garsot E. Surgically treated perforations of the gastrointestinal tract caused by ingested foreign bodies. *Colorectal Dis.* 2008;10(7):701-7.
<https://doi.org/10.1111/j.1463-1318.2007.01401.x>