

Pericardial effusion revealing cardiac and thyroid AA amyloidosis in chronic inflammatory bowel disease complicated by hypothyroidism discovered incidentally

ABSTRACT

The association of pericardial effusion with ventricular hypertrophy is one of the signs suggestive of cardiac amyloidosis, according to the literature. We report a case of cardiac and thyroid AA amyloidosis in a 65-year-old patient followed for chronic inflammatory bowel disease complicated by hypothyroidism revealed by a large pericardial effusion. We report a case of a 65-year-old postmenopausal patient followed for constipation for 3 years without any other particular history, who consulted for dyspnea evolving for 20 days initially with effort then becoming at rest evolving in a context of alteration of the general condition. Our report is the case of type AA amyloidosis probably secondary to chronic intestinal inflammation responsible for cardiac damage expressed by left ventricular hypertrophy and thyroid damage leading to hypothyroidism responsible for large pericardial effusion.

Keywords: Pericardial effusion; AA amyloidosis; Hypothyroidism

INTRODUCTION

Pericardial effusion secondary to hypothyroidism has been well described.

The association of pericardial effusion with ventricular hypertrophy is one of the signs suggestive of cardiac amyloidosis, according to the literature. Amyloidosis is a serious systemic disease. There are several types of amyloidosis, notably AA amyloidosis which is the subject of our study, whose cardiac involvement is very rare. (6) and which is often preceded by chronic inflammation.

We report this case of cardiac tamponade secondary to hypothyroidism complicating thyroid

amyloidosis in the context of multi-organ involvement of AA amyloidosis.

Case Presentation

This is a 65-year-old postmenopausal patient followed for constipation for 3 years without any other particular history, who consulted for dyspnea evolving for 20 days initially with effort then becoming at rest evolving in a context of alteration of the general condition.

The clinical examination upon hospitalization found a polypneic patient at 35 c/minute, So₂: 90% AA, BP: 120/80 mmHg, Fc: 80 b/minute with turgor of the jugular veins and edema of the lower limbs, and a muffled heart sounds on auscultation.

The remainder of the clinical examination was unremarkable.

On the ECG we noted a sinus rhythm, diffuse microvoltage with an appearance of right bundle branch block.

On transthoracic echocardiography: severe left ventricular hypertrophy without SAM, a large pericardial effusion with an overall longitudinal strain of -13.1% (images 1, 2 and 3 respectively).

An abdominal CT scan was performed revealing polyseritis associated with extensive right colonic parietal thickening, which appeared to be inflammatory.

On the biological level: we note a slight normochromic normocytic anemia Hb: 10.5 g/dl, hypothyroidism with TSHus at 156 μ IU/ml; T3=17ng/dl; T4=0.19ng/dl, liver and kidney function as well as the hemostasis assessment were correct, The autoimmunity assessment and thyroid ultrasound as part of the etiological search for hypothyroidism were unremarkable.

Thyroid aspiration revealed AA type amyloid deposits.

The pericardial effusion fluid was exudative on biochemical study, and the GeneXpert for tuberculosis was negative.

The bone scan was unremarkable.

The patient underwent pericardiocentesis with removal of 600 cc of citrine yellow liquid (image 4). She was put on Colchicine 0.5 mg/day, Aspirin 3g/day and Levothyrox 12.5 ug/day.

DISCUSSION

Hypothyroidism can cause effusions from different body cavities, including the peritoneum, pericardium, pleura,

middle ear, scrotum (1), these effusions are exudative and the mechanism is mainly extravasation of hygroscopic mucopolysaccharid in cavities with increased capillary permeability, decreased lymphatic drainage, and improved salt and water retention (2). Fluid accumulation is generally slow and the pericardium has the capacity to chronically distend so that hemodynamic changes are unlikely to be present even with massive pericardial effusion (3, 5).

The occurrence of cardiac tamponade in hypothyroidism is very rare due to the slow accumulation of fluid and pericardial insensitivity (3).

Alvani D et al., concluded in their case series that long-standing hypothyroidism leads to reversible cardiomyopathy, manifesting as asymmetric septal hypertrophy with or without other echocardiographic features of hypertrophic obstructive cardiomyopathy (4).

Mr. Zoubeidi et al., in a retrospective case series of patients with hypothyroidism with cardiac manifestations, found that out of 16 patients, 3 had left ventricular hypertrophy (5). In our case, the patient presents with extensive right colonic parietal thickening that appears a priori inflammatory, suggestive of IBD, which is one of the inflammations that can lead to AA amyloidosis.

AA amyloidosis is a variety of amyloidosis secondary to the deposition of insoluble fibrils of SAA protein produced in excess during chronic inflammatory situations; it is not classically associated with cardiac damage unlike immunoglobulin and transthyretin amyloidosis.

Cardiac involvement is rare and concerns less than 10% of patients; this

was confirmed by Mr. Lachmann et al., in their series which reported cardiac involvement in 1% of cases (6).

Mr. D. Bodez et al., confirmed with modern means of exploring cardiac amyloidosis that the heart is not a target of AA amyloidosis nor a specific cause of mortality a priori in this variety of amyloidosis. (7).

The echocardiographic appearance in our case pointed us towards amyloidosis, although the bone scintigraphy was negative and a search for gammopathy was negative. AA Amyloidosis probably due to chronic intestinal inflammation with cardiac and thyroid involvement as rare locations.

Mr Boudjema had reported in a case of hypothyroidism during type AA amyloidosis in the absence of goiter as was the case in our case (8)

CONCLUSIONS

Type AA amyloidosis is a rare cause of cardiac amyloidosis, our report is the case of type AA amyloidosis probably secondary to chronic intestinal inflammation responsible for cardiac damage expressed by left ventricular hypertrophy and thyroid damage leading to hypothyroidism responsible for large pericardial effusion.

Consent

As per international standards or university standards, patient(s) written consent has been collected and preserved by the author(s).

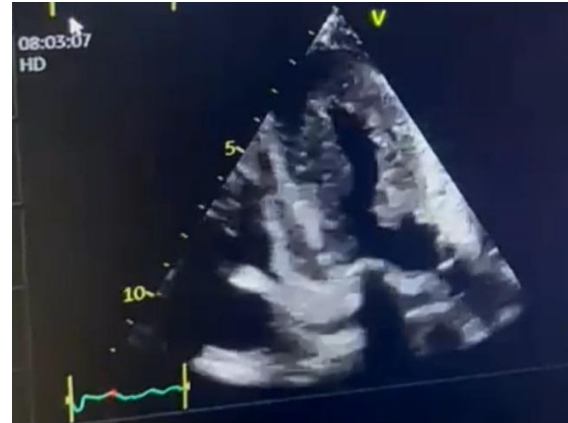

Image 1: Apical section showing significant LVH therefore the IVS/PP ratio: 1.3

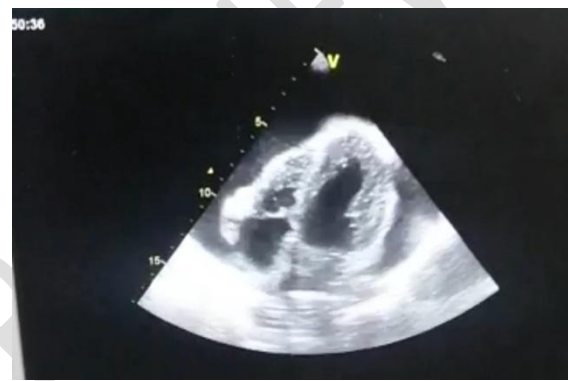

Image 2: 4-cavities subcostal section showing very abundant pericardial effusion

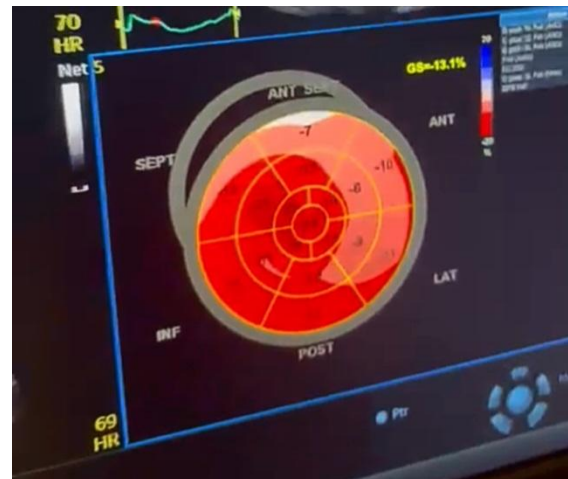


Image 3: Global longitudinal strain showing preservation of the basal walls and alteration of apical function

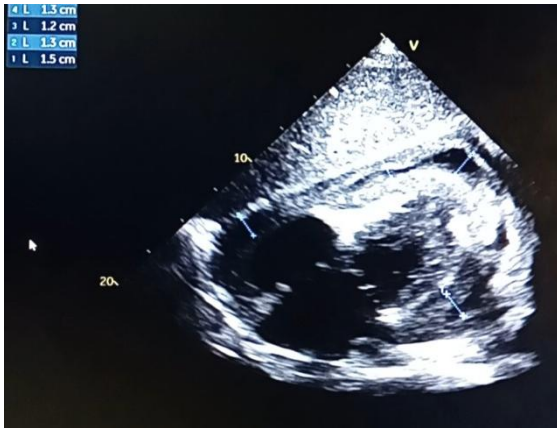


Image 4: subcostal cut after pericardiocentesis

Volume 75, Issues 5–6,2014,Page 501,ISSN 0003-4266,).

6. Lachmann HJ, Goodman HJB, Gilbertson JA, Gallimore JR, Sabin CA, Gillmore JD, et al. Natural history and outcome in systemic AA Amyloidosis. *N Engl J Med.* 7 Juin 2007 ;356(23) :2361-71.)

7. D. Bodez, S. Guendouz, G. Grateau, A. Galat, V. Avellino, M. Kharoubi, A. Guellich, G. Urbanski, E. Itti, J.F. Deux, T. Damy, S. Georgin Laviaille. Cardiac involvement in AA amyloidosis: prospective study on 38 patients, *La Revue de Médecine Interne*, Volume 38, Supplement 2, 2017, Pages A67-A68, ISSN 0248-8663

8. In Boudjema, hypothyroidism in type AA amyloidosis, think of thyroid amyloidosis even in the absence of goiter. *Khan. Revue d'Endocrinologie* 2008.

REFERENCES

1. Zimmerman J, Yahalom J, Bar-On H. Clinical spectrum of pericardial effusion as the presenting feature of hypothyroidism. *Am heart J.* 1983 ;106 :770-771.
2. Lin CT, Liu CJ, Lin TK, Chen CW, Chen BC, Lin CL. Myxedema associated with cardiac tamponade. *Jpn Heart J.* 2003;44(3):447–50. [[PubMed](#)] [[Google Scholar](#)]
3. Sagristà-Sauleda J, Mercé J, Permanyer-Miralda G, Soler-Soler J. Clinical clues to the causes of large pericardial effusion. *Am J Med.* 2000;109(2):95–101. [[PubMed](#)] [[Google Scholar](#)],
4. Echocardiographic characterisation of the reversible cardiomyopathy of hypothyroidism ; A D santos et al. *Am J Med.* 1980 May.
5. H. Zoubeydi, Z. Aydi, F. Daoud, L. Baili, B. Ben Dhaou, F. Boussema, Cardiac manifestations during hypothyroidism: series of 16 cases, *Annals of Endocrinology*,