

# Case report

## End-to-Side NEURORRHAPHY **TECHNIQUE**: EXPLORING NEURONAL REGENERATION TO RESTORE NERVE FUNCTION

### ABSTRACT

**Aims:** To report **the** case of a pediatric patient with total left brachial plexopathy (TLBP), exhibiting partially restored motor function and impaired sensitivity, **who** was treated with the End-to-Side neurorrhaphy (ETSN) technique.

**Presentation of case:** **A 13-year-old female was involved in** a car accident. After clinical and imaging evaluation, the diagnostic hypothesis was **TLBP** with partially restored function and loss of protective sensitivity in the pincer region. A surgical intervention was recommended. **Due to case characteristics, ETSN appeared to be the most appropriate technique.**

**Discussion:** **ETSN is a technique utilized for repairing nerve injuries.** It involves suturing the distal end of a transected nerve to the lateral side of a healthy donor nerve, aiming to restore neurons through peripheral plasticity. **The regeneration mechanism promoted by this technique shares some similarities with that promoted by standard techniques, with important roles being assigned to Schwann cells (SC), for example.** However, this procedure has its own particularities, which still require further investigation. Generally, ETSN cannot replicate the efficacy of model techniques, but remains valid in select cases, such as instances involving nerve injuries exceeding 3-4 cm or in the absence of donor nerves. **Therefore, ETSN stands as a choice and deserves consideration.**

**Conclusion:** The patient progressed with a good prognosis and recovered protective sensitivity in the pincer region. **ETSN is efficient** for peripheral nerve injuries with inaccessible proximal trunks or long nerve defects. The discussion surrounding ETSN remains controversial, making this study essential for expanding scientific knowledge.

*Keywords: Neurorrhaphy, Sensory, Trauma, Pediatrics, Case report.*

### 1. INTRODUCTION

Peripheral nerve injuries affect 2-2.8% of polytrauma patients, being associated with impairment of the functioning of the upper and lower extremities [1]. The occurrence of a complex process is crucial for the neuronal regeneration of the damaged nerve [2].

Initially, nerve membranes are stimulated to undergo a sealing process, due to the action of calpain, which is activated by the prompt influx of calcium and sodium. In this first moment, the proximal nerve stump is stimulated by action potentials, triggering the activation of the second messenger cAMP, which consequently releases pro-regenerative transcription factors [2].

Protein kinases are the main mediators of a second and slower phase, which, through the retrograde trafficking system, activate transcription factors. Despite these two phases, it is also necessary to eradicate the axons and myelin present in the distal stumps, as debris

produce inhibitory signals, impeding axonal neural development from the proximal stump. The Wallerian degeneration (WD) is vital for this process [2].

Variables such as the technique applied, type of nerve reconstruction and period between injury and surgery influence clinical outcomes of neuronal regeneration[3]. The End-to-End epineural nerve suture, considered the gold standard technique for microsurgical nerve reconstruction, has imperfections, sometimes not being feasible, such as when significant gaps exist between the stumps, limited amount of obtainable graft tissue, unavailability of the proximal nerve stump and morbidity at the donor site [3, 4, 5]. The literature discusses the End-to-Side neurorrhaphy (ETSN) technique as a potential strategy for treating nerve lesions [4, 5, 6].

ETSN was initially described by Létievant in 1873, however, it was rapidly abandoned due to unsatisfactory outcomes, probably related to the utilization of non-microsurgical instruments and techniques [5]. Later, Viterbo's experimental work, exhibiting histologic evidence of axonal growth into the distal recipient nerve and electrophysiological evidence of reinnervation, shifted the attention back to ETSN [6].

ETSN involves coaptation of the distal stump of a transected nerve to the trunk of an adjacent donor nerve, allowing the patient to regain nerve function [6]. This technique is based on the concept that axons regenerate through terminal and collateral sprouting from the donor nerve [7]. Usually, ETSN is recommended when End-to-End neurorrhaphy cannot be performed or the proximal stump is unavailable, as observed in global brachial plexus avulsion injuries [8]. When compared to other classic procedures, ETSN needs less time and dissection [1].

This study reports the case of a pediatric patient with TLBP, exhibiting partially restored motor function and impaired sensitivity. ETSN was performed from the lateral cutaneous nerve to the median nerve to restore protective sensation in the pincer region.

## 2. PRESENTATION OF CASE

Patient WK, a 13-year-old right-handed female with no comorbidities, was involved in a car accident. She was admitted to the neurosurgery department of a leading trauma hospital in Brazil and, after clinical stabilization, lost motility of the left upper limb. The clinical investigation revealed no intracranial lesions or fractures. She was then followed up as an outpatient, receiving post-trauma motor physiotherapy, which resulted in partial recovery of movement in the affected limb after two months.

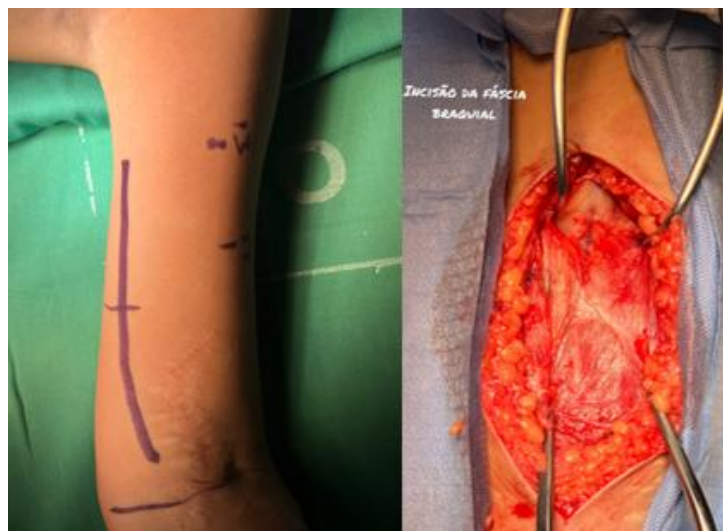A new physical examination revealed restored motor function in the musculocutaneous, median and axillary nerves. However, motor function of the ulnar and radial nerves was compromised. Also, painful sensitivity was preserved in the C5, hypoaesthetic in C6 and T1 and anesthetic in C7 and C8, with an electroneuromyography (ENMG) performed for further evaluation.

ENMG and magnetic resonance imaging (MRI) of the brachial plexus identified left axonal brachial plexopathy, mainly affecting upper and middle trunks, both pre and postganglionic. The evaluation exhibited absent or reduced signs of reinnervation in the biceps, extensor digitorum communis and extensor indicis muscles.

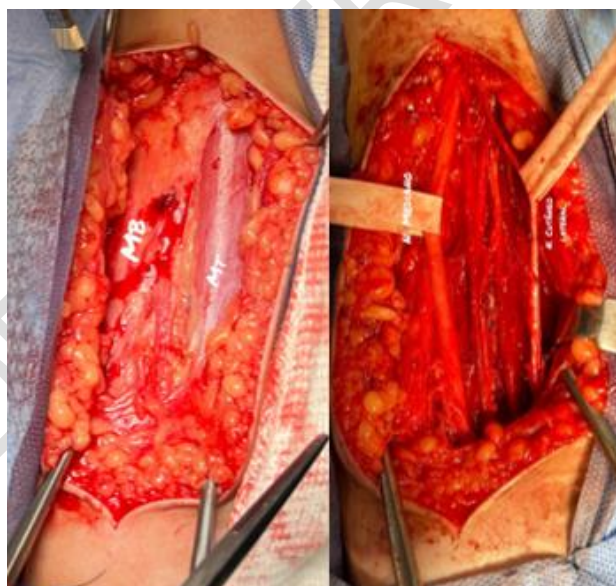
The MRI indicated avulsion of left C7 and C8 roots in the intradural portion, with no other abnormalities. Right plexus appeared normal. The left plexus showed heterogeneous appearance with prominent edema in the retroclavicular region, outside the scalene triangle. Diffuse muscle edema was present in the supraspinatus, infraspinatus, subscapularis and deltoid muscles, indicating denervation. Spinal cord signal alteration was noted from C3 to C6-C7 transition, related to traumatic myelopathy.

The diagnostic hypothesis was TLBP with partially restored function and loss of protective sensitivity in the pincer region. Surgical intervention was recommended. When analyzing the characteristics of the lesion in WK's case, which had nerve defects of over 3 cm associated with the absence of potential proximal donor nerve trunks, ETSN appeared to be the most

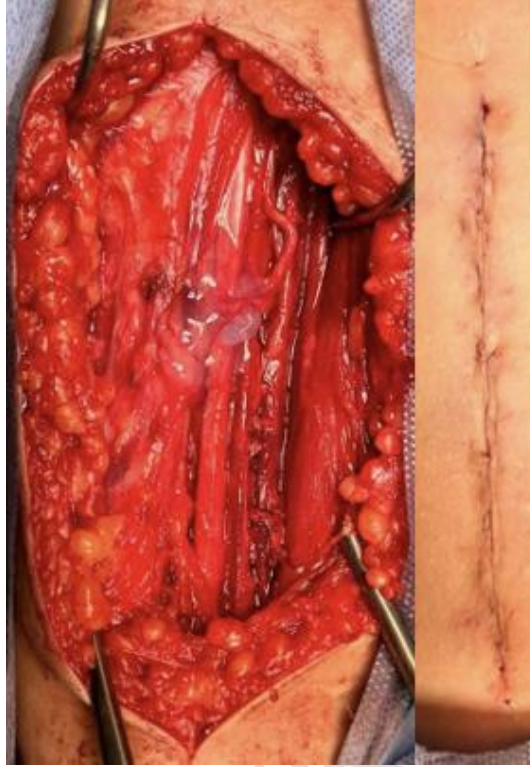
appropriate technique, being the procedure performed, involving neurotomy of the lateral cutaneous nerve as the donor to the median nerve as the recipient. The patient presented a good prognosis and recovered protective sensitivity in the pincer region. Below, there are images depicting the procedure.



**Fig.1:** Supine position with the arm abducted and externally rotated. Forearm extended in supination (left). Incision of the brachial fascia (right).



**Fig.2:** Muscle identification, biceps and triceps. Vasculonervous bundle dissection with identification of the median nerve and lateral cutaneous nerve.



**Fig.3:** Lateral cutaneous nerve section and End-to-Side transfer. Closing by planes and final appearance of incision.

### 3. DISCUSSION

ETSN is based on the suture of the distal end of a transected nerve to the lateral side of a healthy donor nerve, aiming to restore neurons through peripheral plasticity [1]. The recipient nerve acts as a scaffold for the growth of branches from the donor nerve, promoting sensory-motor restoration. Potentially, factors related to metabolism, neuroendocrinology, donor-recipient neurocompatibility, the degree of surgical trauma, size of the contact area and other variables influence outcomes [1,4,6].

The molecular regeneration mechanism promoted by the ETSN technique shares some similarities with that promoted by End-to-End nerve coaptation, with Schwann cells (SC), regulated growth fibroblasts, neurotrophic factors, and cell membrane proteins playing important roles. However, ETSN has particularities. Previous studies have demonstrated that undifferentiated SC are organized in columns at the coaptation site, providing pathways through which axons regenerate. The cells will eventually invade the epineural layer of the recipient nerve's end. A thorough research regarding End-to-Side nerve coaptation identified that, in the nerve regeneration process, there is collateral sprouting from the donor nerve, as well as migration of SC from the recipient nerve end to the coapted donor nerve. Additionally, macrophage-assisted elimination of myelin debris, production of growth-promoting factors, along with stimulation of extracellular matrix remodeling, enhance the nerve regeneration process [2].

The ETSN was first described over a century ago. However, previous failures led to its abandonment and re-examination only in 1992, when advances in neurobiology, microsurgical techniques and the contributions of Viterbo et al [1] emerged.

Currently, the efficacy and clinical usefulness of ETSN are debated, with disparities between experimental and clinical results [9]. Nevertheless, many studies have reported its feasibility in clinical practice [4].

Franciosi et al. reported on 5 patients with brachial plexus injuries who underwent the procedure, of whom 4 obtained a notable improvement in their clinical condition, achieving grade 4 elbow flexion a few months after surgery. Mennen described a series of 56 patients who were treated by ETSN, achieving better results in proximal motor and distal sensory reinnervation [9, 10].

A systematic review and meta-analysis compared postsurgical outcomes related to different surgical techniques in the treatment of digital nerve injury, revealing interesting results regarding ETSN. Although no technique proved to be entirely superior to the others, ETSN was an effective option in large segment defects or proximal nerve damage. Furthermore, End-to-Side coaptation had the highest excellent rate among the 8 methods analyzed [11].

Studies by Tos et al. and Lykissas et al. demonstrated ETSN effectiveness for nerve defects exceeding 3-4 cm and when proximal neuronal trunks or donor nerves are unavailable [4,5]. Amr et al. reported successful digital nerve reconstruction and traumatic brachial paralysis cases treated with Side-to-Side and ETSN, all showing satisfactory outcomes [4,12].

Haninec et al. analyzed ETSN for brachial plexus reconstruction, achieving a 43.5% satisfactory rehabilitation rate in patients undergoing ETSN with perineural window opening during a two-year follow-up. Previous studies findings, such as perineural suture as optimal intervention for reinnervation of nerves with large diameters, like the brachial plexus, and superior sensory reinnervation over motor after ETSN, reinforced our therapeutic choice [13].

Despite promising studies, such as the one by Czarnecki et al., which demonstrates the good efficacy of ETSN with prognostic results comparable to other techniques and without compromising the donor nerve [3], others, such as those by Tos et al., point to a possible increase in axonal growth time via the ETSN technique, which could be a contributing factor to unsatisfactory outcomes. However, even those studies state that ETSN can be considered a valid therapeutic option in selected situations, associated with other strategies, in the event of unsuccessful prior repair attempts or when other approaches are unavailable [4].

Differences between experimental and clinical results of ETSN may arise from incomplete neuronal regeneration understanding. Regenerated axons in the donor nerve's epineurium are thought to originate from Ranvier nodes near the ETSN site, however, histological evidence is scarce [14]. Partial neurotomy of the donor nerve, promoting endogenous activation of neuroendocrine factors, may enhance motor neuron regeneration through ETSN [4]. Physical and chemical factors, including phototherapy, FK506 and acetyl-L-carnitine, could also stimulate post-ETSN neuronal regeneration, encouraging future research [5].

A potentially promising discovery, that requires further investigation, is the utilization of FK1706 to improve post-ETSN nerve regeneration. Its potential benefit in neural regeneration derives from its capacity to raise the activation level of the Raf protein in nerve growth factor (NGF)-induced cells in signaling pathways.[15,16].

The literature suggests two mechanisms of axonal regeneration: terminal sprouting and collateral sprouting. In the former, axonal growth occurs along the uninjured axonal length. In the latter, axonal growth occurs in the distal mediations of the axons, which may or may not be injured. Contrary to initial studies findings, the process of axonal regeneration provided by the ETSN technique involves collateral sprouting in the intact axon side of the donor. This process begins in the nodes of Ranvier, proximal to the lesion, as mentioned above. However, this topic is still under research [6].

According to Zhang et al.'s studies, the combination of SC from the donor nerve with those migrating from the distal stump of the recipient nerve to the coapted donor nerve promotes collateral axonal sprouting [2].

Despite the fascicular transfer higher success rate, ETSN serves specific cases, particularly those involving risk of distal movement interruption due to donor nerve fascicle transection, a common concern in combined supraclavicular and infraclavicular brachial plexus injuries, leading to hand function impairment. [5,13]. Viterbo et al. and Frutan et al. explored variables that could influence ETSN efficacy, comparing it to other neuroorrhaphy methods. Frutan's study compared techniques with and without window, assessing functional and non-functional parameters. Results revealed that functional factors were not statistically different between groups, while non-functional aspects exhibited higher axonal fiber concentration in the ETSN with window technique, suggesting its sensitivity to neurotrophic factors. Salehi attributed this disproportionality to non-selectivity neural regeneration and metabolic variations [1,14]. Viterbo et al. also examined ETSN with and without a window, evaluating neuronal parameters over 6 months. No differences were found between the two neuroorrhaphy techniques regarding electrophysiological tests, muscle weight, histological evaluation, muscle fiber areas or nerve fiber counts. This finding is significant, as non-removal of perineurium makes ETSN easier, faster and safer [14]. This account becomes essential to shed light once again on the ETSN and also to discuss new approaches to the technique, such as the need to address innovations like the technique of promoting the proximal and distal ends of defective peripheral nerves into normal peripheral nerves using the End-to-Side anastomosis [17] and supercharged ETS transfer [2]. In this procedure, the damaged proximal nerve is primarily repaired and then overloaded with an End-to-Side coaptation of a donor nerve closer to the target muscle. This provides early reinnervation of the affected muscles, preventing their degeneration until native nerves can regenerate, thereby mitigating the effects of chronic denervation. Like the initially described End-to-Side technique, it has the additional advantage of not requiring sacrifice of a donor nerve.

#### **4. CONCLUSION**

ETSN technique proved to be efficient for peripheral nerve injuries with inaccessible proximal trunks or long nerve defects. The discussion surrounding ETSN remains controversial, making this study essential for expanding scientific knowledge on the subject, providing greater clarity and understanding.

#### **5. CONSENT**

The authors report that they have the patient's consent, which is available upon request.

#### **6. ETHICAL APPROVAL**

As per international standards or university standards written ethical approval has been collected and preserved by the author(s).

#### **7. REFERENCES**

1. Frutan SK, Salehi H, Mansouri K, Bakhtyari M, Abootaleb H, Pedram S. Comparison of nerve repair with end to end, end to side with window and end to side without window methods in lower extremity of rat. Medical Journal of Islamic Republic of Iran 2010, [S. l.], v. Vol. 25, n. No. 1, p. 40-46. <http://mjiri.iums.ac.ir/article-1-250-en.html>
2. Pereira CT, Hill EE, Stasyuk A, Parikh N, Dhillon J, Wang A, Li A. Molecular Basis of Surgical Coaptation Techniques in Peripheral Nerve Injuries. J Clin Med. 2023 Feb 16;12(4):1555. doi: 10.3390/jcm12041555. PMID: 36836090; PMCID: PMC9966153.

3. Czarnecki P, Huber J, Szymankiewicz-Szukała A, Górecki M, Romanowski L. End-to-Side vs. Free Graft Nerve Reconstruction-Experimental Study on Rats. *Int J Mol Sci.* 2023;24(13):10428. Published 2023 Jun 21. doi:10.3390/ijms241310428
4. Lykissas MG. Current concepts in End-to-Side neurorrhaphy. *World J Orthop.* 2011 Nov 18;2(11):102-6. doi: 10.5312/wjo.v2.i11.102. PMID: 22474628; PMCID: PMC3302033.
5. Tos P, Colzani G, Ciclamini D, Titolo P, Pugliese P, Artiaco S. Clinical applications of End-to-Side neurorrhaphy: an update. *Biomed Res Int.* 2014;2014:646128. doi: 10.1155/2014/646128. Epub 2014 Jul 20. PMID: 25136607; PMCID: PMC4127263.
6. Konofaos P, BassiliosHabre S, Wallace RD. End-to-Side Nerve Repair: Current Concepts and Future Perspectives. *Ann Plast Surg.* 2018;81(6):736-740. doi:10.1097/SAP.0000000000001663
7. Braga Silva J, Busnello CV, Becker AS, Moriguchi CA, de Melo RO, Waichel VB. End-to-Side neurorrhaphy in peripheral nerves: Does it work? *Hand Surg Rehabil.* 2022 Feb;41(1):2-6. doi: 10.1016/j.hansur.2021.08.010. Epub 2021 Aug 28. PMID: 34464758.
8. Paiva GR, Viterbo F, Deffune E, Custódio MAD. Stem cells in End-to-Side neurorrhaphy. Experimental study in rats. *Acta Cir Bras.* 2021 Jan 20;35(12):e351207. doi: 10.1590/ACB351207. PMID: 33503220; PMCID: PMC7819685.
9. Limthongthang R, Vathana T, Wongtrakul S, Songcharoen P. End-to-Side Neurorrhaphy to Restore Elbow Flexion in Brachial Plexus Injury. *J Med Assoc Thai.* 2016;99(11):1203-1208.
10. Franciosi LF, Modestti C, Mueller SF. Neurotization of the biceps muscle by End-to-Side neurorrhaphy between ulnar and musculocutaneous nerves. A series of five cases. *Chir Main* 1998; 17: 362-7.
11. Zhang Y, Hou N, Zhang J, Xie B, Liang J, Chang X, Wang K, Tang X. Treatment options for digital nerve injury: a systematic review and meta-analysis. *J Orthop Surg Res.* 2023 Sep 12;18(1):675. doi: 10.1186/s13018-023-04076-x. PMID: 37700356; PMCID: PMC10496177.
12. Amr SM, Moharram AN. Repair of brachial plexus lesions by End-to-Side side-to-side grafting neurorrhaphy: experience based on 11 cases. *Microsurgery.* 2005;25:126–146.
13. Haninec P, Mencl L, Kaiser R. End-to-Side neurorrhaphy in brachial plexus reconstruction. *J. Neurosurg* 2013, [S. l.], v. Vol 119, p. 689 - 694; <https://doi.org/10.3171/2013.6.JNS122211>
14. Viterbo F, Teixeira E, Hoshino K, Padovani CR. End-to-Side neurorrhaphy with and without perineurium. *Sao Paulo Med J.* 1998;116(5):1808-14. <https://doi.org/10.1590/S1516-31801998000500005>.
15. Gao W., He X., Li Y., Wen J. The effects of FK1706 on nerve regeneration and bladder function recovery following an End-to-Side neurorrhaphy in rats. *Oncotarget.* 2017; 8: 94345-94357. Retrieved from <https://www.oncotarget.com/article/21718/text/>
16. Gao, W., Yang, H., Xu, L. et al. The Neurotrophic Effects and Mechanism of Action for FK1706 in Neurorrhaphy Rat Models and SH-SY5Y Cells. *Neurochem Res* 46, 2897–2908 (2021). <https://doi.org/10.1007/s11064-021-03391-1>
17. Li D, Yang Q, Liu X, Jia J, Liu G, Bai K, Jia S, Peng J and Yu F (2023) Experimental study on the repair of peripheral nerve injuries via simultaneously coaptating the proximal and distal ends of peripheral nerves to the side of nearby intact nerves. *Front. Neurol.* 14:1088983. doi: 10.3389/fneur.2023.1088983