

Case report

Multiple Magnetic Foreign Bodies Causing Double gastrocolic fistulas In a Child: Case report

ABSTRACT

Aims:

This case report aims to highlight the serious complications arising from the ingestion of multiple magnetic foreign bodies in children, particularly focusing on a rare occurrence of double gastrocolic fistulas caused by the ingestion of 11 magnets with a metallic spring.

Presentation of Case:

A 10-year-old autistic child presented with abdominal pain and vomiting, leading to the discovery of multiple magnetic foreign bodies, resulting in a double gastrocolic fistula. Despite initial management attempts, surgical intervention became necessary after failed endoscopic extraction.

Discussion:

The ingestion of magnetic foreign bodies poses significant challenges in diagnosis and management, especially in cases involving multiple magnets. Clinical presentations vary, and diagnosis may be delayed, particularly in patients unable to provide detailed medical history, such as autistic individuals. Diagnostic imaging, notably abdominal X-rays, may not always provide clear differentiation between magnetic and metallic foreign bodies. Treatment strategies range from conservative monitoring to surgical intervention, with emphasis on prompt action to prevent severe complications.

Conclusion:

Awareness of the dangers associated with magnetic foreign body ingestion is crucial for early diagnosis and management, thereby minimizing morbidity and preventing potentially life-threatening complications. Efforts such as regulatory measures to restrict access to magnetic toys for young children are essential in mitigating the risks associated with these ingestions.

Keywords : Magnetic foreign body, child, case report, gastro-colic fistula.

1. INTRODUCTION

Foreign body (FB) ingestion remains a common emergency in children between 6 months and 6 years of age [1]. The rising popularity of magnetic objects, including toys, has led to a notable increase in the incidence of magnetic foreign body ingestion. Several case reports describe the ingestion of multiple magnets in children, contributing to significant damage

to the gastrointestinal tract which require endoscopic or surgical interventions. Here, we present a rare case of a 10-year-old autistic child with double gastrocolic fistulas caused by the accidental ingestion of 11 magnetic FBs with a metallic spring. The patient was successfully treated and cured at the Department of Pediatric Urology and Visceral, Mohammed VI University Hospital affiliated with Abdelmalek Essaadi University, Faculty of Medicine and Pharmacy, in October 2023.

2. PRESENTATION OF CASE

A 10-year-old autistic boy, presented with a history of diffuse abdominal pain and postprandial vomiting for one month. Initial management included antibiotic therapy and symptomatic treatment. Due to persistent symptoms, the treating physician requested an abdominal X-ray, revealing the presence of a radio-opaque FB with an intragastric spring. Despite the intragastric FB persisting in the radiological follow-up one week later, the patient was referred to the pediatric emergency department.

The clinical examination at admission revealed an afebrile and vitally stable child with a soft and non-distended abdomen. An abdominal X-ray was performed and did not show progression of the FB in the gastrointestinal tract (figure 1).

The patient underwent endoscopy next day, revealing six cylindrical magnets from construction toys embedded in the gastric mucosa that could not be removed via this method. Consequently, the patient was referred to our pediatric visceral surgery department, where surgical exploration with extraction of the FB is indicated.

An exploratory supra-umbilical midline laparotomy was performed, revealing, after the dissection of the gastro-colic ligament, double fistulas gastro-colic between the posterior wall of the stomach and transverse colonic (figure 2 et 3). Six cylindrical magnets were present in the stomach, embedded across the double fistulas, with 5 magnets and a spring in the colon (figure 4). The edges of the fistulas were brought together and closed with separate stitches of absorbable suture (figure 5). The postoperative course was straightforward. The patient was discharged on the seventh day after surgery.

3. DISCUSSION

Magnetic FB ingestions are rare in children. The first report of multiple FBs ingestion was reported by Honzumi from Japan in 1995 [2], which was complicated by jejuno-ileal fistula. During a 7-year retrospective study from 2003 to 2009, 1826 patients presented with FB ingestions. Out of these, 38 cases of magnetic FB ingestions were identified [3].

The prevalence of magnetic FB ingestion has risen steadily in children due to the widespread availability of small, high-powered rare-earth magnets in toys and desktop novelties. Between 2002 and 2011, approximately 16,386 cases of magnetic FB ingestions occurred in children in the United States. Representing an average annual increase of 75%, leading to an overall 8.5-fold rise in emergency department visits related to magnetic body ingestions [4].

Among the factors that make the diagnosis of foreign body ingestion difficult and delayed:

Diverse Clinical Presentations: The variety of clinical presentations adds to the challenge, ranging from asymptomatic patients without physical or functional signs, especially in cases of single magnetic FB, to cases involving symptoms such as vomiting, abdominal pain, occlusive syndrome, and signs of peritonitis. This is particularly when multiple magnetic FBs are ingested or when there is co-ingestion of a magnet with a metallic FB. Such cases can lead to severe complications like ulceration, volvulus, intestinal perforation, inter-intestinal fistula, peritonitis, or even death, attributed to the attractive force of magnets through the intestinal walls [5].

Age and Psychological Factors : Another contributing factor is age and psychological terrain. Young children, autistic individuals, or those with post-traumatic stress disorder or attention deficit hyperactivity disorder may lack the capacity to provide a comprehensive description of the nature and number of foreign bodies, further complicating the diagnostic process. This is exemplified in the case of our autistic patient, who exhibited symptoms for a month without receiving a diagnosis.

When there is a suspicion of foreign object ingestion, the initial radiologic test is typically an abdominal X-ray, chosen for its accessibility. However, distinguishing between magnets and other metallic foreign objects (like coins) can pose a challenge [6]. In our specific case, the abdominal X-ray did not provide a conclusive determination regarding the number and nature of the foreign body. It remains unclear if they are metallic or magnetic.

The therapeutic management of magnetic FB ingestion remains a constant challenge, with no clearly established consensus. Butterworth et al. suggest that any ingestion of a magnetic FB should be treated as multiple magnetic FB ingestion [7]. However, other teams opt for an outpatient approach in the case of a single magnet, monitoring the migration of the FB along the digestive tract with upright abdominal X-ray, and considering endoscopic or laparotomy extraction in case of progression failure or worsening symptoms [8]. However, if more than one magnet has been ingested, endoscopic extraction should be performed without delay, unless the magnets have passed the pylorus. Once the magnets have passed the pylorus, some authors prefer rapid surgical intervention, even if the patient is asymptomatic to assess the integrity of the bowels [9]. As described in our patient, following the failure of endoscopic extraction, a midline supraumbilical laparotomy is considered, revealing the presence of a double gastrocolic fistula complicated by the ingestion of 11 magnets with a spring.

In response to the rising digestive complications resulting from the ingestion of magnets, the US Consumer Product Safety Commission has mandated the prohibition of selling magnetic toys to individuals under the age of 14 years [10]. In 2006, the Directorate-General for Competition, Consumer Affairs, and Fraud Control conducted a press campaign in France, advising to keep small magnetic pieces found in products like jewellery and games out of the reach of three-year-old children. Additionally, it recommended informing older children about the risks associated with ingesting or inhaling multiple such elements [11].

4. CONCLUSION

Multiple magnets ingestion can lead to serious, sometimes deadly complications. Increased awareness of these dangers, both among parents and healthcare professionals, enables early diagnosis and management, which can significantly reduce, if not prevent, the complications and morbidity associated with the ingestion of magnetic foreign bodies.

Consent to publication:

We have received written consent from the patient's legal guardian for the publication of this case report. A copy of this consent form is available upon request.

REFERENCES

1. K. L. E. Hon, T. F. Leung, C. W. E. Hung, K. L. Cheung, and A. K. Leung, "Ingestion - associated adverse events necessitating pediatric ICU admissions," *Indian Journal of Pediatrics*, vol. 76, no. 3, pp. 283–286, 2009.
2. Honzumi M, Shigemori C, Ito H, et al. An intestinal fistula in a 3-year-old child caused by the ingestion of magnets: report of a case. *Surg Today* 1995;25:552–3.
3. M. M. Tavares, R. A. Saladino, B. A. Gaines, and M. D. Manole, "Prevalence, clinical features and management of pediatric magnetic foreign body ingestions," *Journal of Emergency Medicine*, vol. 44, no. 1, pp. 261–268, 2013.
4. Abbas MI, Oliva-Hemker M, Choi J, Lustik M, Gilger MA, Noel RA, et al. Magnet ingestions in children presenting to US emergency departments, 2002-2011. *J Pediatr Gastroenterol Nutr* 2013;57(1):18-22.
5. C. Raquillet *et al.* Avaler des aimants : un jeu dangereux. À propos d'une observation *Archives de Pédiatrie* Volume 15, Issue 6, June 2008, Pages 1095-1098
6. August A, Mueller C. Early recognition is important when multiple magnets masquerade as a single chain after foreign body ingestion. *J Pediatr Surg Case Rep* 2016;13:8–9.
7. Butterworth J, Feltis B. Toy magnet ingestion in children: revising the algorithm. *J Pediatr Surg* 2007;42:e3e5.
8. Lin A, Chan L.C.N, Hon K.L.E, Tsui S, Pang K, Cheung H.M, et al. Magnetic foreign body ingestion in children: the attractive hazards. *Case Rep Pediatr* 2019; 2019:3549242.
9. Lee S.K, Beck N, Kim H. Mischievous magnets: unexpected health hazard in children. *J Pediatr Surg* 1996;31:1694–5.
10. Serious injuries prompt recall of mattel's pollypocket magnetic play sets. Release 07-039, (Accessed 21 June 2012). <http://www.cpsc.gov/cpsc/pub/prerele/prhtml07/07039.html>; 2006, Published 21, November.
11. Vijaysadan V, Perez M, Kuo D. Revisiting swallowed troubles: intestinal complications caused by two magnets: a case report, review and proposed revision to the algorithm for the management of foreign body ingestion. *J Am Board Fam Med* 2006;19:511–6.

Figures:

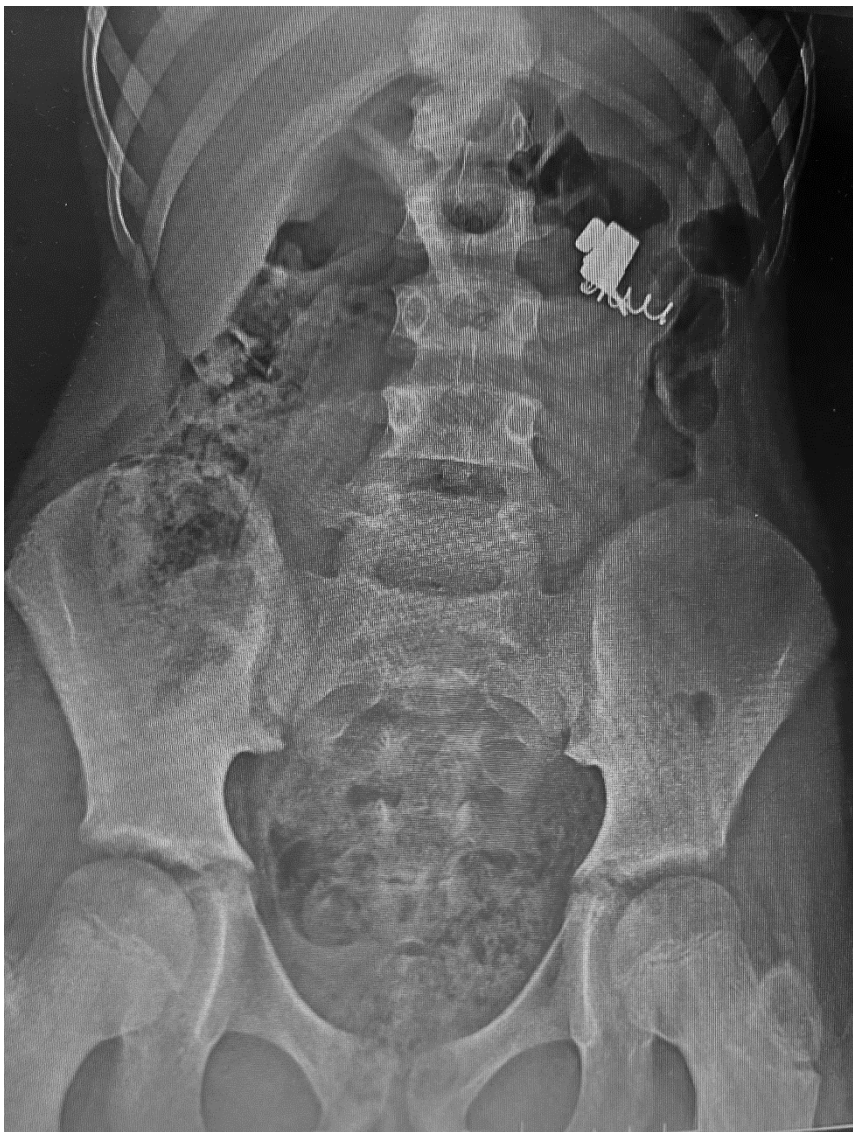

Figure 1: abdominal X-ray showing a radiopaque FBs in the epigastrium.

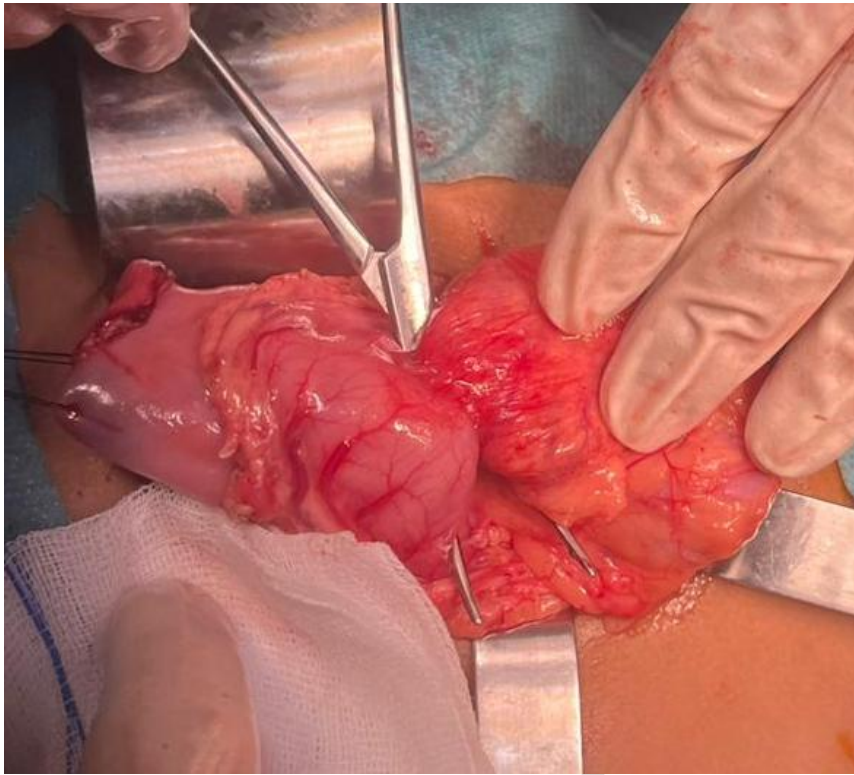


Figure 2: Intraoperative findings revealed Magnets attached to each other through the gastrosplenic wall

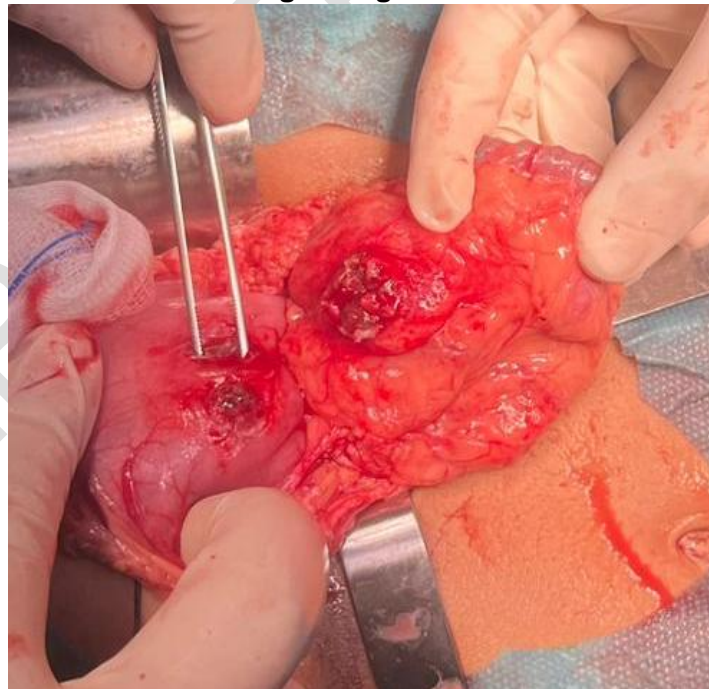


Figure 3: Intraoperative findings revealed double gastrocolic fistulas

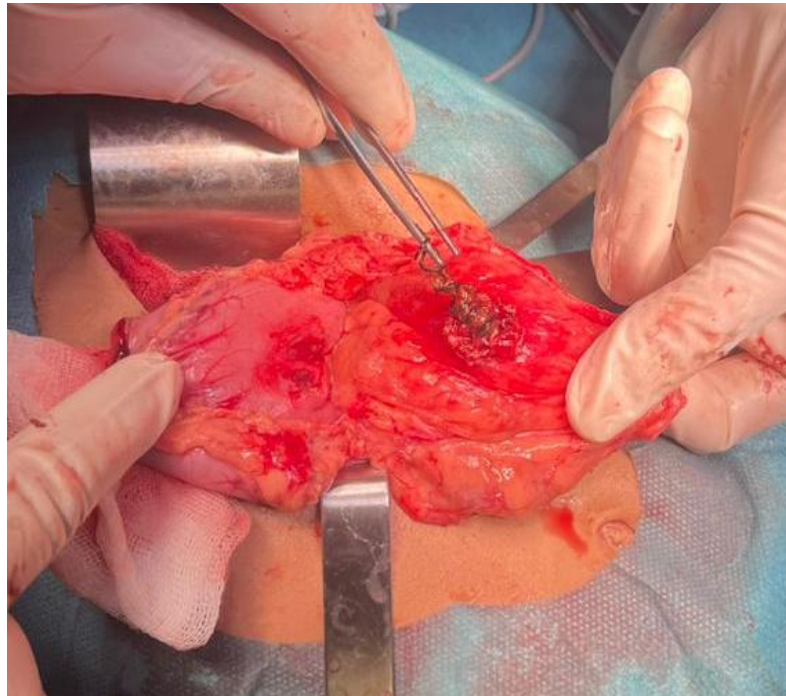


Figure 4: Intraoperative findings revealed extraction of the spring from transverse colonic

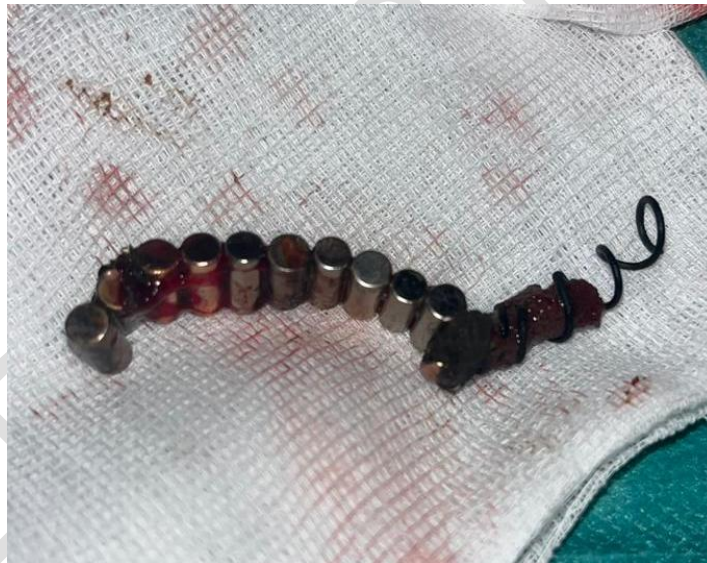

Figure 5: 11 cylindrical Magnets with a spring attached to each other