

# **CLINICOPATHOLOGICAL CONSISTENCY IN THE DIAGNOSIS OF SKIN DISORDERS IN A TERTIARY CARE HOSPITAL IN SOUTHERN NIGERIA: A DESCRIPTIVE CROSS-SECTIONAL ANALYSIS.**

***TYPE OF ARTICLE: ORIGINAL RESEARCH ARTICLE***

## **ABSTRACT**

**BACKGROUND:** The histopathological examination of representative skin biopsyspecimens is widely regarded as the gold standard for the resolution of dermatological diagnostic dilemmas, especially with good clinico-pathological correlation, and the skin biopsy is the dermatologists' most requested investigation. Studies on the clinico-pathological consistency in the diagnosis of skin disorders from **our** part of the world are very rare.

**OBJECTIVE:** This study aimed at determining the consistency between the provisional clinical diagnosis and the histopathological diagnosis of skin biopsy specimens.

**MATERIALS AND METHODS:** This study was carried out prospectively over a six-month period using specimens from the 58 patients who consented to skin biopsy during this time, and comparison was made between the provisional clinical diagnosis and the histopathological diagnosis.

**RESULTS:** Of the 58 subjects that participated in the study, 29 were males and 29 were females. Their ages ranged between 7 and 68 years, with a mean age of 37.3 years. The spectrum of histopathologically diagnosed disorders included skin tumours and tumour-like conditions (12 cases, 20.7%), psoriasiform disorders (10 cases, 17.2%), lichenoid disorders (9 cases, 15.5%), infectious disorders (8 cases, 13.8%), disorders of epidermal maturation and keratinization (7 cases, 12.1%), spongiotic disorders (7 cases, 12.1%), vesiculo-bullous disorders (3 cases, 5.2%), and others (3.4%). Overall, the histopathological diagnosis was consistent in 19 cases (32.8%), corroborative in 12 cases (20.7%), with clinico-pathological correlation, and inconsistent in 27 cases (46.6%), leading to the issuance of a completely new diagnosis.

**CONCLUSION:** The observed degree of clinico-pathological inconsistency in the evaluation and diagnosis of skin disorders in our environment implies that skin biopsy for histopathological examination is highly valuable if patients are to be issued the appropriate diagnoses for the **avoidance of inappropriate treatments**. The contribution of histopathology to the accuracy of dermatological diagnosis is significantly enhanced by clinico-pathological corroboration.

**KEYWORDS:** Clinico-pathological, Histopathological, Skin biopsy, Diagnosis

## INTRODUCTION

Skin diseases are not merely cosmetic problems but a major medical challenge affecting much of the global population, although more by morbidity than mortality.<sup>1</sup> Although they are quite prevalent in developing countries, unfortunately, they are presently not given much attention in the drafting of health policies and in the planning of public health strategies in these countries, including Nigeria. Studies have shown in particular, that skin disorders as a whole are a significant contributor to morbidity in Nigeria.<sup>1,2</sup> According to a study in rural Tanzania, significant skin disease was found in 27% of the individuals examined.<sup>3</sup> Increased urbanization, but with poor town planning and inadequate social amenities, seems to adversely influence the trend of skin disorders. A survey of a population in urban Mali revealed that up to 26% of consultations were due to skin conditions.<sup>4</sup>

Dermatologists do not routinely perform skin biopsies on every patient seen, as it is not always clinically indicated, nor does every patient requiring it give consent even when affordable.<sup>5</sup> Many dermatological disorders however require skin biopsy for the refinement and clarification of clinical diagnoses. In some cases, the histopathological examination of skin biopsy specimens proves the clinical diagnosis wrong. This is important for the avoidance of inappropriate treatments and/or therapeutic failures. A diagnosis rendered by histopathological examination of skin biopsy specimens is regarded as definitive in times of clinical diagnostic uncertainty, and skin biopsy for histology is the most common investigation requested for by dermatologists.<sup>5,6</sup> In our environment, anatomic pathology contributes a lot more to dermatology practice than to the practice of other subspecialties in internal medicine.

The interpretation of the non-neoplastic pathological changes in skin biopsies is restricted by the fact that the skin has a limited number of morphological reaction patterns for numerous aetiological agents, so that clinically diverse diagnostic entities may share similar

histomorphology. The overall precision of the final diagnosis for the patient therefore depends on the accompaniment of the biopsy specimen by relevant information such as, site of biopsy, duration, clinical appearance and distribution of the lesions, nature and duration of treatment so far and clinical differential diagnoses. When the histological picture is not diagnostic as is sometimes the case, clinicopathological correlation will often make diagnosis possible. Repeat and follow-up biopsies are sometimes needed for further clarification.<sup>7,8</sup>

Studies from various parts of the world show varying degrees of clinico-pathological consistency in dermatological practice, depending on how this is assessed and adjudged; but the bottom line for all researches reviewed is that clinico-pathological correlation greatly enhances the practice of dermatology by improving diagnostic accuracy.<sup>5-8</sup> In Nigeria, there are a number of challenges to achieving good clinico-pathological correlation in dermatology practice, including the shortage of specialist dermatopathologists, the low level of interest of general pathologists in dermatopathology, the additional cost implications of skin biopsy to the average patient, and traditional, self- and physician-prescribed medication prior to eventual skin biopsy.

The aim of this study was to examine the degree of clinico-histopathological consistency in the diagnosis of skin disorders in our practice, with a view to highlighting the relevance of histopathological examination of skin biopsy specimens to the accuracy of dermatological diagnoses. To the best of our knowledge, and from online search findings, the overwhelming majority of studies on skin disorders in Nigeria in which Pathologists are involved are retrospective reviews with respect to the pattern or spectrum of dermatological disease occurrence. There is therefore, in Nigeria and Africa, an obvious dearth of studies similar in concept and design to the index study. This comes as no surprise, as in Nigeria for instance, formal training or subspecialisation in dermatopathology is not yet available. Moreover, most

of our Pathologists are generalists, and only very few are even at all interested in dermatopathology.

## **METHOD**

This was a descriptive cross-sectional study conducted in the Dermatology Clinic and Histopathology Department, after ethical clearance, over a period of 6 months in a tertiary care centre in south-south Nigeria. The subjects were all the patients who provided written informed consent to undergo skin biopsy and partake in our study during the period between July 1 and December 31, 2019. For subjects who were minors, written informed consent was obtained from their parents. Patient particulars, brief history and clinical findings, provisional diagnoses and differential diagnoses (if any) were clearly mentioned in the biopsy requisition form. Representative biopsy specimens were obtained, with multiple biopsies taken as required. The specimens were fixed in 10% neutral buffered formalin for 24 - 48 hours and embedded in paraffin. Microtomy sections of 4µm thickness were made and stained with routine haematoxylin-eosin (H&E) and periodic acid Schiff (PAS). Special histochemical stains were utilized whenever required. The slides were reviewed by a Consultant Pathologist with special interest and experience in dermatopathology.

For convenience of evaluation we classified all the skin disorders encountered into groups namely; skin tumours and tumour-like conditions, psoriasiform disorders, lichenoid disorders, infectious disorders, disorders of epidermal maturation and keratinization, spongiotic disorders, vesiculo-bullous disorders and others. We interpreted the histopathological reports as follows:

1. Consistent- when provisional diagnosis and histopathological diagnosis were the same.
2. Corroborative - when histopathological diagnosis was consistent with at least one of the differential diagnoses.

3. Inconsistent- when histopathological diagnosis was not consistent with provisional clinical diagnosis or differential diagnoses.

The results were presented in a simple figure and tables.

#### SAMPLE SIZE DETERMINATION

The minimum sample size was calculated to be 23, using an automated sample size calculator application based on the formula,

$$n = \frac{z^2 \times p(1-p)}{\epsilon^2}, \text{ where:}$$

n = minimum sample size

$z^2 = 1.96$  (standard normal deviation of statistical level of significance)

p = proportion of biopsies that were skin biopsies, of the total number of biopsies received in the department over the previous 10 years (403 out of 26,359, being 0.015 or 1.5%), and

$\epsilon$  = margin of error (95% confidence level and 5% margin of error).

## RESULTS

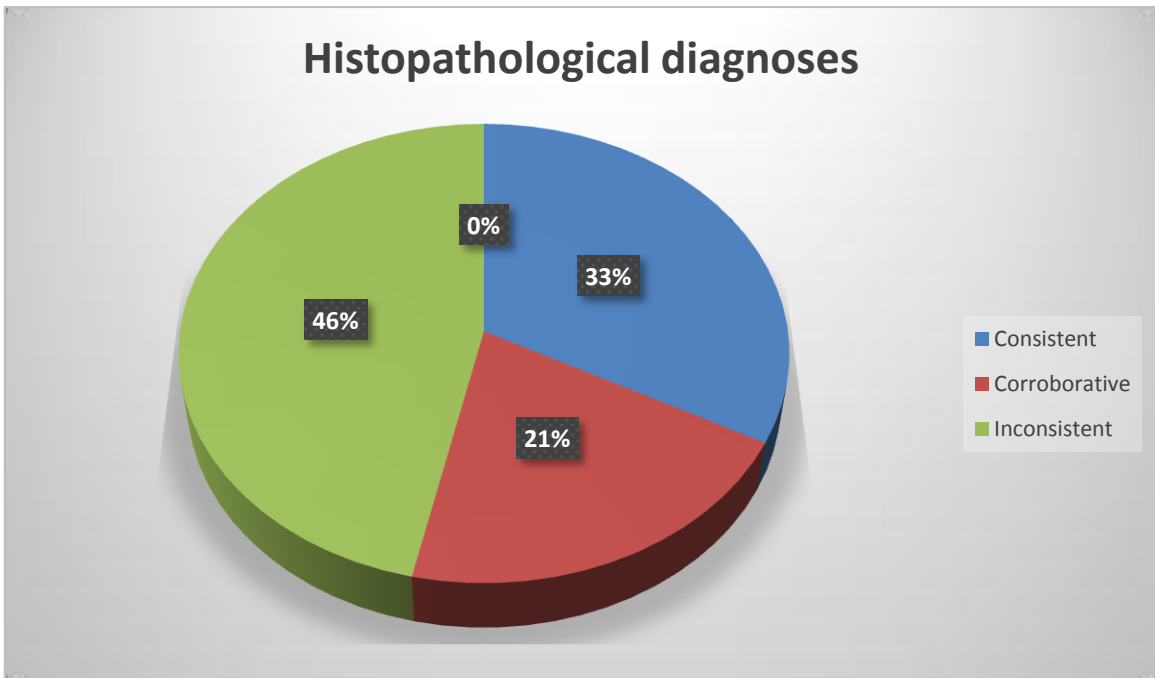
Of the 58 subjects that participated in the study, 29 were males and 29 were females. Their ages ranged between 7 and 68 years, with a mean age of 37.3 years.

The spectrum of histopathologically diagnosed disorders included skin tumours and tumour-like conditions (12 cases, 20.7%), psoriasiform disorders (10 cases, 17.2%), lichenoid disorders (9 cases, 15.5%), infectious disorders (8 cases, 13.8%), disorders of epidermal maturation and keratinization (7 cases, 12.1%), spongiotic disorders (7 cases, 12.1%), vesiculo-bullous disorders (3 cases, 5.2%), and others (3.4%). This distribution of lesions is represented in table 1.

**Table 1: Spectrum of histopathologically diagnosed skin disorders**

<b>Class of Skin Disorder</b>	<b>Frequency</b>	<b>Percentage</b>
Skin tumours and tumour-like conditions	12	20.7
Psoriasiform disorders	10	17.2
Lichenoid disorders	9	15.5
Infectious disorders	8	13.8
Disorders of epidermal maturation and keratinization	7	12.1
Spongiotic disorders	7	12.1
Vesiculo-bullous disorders	3	5.2
Others	2	3.4
<b>Total</b>	<b>58</b>	<b>100.0</b>

Overall, the histopathological diagnosis was consistent in 19 cases (32.8%), corroborative in 12 cases (20.7%), with clinic-pathological correlation, and inconsistent in 27 cases (46.6%), leading to the issuance of a completely new diagnosis. These findings are as depicted in figure 1.



**FIGURE 1: Consistency between provisional clinical diagnosis and histopathological diagnosis**

UNDER PEER REVIEW

**Table 2: Selected cases with inconsistency between the provisional clinical diagnosis and histopathological diagnosis**

	<b>PROVISIONAL CLINICAL DIAGNOSIS / DIFFERENTIAL</b>	<b>HISTOPATHOLOGICAL DIAGNOSIS</b>
1.	Cutaneous DLE with candidiasis	Lichen simplex chronicus
2.	Bacterial skin infection	Lichenoid dermatitis
3.	Immunobullous disorder	Lichenoid dermatitis
4.	Melanoma	Dermoid cyst
5.	Chronic papular onchocerciasis	Lichen simplex chronicus
6.	Bacterial skin infection	Allergic contact dermatitis
7.	Sarcoidosis / cutaneous tuberculosis	Sebaceous hyperplasia
8.	Prurigo nodularis	Lichen simplex chronicus
9.	Lichenoid dermatosis	Allergic contact dermatitis
10.	Dermatophytosis / scabies	Small plaque parapsoriasis
11.	Bacterial skin infection	Irritant contact dermatitis
12.	Cystic fibroma	Eccrine hydrocystoma
13.	Kaposi sarcoma	Skin abscess with FB granuloma
14.	Nevus with malignant transformation	Syringocystadenomacystoma
15.	Urticaria / atopic dermatitis	Pemphigus foliaceus
16.	Plantar keratoderma	Verruca vulgaris
17.	Steatocystoma simplex	Calcinosis cutis
18.	Immunobullous disorder/bacterial skin infection	Chronic psoriasiform dermatitis
19.	Fibroma	Neurofibroma
20.	Allergic contact dermatitis	Lichen planus-like keratosis

**KEY:**DLE – discoid lupus erythematosus, FB – foreign body.

## DISCUSSION

The need to ensure an accurate dermatological diagnosis as much as possible cannot be overstated if patients are to receive the appropriate therapy, and if treatment failures are to be avoided, or at least minimized. Although there are skin disorders that are readily, conclusively and reliably diagnosed clinically, the dermatologist often requires the assistance of the pathologist via the examination of skin biopsy specimens. Sometimes, the histopathological diagnosis perfectly matches and confirms the provisional clinical diagnosis; at other times, it is completely at variance, and an entirely new and clinically unforeseen diagnosis has to be issued to the patient. In many cases, a conclusive diagnosis cannot be reached histopathologically because a number of related and unrelated skin disorders may share the same histomorphology. In such cases, a clinico-pathological correlation is required to arrive at a suitable diagnosis.<sup>7,8</sup>

Unfortunately, despite the usefulness of skin biopsy some patients in our environment do not readily consent to the procedure because of the additional costs (payments are made out of pocket) and the invasive nature. This leaves the dermatologist with no option than to proceed with treatment based on the clinical diagnosis alone, which may or may not be successful. In many cases it is the failure of treatment that compels patients to return for skin biopsy, which increases the chances of an appropriate diagnosis, which is often followed by definitive treatment. A possible drawback at this point though, is that additional, and possibly confounding morphological changes, will have been induced in the lesion following prolonged, ineffective treatment and chronic irritation.<sup>9</sup>

In our study skin tumours and tumour-like conditions were the most frequently encountered. This finding was also true for studies done by Al-Hamammy et al,<sup>10</sup> Korfitis et al<sup>5</sup> and Yap et al,<sup>11</sup> but is unlike what is generally reported in the available literature.<sup>6,12-18</sup> Our finding is

probably because a clinically suspected neoplasm is more likely to provoke greater curiosity and anxiety, and so will more likely get to be biopsied.

Overall, we found the clinical diagnosis to be consistent with the histopathological diagnosis in less than a third of cases (32.8%). This is much lower than the clinico-pathological consistency as reported in some studies in Asia, North America and Europe,<sup>5-9,13,14,19</sup> where the concordance rates ranged from 56% - 87%, but is higher than the full concordance rate reported in some studies in the Middle East (19-28%).<sup>10,20</sup> Furthermore, in one-fifth of the cases the clinical diagnosis, or any of the differentials, was corroborative with the histopathological diagnosis, with final diagnoses unattainable without clinico-pathological correlation. This proportion is similar to the finding by Sa et al (19.1%),<sup>6</sup> and Rajaratnam et al (25%),<sup>21</sup> but is much lower than reported by Al-Hammamy et al (55%).<sup>10</sup> Nevertheless, it is clear that the utility of histopathology is improved when well thought-out clinical differential diagnoses are provided, as also alluded to by several studies.<sup>14,21</sup>

In as many as 46.6% of cases in this study, the histopathological diagnosis was completely different from the provisional clinical diagnosis, or any of its differentials, leading to the issuance of a completely new diagnosis to the patient. This proportion of cases of complete clinico-histopathological discordance was similar (44.7%) to the findings of Ndukwe et al in eastern Nigeria,<sup>1</sup> but higher than reported by Sa et al<sup>6</sup>(13.5%), Kafle et al (21.6%)<sup>14</sup> and Mishra (21%) in Asia.<sup>22</sup> One Indian study reported a clinico-pathological discordance rate of 35.6%.<sup>23</sup> In these kinds of situations, the histopathological examination of skin biopsies proves to be the only bridge between the patients' presenting lesions and the issuance of accurate and appropriate diagnoses. It seems plausible however, that the observed high degree of clinico-histological discordance may have been contributed to by the effects of chronic irritation and/or scratching on the clinical appearance of the lesions prior to skin biopsy. Furthermore, the prior application of unorthodox or herbal / traditional medication to

the lesions might have in some cases modified both the clinical and microscopic morphology. Moreover, because skin biopsy is often not consented to by patients at first prescription for a variety of reasons, some of which have been earlier adduced, even orthodox medication prescribed by the dermatologists themselves, or orthodox self-medication, used by patients who are slow to consent to skin biopsy but demand treatment, might have modified the lesions ahead of a later skin biopsy. Factors as these should be borne in mind by dermatologists and pathologists alike, and by future researchers along these lines.

Conclusion: the observed degree of clinico-pathological inconsistency in the evaluation and diagnosis of skin disorders in our environment implies that skin biopsy for histopathological examination is highly valuable if patients are to be issued the appropriate diagnoses. The contribution of histopathology to the accuracy of dermatological diagnosis is enhanced by clinico-pathological corroboration. The establishment of a comprehensive health insurance scheme could increase the proportion of patients undergoing skin biopsies for the enhancement of diagnostic accuracy and therapeutic success. Moreover, it is believed that practising under such conditions will promote both dermatological and dermatopathological experience and expertise.

## REFERENCES

1. Ndukwe CO, Chiemeka ME, Eziagu UB, Ndukwe CC, Uzoigwe JC. Histopathological spectrum and clinicopathological concordance of nonneoplastic skin lesions at a teaching hospital in South-Eastern Nigeria: A 16-year retrospective study. *Journal of Nature and Science of Medicine* 2021;4(4):373-8.
2. Nnoruka EN. Skin diseases in south- east Nigeria: a current perspective. *International journal of dermatology* 200;44(1):29-33.
3. Gibbs S. Skin Disease and Socioeconomic Conditions in Rural Africa: Tanzania. *International Journal of Dermatology* 1996;35:633–39.
4. Mahe A, N'Diaye T, Bobin P. The Proportion of Medical Consultations Motivated by Skin Diseases in the Health Centre of Bamako (Republic of Mali). *International Journal of Dermatology* 1997;36:185–86.
5. Korfitis C, Gregoriou S, Antoniou C, Katsambas AD, Rigopoulos D. Skin biopsy in the context of dermatological diagnosis: a retrospective cohort study. *Dermatology research and practice* 2014.
6. Sa DK, Kumar P. Clinicopathological consistency in diagnosis of skin disorders: a retrospective study of 371 histopathology reports. *Journal of Pakistan Association of Dermatologists*. 2016;26(2):96-8.
7. Grace DF, Bendale KA, Patil YV. Spectrum of pediatric skin biopsies. *Indian J Dermatol* 2007; 52:111-5
8. Sellheyer K, Bergfeld WF. A retrospective biopsy study of the clinical diagnostic accuracy of common skin diseases by different specialties compared with dermatology. *Journal of the American Academy of Dermatology* 2005;52(5):823-30.
9. Taylor SC. Skin of colour: biology, structure, function, and implications for dermatologic disease. *Journal of the American Academy of Dermatology* 2002;46(2):41-62.
10. Al-Hamammy HR, Al-alsadawi AR, Al-Samarraee RI. Clinicopathological Consistency in the Diagnosis of Skin Disorders in Patients Attending Dermatology Centre\Medical City Teaching Hospital. *Iraqi Postgraduate Medical Journal* 2019;18(3).
11. Yap B, Boon F. Dermatopathology of 400 skin biopsies from Sarawak. *Indian journal of dermatology, venereology and leprology* 2009;75(5):518-9.
12. Faituri SS. Clinicopathological Correlation in Dermatopathology. *J Dermatol Res*. 2022;3(2):1-2.
13. Gupta P, Karuna V, Grover K, Rathi M, Verma N. The histopathological spectrum of skin diseases with emphasis on clinicopathological correlation: A prospective study. *IP Journal of Diagnostic Pathology and Oncology* 2018;3(2):91-5.
14. Kafle SU, Chaudhary D, Yamu SY, Jha K. Diagnostic Significance of Clinicopathological Concordance in Various Spectrums of Skin Disorders. *Birat Journal of Health Sciences* 2020;5(1):955-9.
15. Nagar K, Shah N, Bhalodia J. Histopathologic pattern of skin diseases in tertiary health care centre: A retrospective study of 133 cases. *International Archives of Integrated Medicine* 2021;8(11).
16. Nageen S, Waqas N, Mehmood A. Association of clinical diagnosis with histopathology in various skin diseases. *Journal of Ayub Medical College Abbottabad-Pakistan* 2021;33(2).
17. Talwar A, Ballambat SP, Rao R, Shetty VM. Clinico-pathological correlation in Dermatological Disorders: A retrospective audit of 332 Skin biopsies from a tertiary care center. *Indian Dermatology Online Journal*. 2022 Dec.
18. Venugopal R, Shankar P, Pathania V. Clinicopathological correlation in the diagnosis of skin diseases: A retrospective study. *Med J DY Patil Vidyapeeth* 2020; 13:648-52.

19. Aslan C, Göktay F, Mansur AT, Aydınöz İE, Güneş P, Ekmekçi TR. Clinicopathological consistency in skin disorders: a retrospective study of 3949 pathological reports. *Journal of the American Academy of Dermatology*. 2012;66(3):393-400.
20. Al-Saif FM, Binsufayan SA, Alhussain AH, Alkaff TM, Alshaikh HM, Aldosari MS, et al. Clinicopathological concordance in the diagnosis of skin diseases: a retrospective analysis of 5000 histopathology reports. *Ann Saudi Med* 2019; 39(6): 388-394. DOI: 10.5144/0256-4947.2019.388
21. Rajaratnam R, Smith AG, Biswas A, Stephens M. The value of skin biopsy in inflammatory dermatoses. *The American Journal of Dermatopathology* 2009;31(4):350-3.
22. Mishra S. Assessment of Clinico-Pathologic Consistency in Diagnosing Skin Lesions: An Institutional Based Study. *Indian Journal of Basic & Applied Medical Research*; September 2012; (4)1: 377 – 82.
23. Malik A, Siraj F, Shruti S, et al. Clinicopathological Concordance in 2216 Cases of Skin Biopsy over One Year: An Indian Experience. *Cureus*2020; 12(4): e7752. DOI 10.7759/cureus.7752

UNDER PEER REVIEW