

## **Invasive urothelial carcinoma of the ureter with associated obstructive uropathy and chronic pyelonephritis: case report and literature review**

### **Abstract**

Urothelial carcinomas can develop from any urothelium lined surface in the body and they are the seventh most common cancers seen globally. Urothelial carcinoma of the upper urinary tract (involving the renal pelvis and ureter) is not common. Here we report the case of a 66-year-old male with invasive urothelial carcinoma affecting the distal one-third of the ureter with secondary obstructive uropathy and chronic pyelonephritis. No mass lesion or tumour was seen in the urinary bladder. Radical nephroureterectomy with excision of the bladder cuff was performed and the specimen was sent for histopathologic evaluation. This case report highlights the rare presentation of invasive urothelial carcinoma of the ureter and the role of radiologic imaging in diagnosis and thorough histopathologic evaluation in the determination of tumour grade and tumour stage and ultimate prognosis of patients. A high index of suspicion is needed for diagnosis based on presenting symptoms, and examination findings.

**Key words:** ureter, urothelial carcinoma, chronic pyelonephritis, obstructive uropathy, hydronephrosis.

## 1. Introduction

Urothelial carcinomas (UC) can develop from any urothelium lined surface in the body and they are the seventh most common cancers seen globally [1]. There are three types of UC including bladder urothelial carcinoma, upper urinary tract urothelial carcinoma (UTUC) and urethral urothelial carcinoma [1]. UTUC (involving the renal pelvis and ureter) is not common and it accounts for about 5% of all urothelial cancers while bladder urothelial carcinoma accounts for the remaining 90–95% of UC [1, 2].

UTUC have typically been typed as a single disease entity because of their common origin from the urothelium, however recent information about their clinical and epigenetic variations has revealed that renal pelvic and ureteral carcinomas may actually be two distinct tumours and that patients with ureteral urothelial carcinomas have a poor prognosis [2,3]

UTUC is seen more commonly in the elderly and it has been described to occur more frequently in males but a recent large systematic literature review reported that the specific gender predilection is uncertain [4].

About sixty percent of UTUCs are seen to be invasive at the time of diagnosis [4]. The diagnosis of UTUC may be an incidental finding or seen during diagnostic work-up following a high index of suspicion from presenting symptoms [5]. The most common presenting symptom seen in patients with UTUC is hematuria in up to 70 to 80% of cases [5].

Here we report the case of a 66-year-old male with high grade muscle invasive urothelial carcinoma affecting the distal one-third of the ureter with secondary obstructive uropathy and chronic pyelonephritis.

## 2. Case presentation

### 2.1. Clinical presentation

We hereby report the case of a 66-year-old male who presented with recurrent left flank pain, recurrent urinary tract infection and occasional hematuria of six month's duration. Physical examination at presentation showed pallor and abdominal tenderness in the left hypochondrium. Examination of other systems were unremarkable.

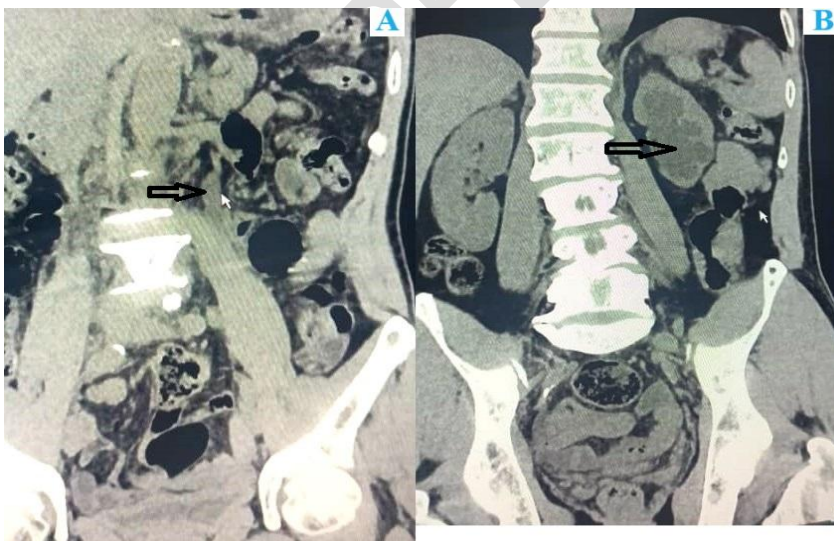**Comment [A1]:** You don't need points like this. I think you should combine the case presentation

### 2.2. Investigations findings

Diagnostic workup commenced with radiologic imaging and laboratory investigations.

Abdominal Computerized Tomography(CT) done showed moderate left hydro-ureter and hydro-nephrosis and a mass was seen in the lower one-third of the left ureter (figure 1A&B).

**Comment [A2]:** same



**Figure 1: 1A: CT image showing a mass in the distal one-third of the ureter (black arrow). 1B: CT image showing hydronephrosis (black arrow).**

The mass showed moderate enhancement on post contrast studies and measures 3.1x1.84cm in Longitudinal and transverse dimensions respectively. The right kidney and the right ureter were seen to be within normal limits. The urinary bladder was moderately distended with clear luminal contents, no mass lesion or tumour was seen. Features seen at CT was suggestive of a urothelial carcinoma of the distal left ureter.

Urinalysis showed turbid dark-yellow urine with moderate bacterial growth (of Escherichia coli) and 20-30 pus cells seen per high power fields on microscopy. The coagulation profile was within normal limits with prothrombin time of 14.6 seconds, partial thromboplastin time of 39.8 seconds and international normalized ratio of 1.08.

Liver function test showed elevated bilirubin (total bilirubin of 24 µmol/l & direct bilirubin of 4.8 µmol/l) and reduced total protein of 65g/l. Lipid profile was within normal limits. Electrolytes showed increased serum uric acid of 462 µmol/l and reduced magnesium of 0.76 mmol/l. urea and creatinine values were within normal limits.

Complete blood count showed blood group type A and anemia; with red blood cell count of  $3.92 \times 10^6$  cells, haemoglobin value of 12.2g/dl, hematocrit value of 35.6% and mean corpuscular haemoglobin concentration of 30.6g/dl.

### 2.3. Treatment

Comment [A3]: same

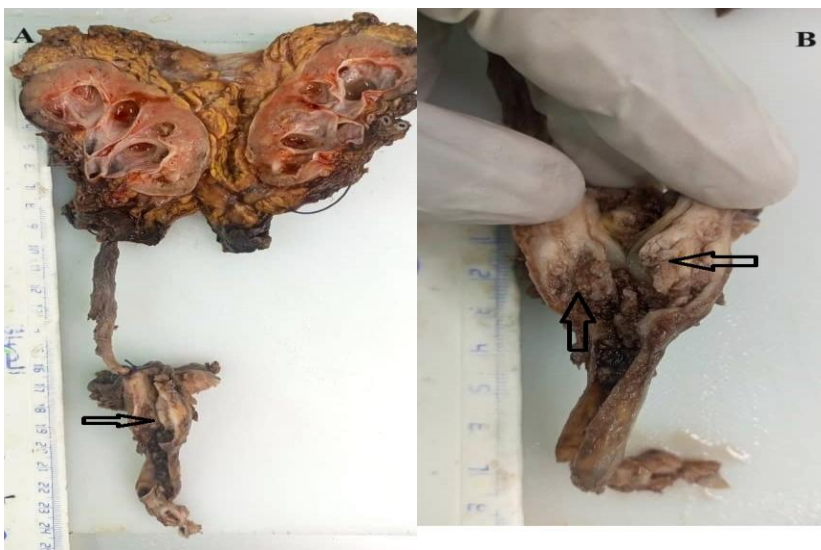Patient was admitted and had radical nephroureterectomy with excision bladder cuff and the sample was sent for histopathologic evaluation.

### 2.4. Histopathologic evaluation of specimen

Comment [A4]: same

2.4.1. Gross examination finding: The specimen received at surgical pathology grossing was a left nephrectomy specimen that weighed 145g and measured 10x7x3cm in dimension. The ureter measured 16.5 cm in length. The lower one-third of the ureter was dilated and cut

sections through the ureter showed a friable tan mass in the lumen causing near-complete occlusion with gross infiltration into the muscular wall (figure 2 A&B).



**Figure 2: 2A: image of gross specimen showing cut surfaces of the left kidney and ureter. There is a tan friable mass in the distal one-third causing lumen (black arrow). 2B: image of gross specimen showing a closer view of the ureter with tan friable tumour (black arrows).**

Cut sections through the kidney showed fair cortico-medullary differentiation with dilated pelvi-calyceal system. The lower pole showed areas of softness and severe congestion.

2.4.2. **Microscopic examination finding:** Sections of the ureteric mass showed features consistent with an invasive high-grade urothelial carcinoma. The cells show marked nuclear pleomorphism and are disposed in invasive nests, cords and solid sheets. The malignant cells

**Comment [A5]:** same

show areas of invasion into the muscularis propria of the ureter, the renal hilum and the renal parenchyma (figures 3 &4).

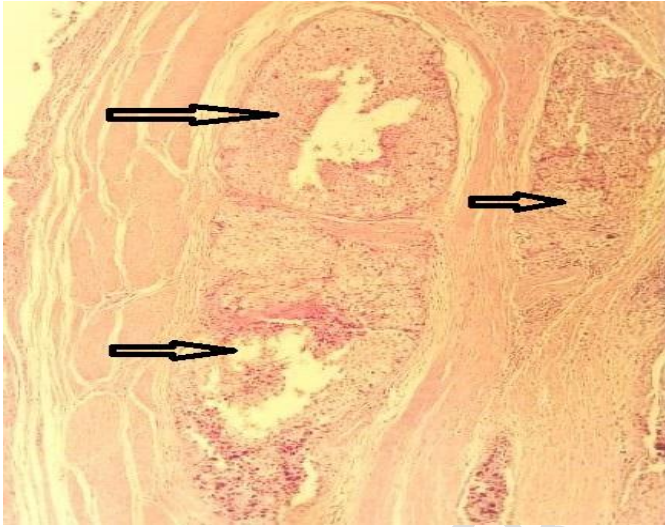
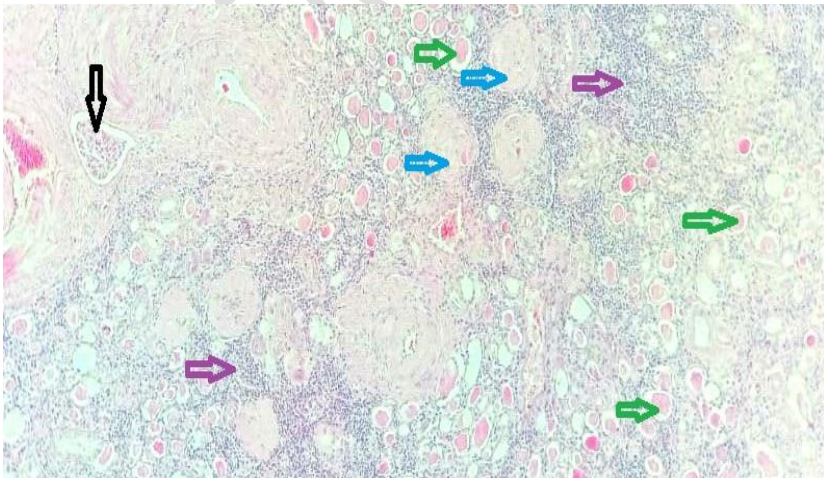


Figure 3: photomicrograph shows transverse section of the ureter with invasion of nests of high-grade urothelial carcinoma into the muscularis propria (black arrows). Haematoxylin and eosin stain, x200 magnification.



**Figure 4: photomicrograph shows section of the renal parenchyma with invasion of nests of high-grade urothelial carcinoma into a blood vessel (black arrows). There is thyroidization of the renal tubules (green arrows), glomerular sclerosis (blue arrows). and interstitial lymphocytic infiltrates (purple arrows). Haematoxylin and eosin stain, x200 magnification**

The Distal margin of resections of ureter and renal vein showed no tumour involvement.

Tumour stage: pT2 N0 M0.

#### 2.5. Patient follow-up and outcome

Patient had post-operative blood transfusion, he recuperated and was subsequently discharged for follow-up at the surgical outpatients' clinic with no adverse event reported till present (after one year).

### 3. Discussion

The incidence of UTUC is highest in the eight to tenth decades [5]. In our patient, the tumour occurred at a lower age group in the seventh decade. Renal calyceal and renal pelvistumours occur twice more commonly than ureteric tumours [5]. In 11-36% of UTUC cases, carcinoma-in-situ may co-exist while UTUC can be multifocal in 10-20% of cases [5]. More than 60% of UTUCs are already muscle invasive at the time of diagnosis and about 17% of cases occur synchronously with a bladder tumor [5]. In this index case, no mass lesion or tumour was seen in the urinary bladder.

Some of most common risk factors that have been associated with UC of the ureter include cigarette smoking and aristolochic acid[4]. There is also increasing epidemiologic and genetic proof that some UTUC occur as part of hereditary non-polyposis colorectal carcinoma (HNPCC) especially UC of the renal pelvis and ureter. This patient has no evidence supporting HNPCC or other known risk factors.

**Comment [A6]:** how can you make a diagnosis without evidence of metastasis? Do you have CT Scan of thorax or Xray or bone scan?

**Comment [A7]:** You should provide laboratory or imaging follow up.

Tumor grade and stage in UTUC are good predictors of clinical outcomes and prognosis[6]. Most World Health Organization (WHO) Grade 1 UC are non-invasive, while the higher-grade tumours (WHO grade 2 and 3) show invasion into the lamina propria or muscle layer ( $P \geq T2$ ) in 50 -60% of cases and up to 25% of patients presents with tumour metastasis at diagnosis [6, 7]. This is similar to what was seen in this our index case, at diagnosis the tumour was found to be high grade with invasion into the muscularis propria layer of the ureter (stage pT2). Despite this the prognosis appears good in the patient. No adverse event has been reported since surgical resection.

Asper the guidelines of the European Association of Urology (EAC), as part of routine diagnostic workup; CT urography, urine cytology, and cystoscopy should be done to rule out a co-existing bladder UC [4]. In our index case, according to the EAC guidelines, cystoscopy was done to rule out concomitant bladder UC.

Some studies have reported that the presence of preoperative hydronephrosis is a poor prognostic indicator for advanced disease [7]. In this index patient, there was hydronephrosis and chronic pyelonephritis secondary to obstructive uropathy caused by the ureteric obstruction.

The gold standard treatment for UTUC is a radical nephroureterectomy (RNU) with bladder cuff excision performed as an open or minimally invasive procedure [4]. This patient has surgery and the specimen was sent for histopathological evaluation and subsequently the diagnosis, tumour grade and stage were confirmed.

The TNM staging and classification system is the basis of the prognosis of patients with UTUC.[8] In this classification system, clinicians can determine the TNM stage according to the depth of tumor invasion (T), lymph node metastasis number (N) and distant metastasis (M), so that clinicians can make personalized treatment plans for patients and evaluate the prognosis of patients.

**Comment [A8]:** in your discussion, you were already mention. But, I didn't see evidences in your case presentation.

#### 4. Conclusion

This case presentation highlights the rare presentation of muscle invasive high grade urothelial carcinoma in the distal one-third of the ureter and the role of radiologic imaging in diagnosis and thorough histopathologic evaluation in the determination of tumour grade, stage, clinical management and ultimate prognosis of patients. A high index of suspicion is needed for diagnosis based on presenting symptoms, detailed history taking and physical examination.

#### Ethical considerations

This case report has no breach of Helsinki declaration. All departmental and instructional protocols were followed in the process of acquisition and use of clinical information. The patient's data has been completely de-identified for confidentiality.

#### References

1. Giudici N, Bonne F, Blarer J, Minoli M, Krentel F, Seiler R. Characteristics of upper urinary tract urothelial carcinoma in the context of bladder cancer: a narrative review. *Transl Androl Urol.* 2021;10(10):4036-4050. doi.org/10.21037/tau-20-1472
2. Qiwei C, Jiajun S, Cheng L, Shengbo H, Yue K, Shujing W, et al. Comparison between renal pelvic and ureteral tumors in muscle-invasive upper tract urothelial carcinoma. *Cancer Sci.* 2023;114(3):984-994. doi:10.1111/cas.15634

**Comment [A9]:** You should provide minimum 10 references

3. Roupret M, Babjuk M, Burger M, Capoun O, Cohen D, Comperat EM, et al. European Association of Urology guidelines on upper urinary tract urothelial carcinoma: 2020 update. *Eur Urol*. 2021; 79:62-79. doi.org/10.1016/j.eururo.2020.05.042
4. Gravestock P, Cullum D, Somani B, Veeraterapillay R. Diagnosing upper tract urothelial carcinoma: a review of the role of diagnostic ureteroscopy and novel developments over last two decades. *Asian Journal of Urology*. 2022; doi.org/10.1016/j.ajur.2022.08.003
5. Cassell A., Manobah B, Willie S. Diagnostic and Therapeutic Challenges of Rare Urogenital Cancers: Urothelial Carcinoma of the Renal Pelvis, Ureters and Urethra. *World J Oncol*. 2021;12(1):20-27. doi.org/10.14740/wjon1360
6. Blaszyk H, Wang L, Dietmaier W, Hofstädter F, Burgart LJ, Cheville JC, et al. Upper Tract Urothelial Carcinoma: A Clinicopathologic Study Including Microsatellite Instability Analysis. *Mod Pathol* 2002;15(8):790–797. doi: 10.1097/01.MP.0000024263.25043.0C
7. Petros FG. Epidemiology, clinical presentation, and evaluation of upper-tract urothelial carcinoma. *Transl Androl Urol*. 2020;9(4):1794-1798. doi:10.21037/tau.2019.11.22
8. Tsikitas LA, Hopstone MD, Raman A, Duddalwar V. Imaging in Upper Tract Urothelial Carcinoma: A Review. *Cancers*. 2023; 15(20):5040. doi.org/10.3390/cancers15205040