

## **A Case report on IRVAN syndrome**

### **Abstract :**

Idiopathic retinal vasculitis, arteriolar macroaneurysms, and neuroretinitis (IRVAN) is a rare condition predominantly affecting young, healthy females without systemic disease. We present the case of a 35-year-old female who presented with a 3-month history of decreased visual acuity without associated symptoms.

Ophthalmological examination revealed reduced visual acuity in both eyes, papillary oedema, stellate macular oedema, and haemorrhages bilaterally.

Retinal imaging confirmed IRVAN syndrome. Treatment included pan-retinal photocoagulation (PRP) and intravitreal bevacizumab injections, resulting in macular oedema regression.

**Key Words :** Vasculitis- Arteriolar macroaneurysms- Neuroretinitis - Anti VEGF- PRP

### **Introduction :**

"Idiopathic retinal vasculitis, arteriolar macroaneurysms, and neuroretinitis (IRVAN) is a rare clinical entity typically observed bilaterally in a young, healthy female without any systemic disease". [1] "Retinal vessel inflammation can occur in conjunction with different ocular inflammations and systemic vascular diseases, or it may be of unknown origin. Phlebitis is typically more prevalent than arteritis. Arterial involvement is frequent in IRVAN, a condition linked with multiple aneurysmal dilatations of the retinal arterioles and the optic nerve head. Peripheral capillary non-perfusion, retinal neovascularization, and macular exudation are additional characteristics of this condition. Failure to treat it promptly can result in severe vision-threatening complications". [1-3]

Numerous treatments have been used to treat the IRVAN syndrome such as intravitreal injection of anti-vascular endothelial growth factor (VEGF) [4,5] and pan-retinal photocoagulation (PRP) for ischemic areas.

Our case highlights the clinical presentation, diagnostic workup, and management challenges of IRVAN, emphasizing the importance of continued monitoring and adherence to treatment protocols.

### **Case presentation :**

We present the case of a 35-year-old female who was admitted to our department with a three-month history of decreased visual acuity, without any other associated symptoms. Ophthalmological examination revealed a best-corrected visual acuity (BCVA) of 2/10 in the right eye and 3/10 in the left eye, with no abnormalities detected in the anterior

segment examination. Fundus examinations showed papillary oedema with stellate macular oedema and scattered haemorrhages in all four quadrants, along with pre-retinal haemorrhages in both eyes (Fig 1). A comprehensive clinical examination of the other systems reveals no abnormalities. Fluorescein angiography (FFA) revealed aneurysmal dilatations along the arterial pathways in the right eye and peripheral ischemia in both eyes (Fig 2). Macular Optical Coherence Tomography (OCT) demonstrated bilateral macular oedema (Fig 3). A comprehensive biological assessment, including serology and immunology, returned normal results. The patient underwent extensive pan-retinal photocoagulation (Fig 4) in addition to intravitreal injections of Bevacizumab in both eyes. The patient's course was characterized by regression of macular oedema (Fig 5) but without improvement in her BCVA.

### **Discussion :**

"The IRVAN syndrome (Idiopathic Retinal Vasculitis, Aneurysms, and Neuroretinitis) was first defined in 1983 by Kincaid and Schatz"[3]"It is a retinal disorder of unknown etiology. The diagnosis of IRVAN is based on three major elements: multiple aneurysmal dilatations, retinal vasculitis, and neuroretinitis at the arterial bifurcation"[6-8].

Samuel et al [2] categorized the progression of the disease into five stages: Stage I : encompasses microaneurysms, exudation neuroretinitis and retinal vasculitis. Stage 2 is characterized by capillary non-perfusion as evidenced by FFA . Stage 3 manifests as neovascularization in the posterior segment, either at the disc or elsewhere, and /or vitreous haemorrhage. In stage 4, there is the presence of anterior segment neovascularizations specifically rubeosis iridis. Stage 5 is marked by neovascular glaucoma. Accordingly, our patient exhibits features consistent with stage 2 of the disease

PRP stands as the singularly recognized treatment method in cases of peripheral ischemia or neovascularization, and its early implementation is crucial to ward off complications arising from ischemia. PRP commonly demonstrates effectiveness, particularly in stages 2 and 3 of the disease[9]. Rouvas et al [10], recommended delaying pan-retinal photocoagulation (PRP) when peripheral ischemia affects fewer than two quadrants of the retina.

Numerous treatments have been used for IRVAN syndrome, with varying degrees of efficacy. Intravitreal injections of anti-VEGF agents, bevacizumab and ranibizumab, have produced favourable results.[5,10,11]

Recently, Cheema et al [12] proposed that "infliximab therapy could be beneficial in mitigating inflammation and leakage from the optic nerve, based on their observation in two cases of treatment-resistant IRVAN syndrome".

Sawhney et al. [13] utilized "PRP in the regions of retinal ischemia and aneurysmal dilatations following three bevacizumab injections for a patient with stage 3 IRVAN

syndrome. Over the subsequent 8 months, the patient received monthly treatment comprising seven additional bevacizumab injections, one intravitreal dexamethasone implant, and one periocular triamcinolone injection. Later, a pars plana vitrectomy was performed to remove the epiretinal membrane and alleviate vitreomacular traction. The macular lipid exudation had completely resolved with a residual lamellar hole".

"Eale's disease could be a differential diagnosis of IRVAN syndrome due to the presence of retinal vasculitis and peripheral non-perfusion features. Furthermore, Eale's disease is more likely to be found in the retinal veins instead of arterioles. Also, multiple aneurysms and optic nerve head vascular tortuosity distinguish IRVAN syndrome from Eale's disease"[14]

### **Conclusion :**

The IRVAN syndrome is thus a highly characteristic clinical picture due to its angiographic features, to be considered in any posterior uveitis that combines neuroretinitis with arterial vasculitis, especially in the case of a young woman. It is crucial to investigate any underlying inflammatory or vascular pathology to confirm the idiopathic nature of this condition.

Once the diagnosis is established, it is crucial to treat retinal periphery ischemia and to conduct regular follow-ups to ensure the absence of evolving complications that may arise during its course.

#### Consent

As per international standards or university standards, patient(s) written consent has been collected and preserved by the author(s).

#### Ethical Approval:

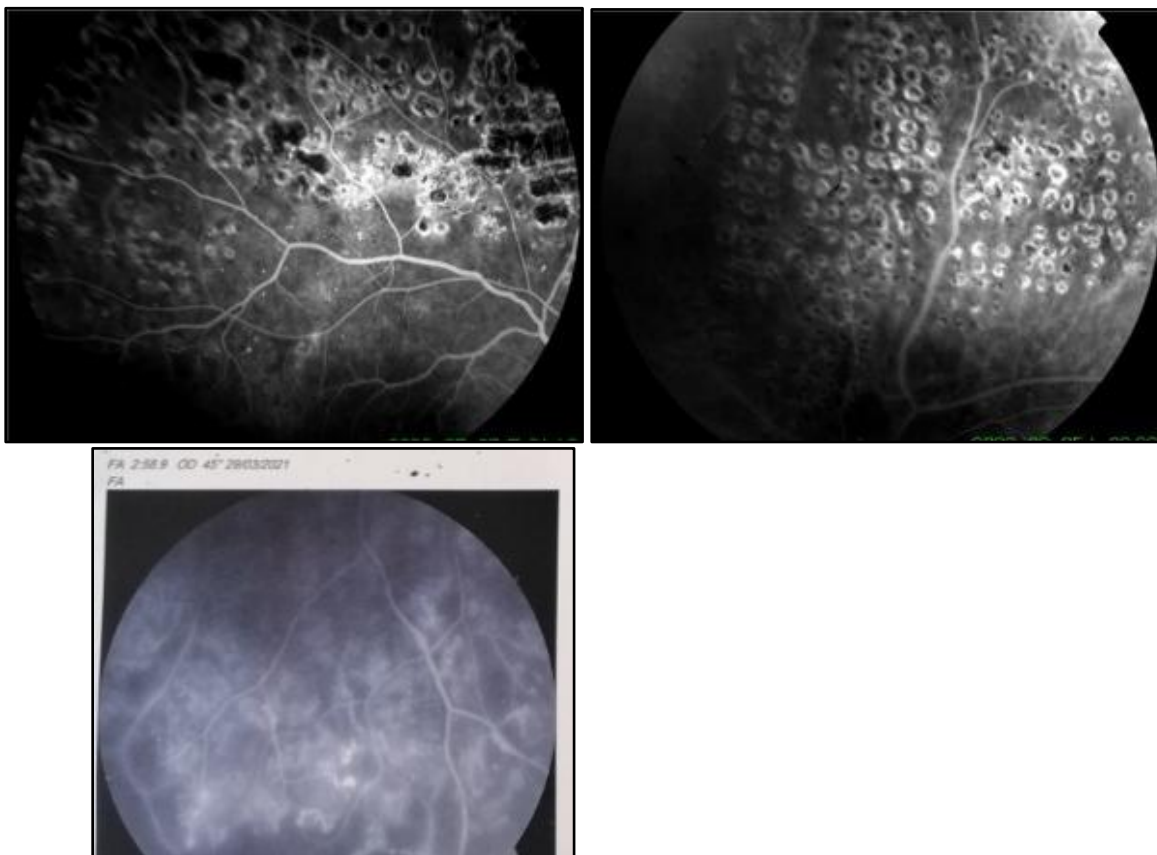
As per international standards or university standards written ethical approval has been collected and preserved by the author(s).

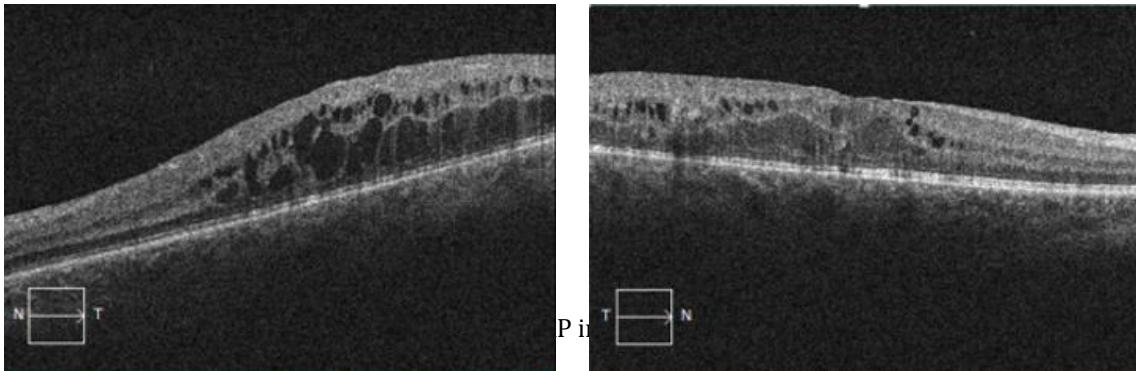
### **Images :**

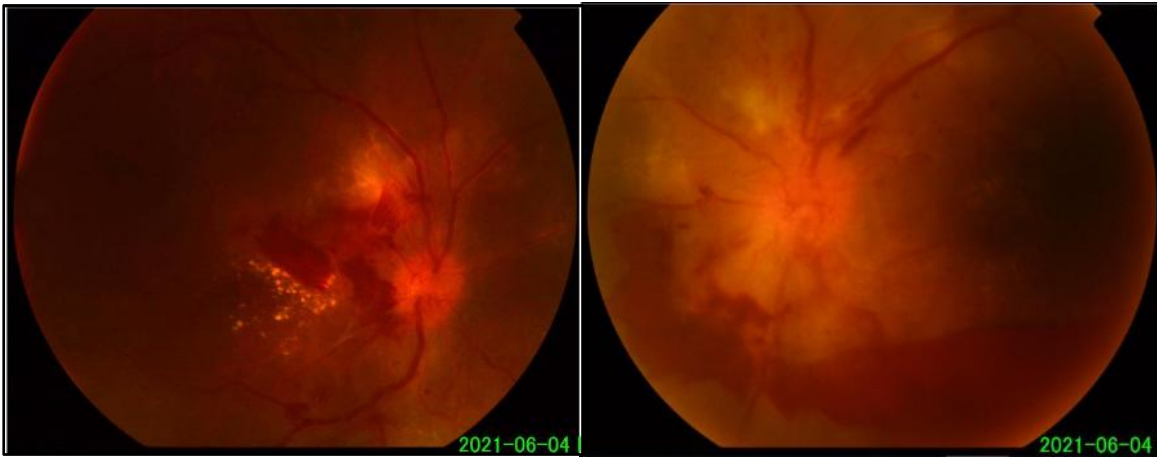

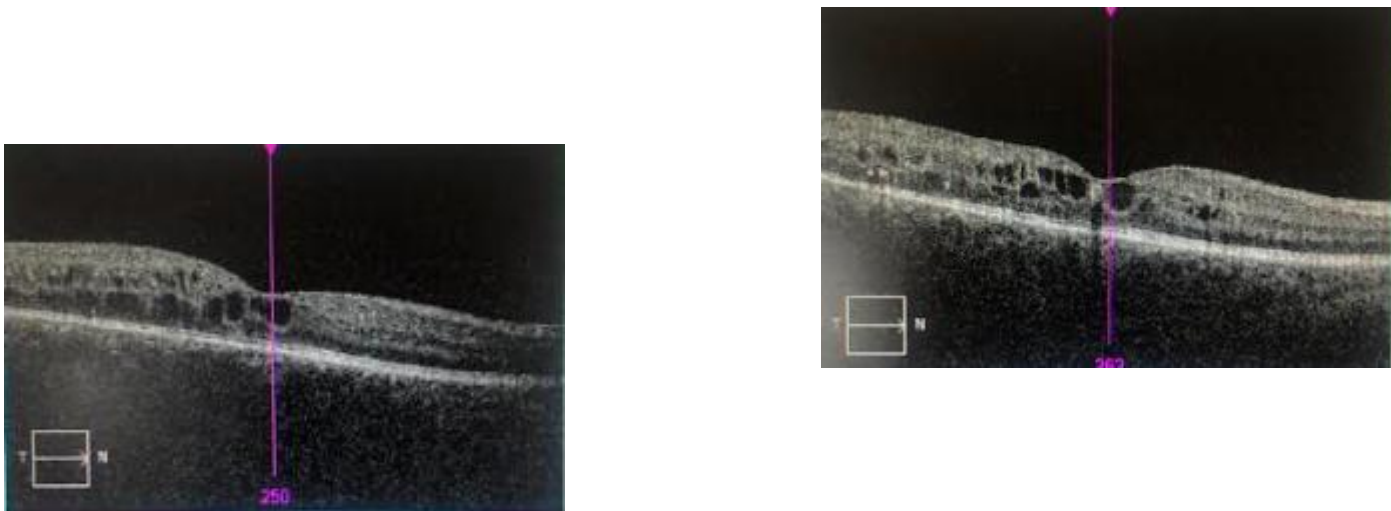
Figure 1: Color fundus photograph of the right and the left eye showing neuroretinitis with pre-retinal hemorrhages in both eyes

Figure 2 :  
Fluorescein angiography showing aneurysmal dilatations with peripheral ischemia in the right eye





**Figure 4 :** The macular Optical Coherence Tomography (OCT) showed diffused retinal thickening right eye and cystoid macular edema of the left eye



**Figure 5 :** The macular Optical Coherence Tomography (OCT) post one cycle of intravitreal injections of Bevacizumab

**REFERENCES :**

1. Chang TS, Aylward GW, Davis JL, Mieler WF, Oliver GL, Maberley AL, et al. Idiopathic Retinal Vasculitis, Aneurysms, and Neuro-retinitis. *Ophthalmology*. 1 juill 1995;102(7):1089- 97.

2. Samuel MA, Equi RA, Chang TS, Mieler W, Jampol LM, Hay D, et al. Idiopathic retinitis, vasculitis, aneurysms, and neuroretinitis (IRVAN): new observations and a proposed staging system. *Ophthalmology*. août 2007;114(8):1526-1529.e1.
3. Kincaid J, Schatz H. Bilateral retinal arteritis with multiple aneurysmal dilatations. *Retina*. 1983;3(3):171- 8.
4. Karagiannis D, Soumplis V, Georgalas I, Kandarakis A. Ranibizumab for idiopathic retinal vasculitis, aneurysms, and neuroretinitis: favorable results. *Eur J Ophthalmol*. août 2010;20(4):792- 4.
5. Akesbi J, Brousseau FX, Adam R, Rodallec T, Nordmann JP. Intravitreal bevacizumab (Avastin) in idiopathic retinitis, vasculitis, aneurysms and neuroretinitis. *Acta Ophthalmol*. mars 2010;88(2):e40-41.
6. Banaee T, Hosseini SM. Optical Coherence Tomography Features in Idiopathic Retinal Vasculitis, Aneurysms and Neuroretinitis Syndrome. *J Ophthalmic Vis Res*. 2015;10(2):193- 6.
7. Pichi F, Ciardella AP. Imaging in the diagnosis and management of idiopathic retinal vasculitis, aneurysms, and neuroretinitis (IRVAN). *Int Ophthalmol Clin*. 2012;52(4):275- 82.
8. Lin X, Meng Z, Deng A, Chen X, Wang S, Gu S, et al. The multimodal imaging characteristics of IRVAN syndrome: a case report. *Am J Transl Res*. 15 août 2021;13(8):9866- 73.
9. Mansour M, Al-Ghotani B, Abo-Shdeed B, Jannoud O. IRVAN syndrome: A case report and a literature review. *Annals of Medicine and Surgery*. 1 mai 2022;77:103725.
10. Rouvas A, Nikita E, Markomichelakis N, Theodossiadis P, Pharmakakis N. Idiopathic retinal vasculitis, arteriolar macroaneurysms and neuroretinitis: clinical course and treatment. *J Ophthalmic Inflamm Infect*. 25 janv 2013;3:21.
11. Basha M, Brown GC, Palombaro G, Shields CL, Shields JA. Management of IRVAN syndrome with observation. *Ophthalmic Surg Lasers Imaging Retina*. 1 mai 2014;45 Online:e18-22.
12. Cheema RA, Al-Askar E, Cheema HR. Infliximab therapy for idiopathic retinal vasculitis, aneurysm, and neuroretinitis syndrome. *J Ocul Pharmacol Ther*. août 2011;27(4):407- 10.
13. Sawhney GK, Payne JF, Ray R, Mehta S, Bergstrom CS, Yeh S. Combination anti-VEGF and corticosteroid therapy for idiopathic retinal vasculitis, aneurysms, and neuroretinitis syndrome. *Ophthalmic Surg Lasers Imaging Retina*. 1 nov 2013;44(6):599- 602.
14. Bajgai P, Katoch D, Dogra MR, Singh R. Idiopathic retinal vasculitis, aneurysms, and neuroretinitis (IRVAN) syndrome: clinical perspectives. *Clinical Ophthalmology*. 6 oct 2017;11:1805- 17.

