

# OPTIMIZATION OF ORAL REHABILITATION: USE OF ARTIFICIAL INTELLIGENCE IN THE MANUFACTURE OF PROTOCOL-TYPE PROVISIONAL PROSTHESES WITH IMMEDIATE LOADING FOR MAXILLAE

## ABSTRACT

The use of Large Language Model (LLM) technologies, such as Artificial Intelligence (AI) with Deep Learning and Machine Learning software, has become commonplace in surgical planning, enabling the capture, manipulation and digital planning of immediately loaded provisional prostheses for dental implants. **Materials and Methods:** this literature review a search was made for scientific articles in virtual databases: PUBMED, ScIELO, Google Scholar, LILACS, BVS, ResearchGate. Articles that were not part of dentistry were excluded based on the theme of the Abstract. The 28 articles pertinent to dentistry and the theme of the abstract were included and fully analyzed. The following were aligned and distributed in the literature review: systematic reviews, literature reviews, clinical cases, laboratory studies, books, theses and dissertations. **Conclusion:** The improvement of Artificial Intelligence in dentistry is enabling better planning and practical-surgical-prosthetic execution with the creation and printing of provisional prostheses with immediate loading, better retention, occlusal stability, less repair and a pleasant biopsychosocial sensation, since it eliminates instability due to the mechanical displacement of overdentures.

**Keywords:** Oral Rehabilitation; Artificial Intelligence; Dental Prosthesis; Digital Planning.

## 1. INTRODUCTION

Oral rehabilitation with protocol prostheses is an alternative fixed prosthesis on osseointegrated implants, made of resin or metal-ceramic, for total edentulous mandibles and/or maxillae. They are used as a fixed alternative for aesthetic and functional rehabilitation of the stomatognathic system. However, between the surgical phase and the definitive prosthesis, there is a transition period in which the patient waits to receive the permanent prosthesis on implants, a period of between 28 and 180 days due to the recommendations of each implant manufacturer. Previously, the solution to prevent the patient from being toothless for the entire waiting period was to use temporary total prostheses. The instability of these prostheses brought discomfort to the patient and the possibility of losing the implants. With the advent of new technologies and virtual planning, new possibilities have emerged to help patients during the transition period with more adapted and fixed provisional prostheses<sup>1</sup>.

Temporary protocol prostheses with immediate loading in the maxilla for patients surgically rehabilitated with dental implants have become increasingly popular. It has become an excellent rehabilitation option in terms of patient adaptation and convenience, as well as providing practicality for the dental surgeon due to the fewer workflow steps between the surgical phase and the prosthetic phase<sup>1</sup>.

Due to the current high cosmetic demand and technical-scientific progress in prosthetic execution, totally edentulous patients who are rehabilitated with dental implants have the alternative of immediate installation of dental prostheses on implants. What used to be seen as something detrimental to primary stability is now known that the secondary stability provided by the immediately loaded provisional protocol prosthesis ensures primary stability between the bone and the implant, providing better post-surgical recovery, as long as the micromovements between prosthesis and implant do not exceed 0.0028 millimeters<sup>1,2</sup>.

This is only possible due to better surface treatment of dental implants in response to tissue biology, the quality and quantity of bone available, and the patient's stable systemic condition. These factors, coupled with excellent surgical planning by the dental surgeon, improve the possibility of mechanical locking of the implant and the opportunity for immediate prosthetic loading<sup>3</sup>.

The term immediate loading was coined by Schnitman in 1990, with the placement of up to six mandibular implants distributed between the mental foramina and two more distal implants to reduce the cantilever, with the installation and active function of an immediate implant-supported protocol prosthesis. Currently, immediate loading is defined as prosthetic rehabilitation without delay 48 hours or two weeks after the installation of osseointegrable implants with a minimum primary stability of 40 Newtons per centimeter of force, the prosthesis must be screwed in and have active function<sup>4</sup>.

In contemporary times, the use of Large Language Model (LLM) technologies has become commonplace in surgical planning, with software that allows digital capture, manipulation and planning with oral and facial structures, as well as obtaining references from the Frankfurt's plane, Camper's plane, Curve of Wilson, Curve of Spee, Curve of Monson and compensatory curves the patient's aesthetic references<sup>5,6</sup>.

Using computed tomography and intraoral and facial scanners, patient data is collected and transferred to software that allows data manipulation and the creation of prosthesis plans with specifications for the shape, size and details of teeth and surrounding structures. Patient data is synthesized for virtual planning<sup>5</sup>.

These software's are compared to brains that read the patient's data using artificial neural networks. Each piece of information from the virtual patient has a specific weight that is read by an algorithm. The set of information is connected to each other through synapse-weights and forms artificial neurons. These are responsible for identifying patterns and connections with other data in order to make it possible to create more combinations of data to ensure better planning of patient information<sup>7,8</sup>.

From the set of neural networks, the algorithms execute propositions that are responsible for creating characters that form 2D and 3D images. This data is constantly compared with each other so that a new database can be created. This artificial brain processing flow ensures that the database provided helps to create and solve oral rehabilitation cases with protocol prostheses on immediately loaded osseointegrated implants<sup>7,8,9</sup>.

In dentistry, artificial intelligence has the subgroups of neural networks of the Machine Learning (ML) and Deep Learning (DL) type, which are the most widely used to learn, recognize and compare data patterns and perform tasks that enable better planning and decision-making in dental diagnoses<sup>10</sup>.

The digital tools required for a processing flow that enables oral rehabilitation with dental prostheses using artificial intelligence are computerized tomography, intraoral and facial

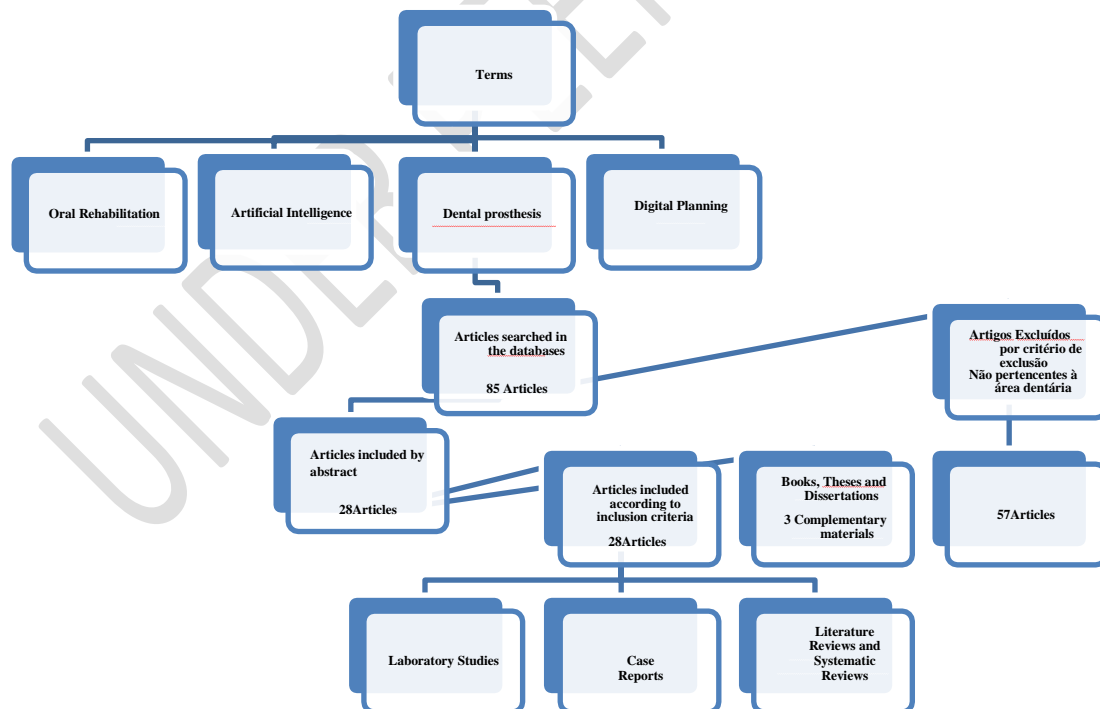
scanners, computer-aided design (CAD) software such as BlueSky, Mesh Mixer, Dental Slice, 3D Builder, computer-aided manufacturing (CAM), such as milling and 3D printing <sup>5</sup>.

The aim of this study is to carry out a literature review on the applicability of artificial intelligence in the manufacture of temporary, immediately loaded prostheses after the installation of osseointegrated implants in the maxilla.

## 2. MATERIALS AND METHODS

For the synthesis of this literature review, a search was made for scientific articles in virtual databases: PUBMED ([www.pubmed.gov](http://www.pubmed.gov)), ScIELO ([www.scielo.org](http://www.scielo.org)), Google Scholar ([www.scholar.google.com.br](http://www.scholar.google.com.br)) VHL (<https://bvvsalud.org/>) and LILACS (<https://lilacs.bvvsalud.org/>), and ResearchGate ([www.researchgate.net](http://www.researchgate.net)).

An accurate search was carried out and papers published between 2018 and 2024 were selected from the title of the literature review based on the combination of the following descriptors in Portuguese and their respective analogues in English: Oral Rehabilitation. Artificial Intelligence. Dental Prosthesis. Digital Planning. Articles that were not part of dentistry were excluded based on the theme of the Abstract. The 28 articles pertinent to dentistry and the theme of the abstract were included and fully analyzed. The following were aligned and distributed in the literature review: systematic reviews, literature reviews, clinical cases, laboratory studies, books, theses and dissertations (Figure 1).



**Figure 1:** Flowchart of article inclusion criteria.

### 3. LITERATURE REVIEW AND DISCUSSION

#### 3.1. Immediate Load Implant-Supported Fixed Prostheses

With the growing technological-scientific-practical development of oral rehabilitation, it is clear that the methods for restoring occlusal stability and aesthetics to the patient's stomatognathic system are undergoing increasing therapeutic remodeling. The use of osseointegrated implants in edentulous jaws has opened up new avenues for the development of protocol-type fixed prostheses with better retention, occlusal stability, less repair and a pleasant positive biopsychosocial sensation of security felt by the patient, since it eliminates the instability offered by the mechanical displacement caused by overdentures <sup>11</sup>.

Protocol-type implant-supported fixed prostheses are screw-retained prostheses with a minimum of four osseointegrated implants in edentulous maxillae and/or mandibles. They can be made with a metal base in Ti (Titanium), CrCo (Cobalt Chrome), milled or cast 5 mm thick and 4 mm high, with or without retainers on the surface and coated with acrylic resin and resin teeth. They can also be produced with a Ti or Zr (Zirconia) metal base and veneered with feldspathic or reinforced ceramics. However, for prosthetic excellence, implant surgical planning must embrace good implant distribution in order to reduce cantilevers <sup>12</sup>.

There is also the protocol prosthesis on immediately loaded implants of the fixed provisional type. This provisional fixed prosthesis covers the transition between the surgical phase and the permanent prosthetic phase for patients rehabilitated with dental implants. It reduces the patient's treatment time and avoids the use of immediate removable mucosupported prostheses, which cause instability and high rates of micromovements due to axial and transverse loads on the implants. These movements cause fibrous neoforations around the implant surface and its consequent loss. As for the material, it can be made of acrylic resin and resin teeth with or without reinforcement by metal wires, as well as being coated with PEEK (Polyetheretherketone), or printed on 3D printers using resins reinforced with zirconia, and then made up and glazed with specific resins for 3D printing <sup>1,2,13</sup>.

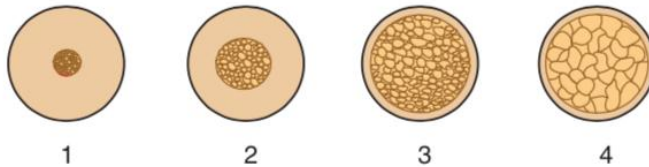
The term immediate loading was proposed by Schnitman in 1990, in a 10-year follow-up study in which surgical procedures were carried out to install 5 to 6 osseointegrated implants with 40 Ncm (Newtons per Centimeter) of primary locking in mandibular edentulous patients, and installation of a full mouth captured prosthesis over the implants immediately. It was concluded that 84.7% of the patients who underwent oral rehabilitation with an immediate provisional fixed prosthesis were successful, and 100% were rehabilitated with a fixed prosthesis on implants 3 months after surgery. The method was successful for the 7 patients in the study in the group that used immediate protocol fixed prostheses. The term immediate loading has been defined as a technique that uses a full or partial prosthesis captured in the mouth within 48 hours or two weeks after the patient is newly rehabilitated with non-osseointegrated dental implants <sup>14,15</sup>.

**In order to install the fixed provisional protocol prosthesis with immediate loading, some factors must be considered when planning the dental surgeon, such as:** stable patient health parameters, the patient's bone quantity and quality must be between bone type I (thick cortical bone), II (dense cortical and trabecular bone) and III (thin cortical and trabecular bone of resistance) <sup>3</sup>.

According to Vargas et al., 2022 as well as França, Paraguassu, 2023, implants with surface treatment, good distribution positioning in the dental arch from prototyped surgical

guides that allow the formation of a polygon with a more distal base to avoid cantilever in the prosthesis, and mechanical locking of the implant of 40 Newtons per centimeter are more favorable to stability. Type IV bone is not very suitable because it has low levels of mechanical strength, which makes it impossible to achieve better mechanical locking (Figure 2) <sup>1,16</sup>.

**Figure 2:** Bone types I, II, III and IV.



Source: Google Image

The development of forms of oral rehabilitation with immediately loaded maxillary protocol prostheses has made the patient's therapeutic treatment integrated. Today, they benefit from the flow of work using AI technologies with materials that provide aesthetics and loading. This has reduced the waiting time for prostheses on implants, while at the same time affecting the biopsychosocial factor, bringing returns in terms of chewing safety, social coexistence in the positive domains of mood, socioeconomic activities and appearance <sup>11</sup>.

### **3.2. Analog and Digital with Artificial Intelligence**


There is the conventional-analog method and the digital flow method with the aid of artificial intelligence for making provisional prostheses such as fixed protocols. In the first method, the dental surgeon takes a functional impression of the edentulous patient's arches and provides the laboratory with the test base and wax plan for try-in and measurement of the guidelines. After gathering the patient's information on the test base and wax plan, the patient's models are mounted in an articulator so that the teeth can be mounted and then acrylicized. Intraoral and facial photographs help in the process of making the provisionals by mediating the shape of the face, bipupillary arrangement, smile lines, and other anatomies of the patient so that the laboratory can make a prosthesis that will be captured in the mouth with self-curing acrylic resin and metal provisional cylinders on implants.

The second digital processing method requires the patient to be scanned intraorally and facially. The scan captures referential information to obtain the patient's Frankfurt plane, Camper plane, Spee curve, Wilson curve, Manson curve, compensation curves and aesthetic information. With the information from the scanner, the file can be exported to image creation and processing software that enables the composition of teeth and gingival structures according to the patient's physical anatomy for printing the 3D prosthesis and subsequent make-up and capture in the mouth with provisional metal cylinders on implants and self-curing acrylic resin <sup>11</sup>.

The digital world we know today only became more elaborate because of the work done by mathematicians in the 19th century. In the Second World War, British autistic mathematician Alan Mathison Turing was recruited by the British government to work at the Government Code and Cipher School (GC&CS). At this military base, Alan created a machine capable of decoding Nazi German naval codes that brought victory for the Allies against Hitler's Germany.

Called the "Turing Machine" (Figure 3), it is an abstract computer model that works with 03 instructions because its memory, state and transitions are subordinate to an algorithm. The machine deciphered cryptographic codes issued from the Enigma Machine hours before the Nazi military attacks. Although many of Alan M. Turing's articles have not yet been released to the world because they are protected by the British State Secret, Turing is considered the father of computing and a pioneer of Artificial Intelligence, due to his contributions to what we now conceive of as the digital age <sup>17</sup>.

**Figure 3:** Turing Machine and its creator Alan Mathison Turing.



Source: Google Image

With Turing's contributions to the world of computing, dentistry has benefited. Today, the flow of digital processing is making room for Artificial Intelligence (AI). AI has emerged as an integrative technique capable of bringing sophistication, security to digital planning, patient comfort and improved working techniques for dentists. AI has several areas of activity and is concerned with knowing, creating and applying the results of what has been entered into its database in an intelligent and autonomous way <sup>18</sup>.

Unlike the conventional method, which requires more chair time and planning by the dental surgeon in conjunction with the laboratory, as well as the use of more clinical materials, physical space to accommodate the plaster models, and the patient's availability for more clinical stages of treatment execution, the digital method using artificial intelligence has an intraoral molding method and the possibility of multiple combinations that are offered to the dental surgeon to incorporate into his case planning, reducing time, space and bringing convenience to the patient <sup>5</sup>.

### **3.3. Artificial Intelligence in Oral Rehabilitation Dentistry**

In dentistry, especially in oral rehabilitation, AI has the most well-known subgroups: Machine Learning (ML) and Deep Learning (DL). These help in the process of planning patient cases. ML initially needs to be fed by an input database, which is an action performed by humans. From this data, useful trends, schemes and rules will be extracted to formulate hypothetical predictions that can be used within the dental surgeon's planning <sup>19</sup>.

On the other hand, the patient's database, such as images and videos, is entered into planning software, which recognizes and determines useful patterns and schemas to be

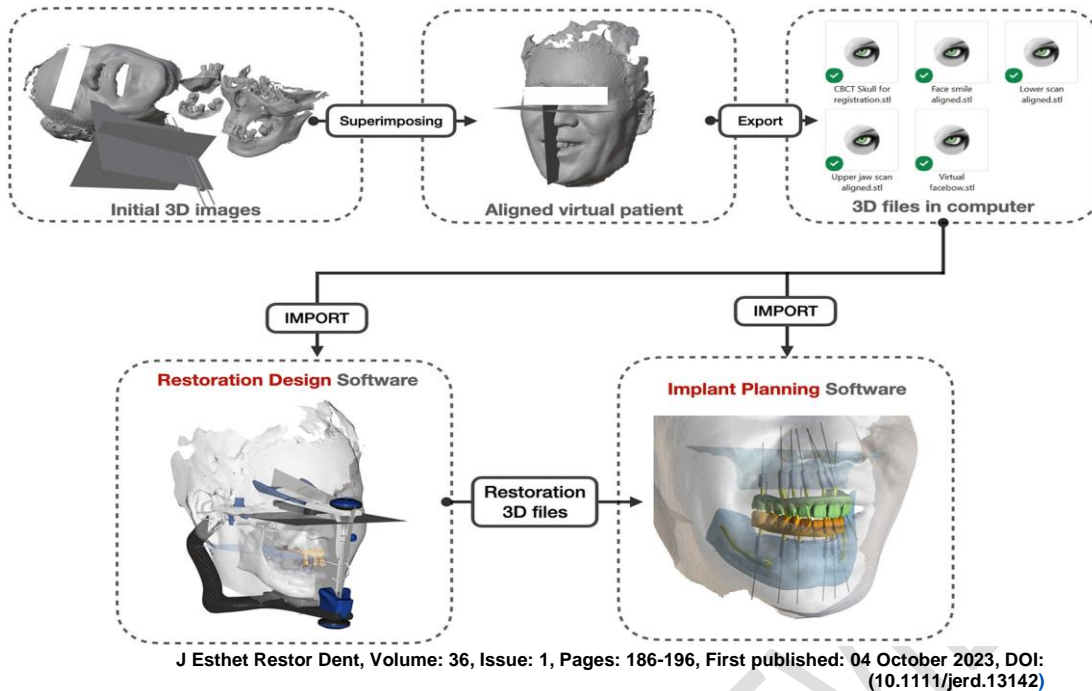
categorized. Afterwards, the dental surgeon is given planning predictions for oral rehabilitation, such as the shape, size of teeth, positioning, prosthesis bases and implants according to the patient's characteristics. Within the software where the patient's CT scan is inserted, a subgroup of ML, called Convolutional Neural Networks (CNNs), are responsible for detecting tissue structures and categorizing them, such as right and left side, male and female, bite, jaw structure, temporomandibular disorders (TMD), etc. <sup>20</sup>.

Deep Learning (DL) is a subgroup of Artificial Intelligence in machine algorithms. It is made up of multi-level layers, and does not require human activity to have databases, since Machine Learning has already provided the data weights. DL enables analysis, classification of these analyses and provides predictability of variables for oral rehabilitation results through the patient's tomography, intraoral and facial scans. Due to its neural networks and the connectivity between each layer, DL enables the capture of tissue edges, lines and subtleties, as well as the analysis of bite overload due to TMD, which are fundamental for good planning of temporary maxillary protocol prostheses. Capturing details ensures greater confidence and less chance of errors when capturing the prosthesis in the mouth, and less occlusal adjustment <sup>21</sup>.

Traditionally, in order to optimize the planning and work flow in oral rehabilitation with temporary maxillary protocol prostheses, it is necessary to have patient documentation. This documentation consists of: computed tomography, intraoral and facial scans, and a 3D model, as well as the type and diameter of the implant that will be proposed for the patient. All documentation goes through AI processing and its subgroups, such as ML and DL <sup>22,27,28</sup>.

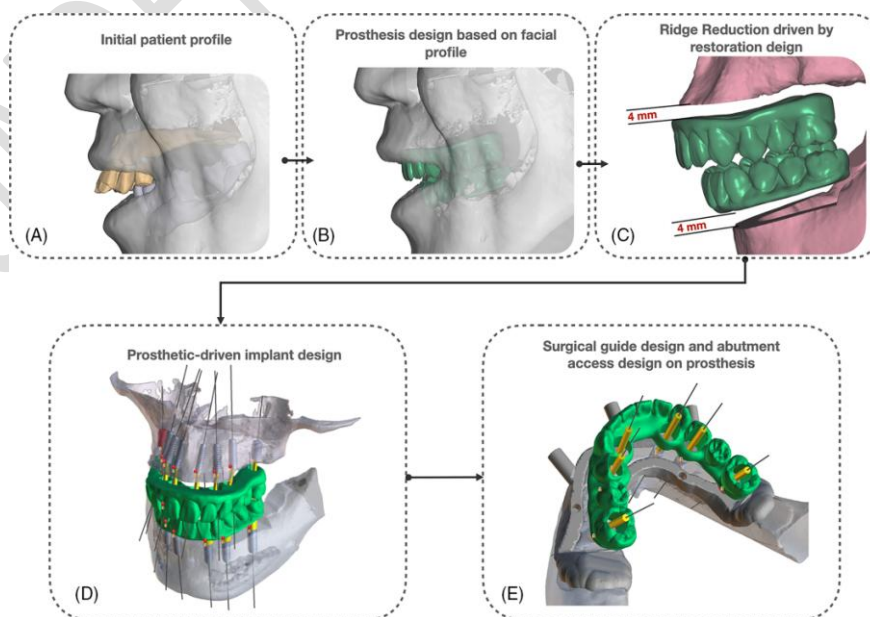
The tomography with the patient's tissue layout will be displayed in a virtual planning software using ML and DL, such as BlueSky Plan, Exocad, Mesh Mixer, which allows you to read, analyze, formulate and execute proposals that best suit the patient when designing the temporary prosthesis for immediate installation under implants. The program's dental surgeon operator will have a choice of protocol prosthesis models in various formats so that he can use the one that best suits his patient from the options provided. The file can usually be exported in Standard Triangle Language (STL) format, where the content of the plan is in the shape of a triangular mesh. Before being printed, the mesh needs to be sliced horizontally <sup>22,27,28</sup>.

Oral scanning is carried out by software that is also configured with ML and DL, which capture optical impressions and images of the patient. It works by emitting light on the objects to be captured virtually. The Virtuo Vivo™ intraoral scanner systems - Dental Wings, Primescan by Dentsply Sirona, 3Shape TRIOS®, are currently the most widely used because of their high functionality and image quality. When scanning, the DL variables establish occlusion by means of the Camper Plane, Spee Curve, Wilson Curve, Manson Curve, Compensation Curves and the patient's aesthetic references, such as gingival aspect for making the provisional protocol prosthesis (Figure 3). The file can usually be exported in STL format and can be integrated with image processing and planning software, such as BlueSky Plan, Exocad, etc., overlaying the projects to reduce errors in relation to the adaptation of the provisional prosthetic prototype to the other tissue structures <sup>22,27,28</sup>.



**Figure 3:**Facial and oral scanning. The data is entered into a software that enables occlusion management and prosthesis design.

After oral scanning, the patient's face is scanned. This allows for better projections to check that the shape of the teeth, mouth corridor, high smile line, midline, guide rails, such as the canine and incisal, and lip rhyme are harmonious with the other facial structures (Figure 4)<sup>22,27,28</sup>. The majority of facial scanners work by means of cameras that capture images using light emitted from the object to be superimposed on a three-dimensional plane. The light reflected from the object is captured by the software system in up to 0.4 seconds and sent to the program that will submit the data to analysis for treatment projections<sup>22</sup>.



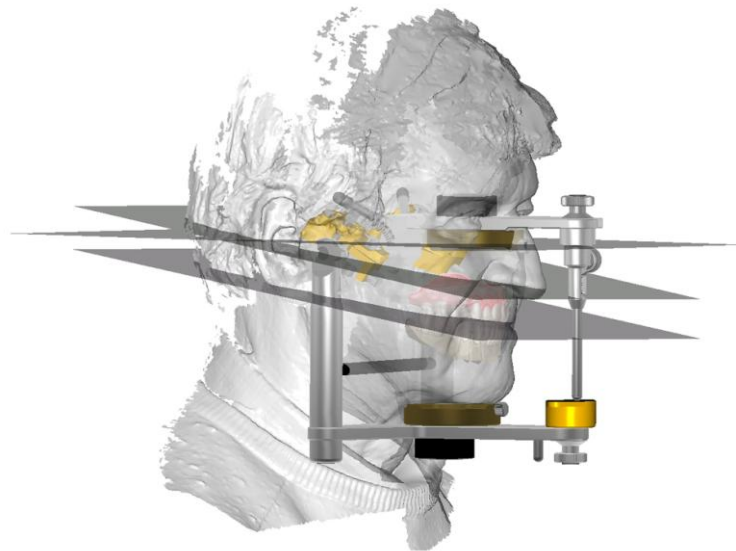
**Figure 4:** Oral scan combined with facial scan with the projections of provisional fixed prostheses on implants.

Nogueira (2023) determined in studies that the most commonly used facial scanners in Brazil today are the clOner Scanner (uses the photogrammetry described above) and the Bellus 3D (operates with cameras that support infrared to capture the points and 3D projection of the patient in 14 seconds). Both forms of facial scanning output STL files, OBJ (Object File Wavefront 3D) which has polygonal and triangular geometry, and PLY (Polygon File Format) which identifies transparency and can add color to the model.

Sartori and colleagues, in studies carried out in 2023, added that the files obtained from 3D scanners are placed in software such as BlueSky Plan, Exocad, Mesh Mixer etc., which uses AI to plan the temporary maxillary protocol prosthesis. The oral scan file (maxilla and mandible) is prepared and refined individually in the software to facilitate export. Once prepared, the files can follow the planning flow for choosing the teeth, their shape, the base of the protocol prosthesis, the shape of the gums, the height and width of the teeth and the occlusion. At this stage, it is important that the facial scan file is also coupled to the planning software. Once coupled, it is possible to check the patient's mouth corridor, high smile line, midline, Camper plane, Spee curve, Wilson curve, Manson curve, compensation curves and

with the  
virtual  
(Figure

aesthetic  
references  
aid of a  
articulator  
5).



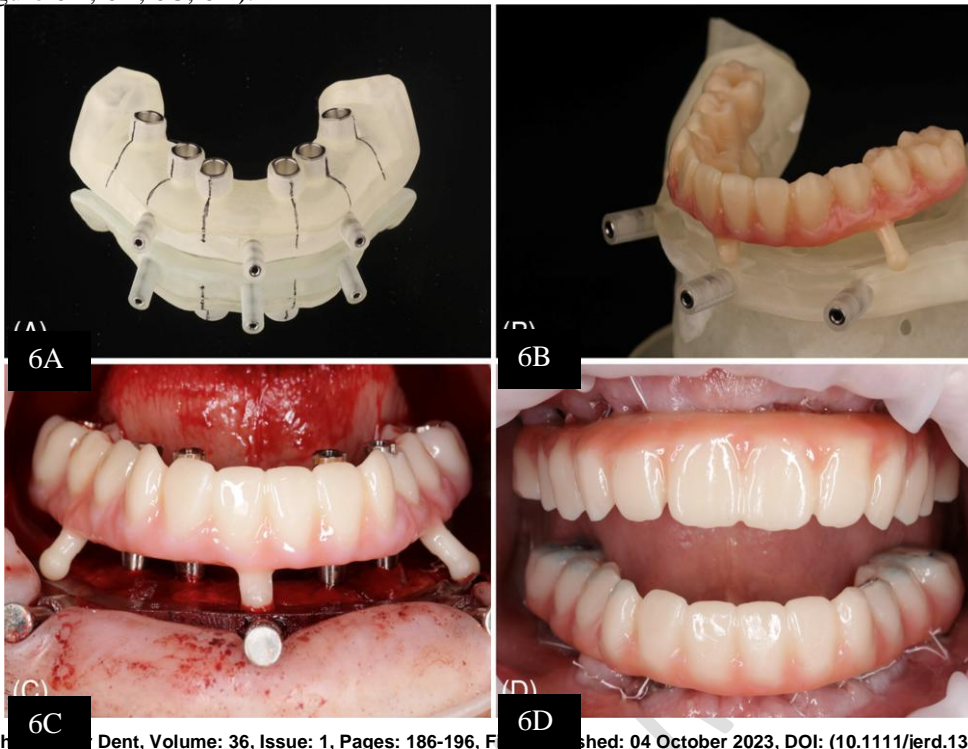
J Esthet Restor Dent, Volume: 36, Issue: 1, Pages: 174-185, First published: 03 March 2023, DOI: (10.1111/jerd.13031)

Figure 5: Planes and orientation in facial scanning combined with oral scanning.

Once the prosthetic planning has been completed, the CAD file will be exported for printing. Initially, the file goes through a horizontal slicing process that will allow the printer to read the G-Code file and print it in inkjet. The selected impression resin must have good dimensional stability, biocompatibility, less shrinkage during polymerization, greater precision and good mechanical strength. Once the provisional protocol prosthesis has been printed, it must be given ultraviolet light and finished <sup>24</sup>.

After curing, the temporary maxillary protocol prosthesis must obtain layers of paint for its anatomization. The paints are specific to 3D printer resins. After each pigmentation, it is necessary to photoactivate the paint, so that the coloring is fixed and can be captured in the

patient's mouth using provisional cylinders and self-curing acrylic resin or resin flow. After capture, it is necessary to achieve occlusion with carbon, in order to adapt the patient's occlusion (Figure 6A, 6B, 6C, 6D).



J Esth Dent, Volume: 36, Issue: 1, Pages: 186-196, Published: 04 October 2023, DOI: (10.1111/jerd.13142)

**Figure 6:** (A) surgical guide for implant placement; (B) Temporary prosthesis protocol printed and painted in similar colors to the patient's mucosa; (C) Temporary protocol prosthesis captured in the mandibular mouth; (D) Temporary maxillary protocol prostheses captured and installed in the patient's mouth.

Although AI brings benefits, as data is entered and processed, creating new arrangements, malicious virtual attacks are also enhanced by mutations within Artificial Intelligence. With this in mind, a study proposed by 500 professionals specializing in Large Language Models (LLMs) led to the creation of an OWASP (Open Web Application Security Project) Top 10 list that provides practical, applicable and summarized security guidelines to be implemented in patient and company data handling programs<sup>25,26</sup>.

While the list provides the most common malicious attacks and guides how each LLM professional should act to prevent and defend themselves, it leaves open that procedures should always be improved as LLMs (AI) are fed.

#### 4. CONCLUSION

In light of this, the use of digital mechanisms in dentistry has optimized the oral rehabilitation processes between the laboratory and the dental surgeon, as well as bringing comfort and improvements to patients' quality of life.

With the advancement of technologies, it is clear that Artificial Intelligence has come to integrate diagnosis with reference simulations that guide the placement of implants, aesthetic-functional formulations of prostheses for immediate loading, and decision-making in the patient's treatment plan.

Although it brings many benefits to the field of oral rehabilitation, the use of Artificial Intelligence technologies requires specialized manpower, financial investment and ethical conduct with regard to cybersecurity, because the more AI is fed, the more likely there are to be attacks with mutations and greater chances of stealing sensitive patient information.

In conclusion, the use of these technologies has emerged to complement the clinical experience with new methodologies that impact on the life of each patient and improve working relationships between the dental surgeon, laboratory and patient.

## REFERENCES

1. França SSM, Paraguassu EC. Immediate loading in implant-supported complete dentures: literature review. *Brazilian Journal of Implantology and Health Sciences*, v. 4, no. 1, p. 14-34, 2022.
2. Cunha JESM, De Sousa Júnior RT, & Ribeiro MIG. Immediate prosthesis on implants. *Electronic Magazine Acervo Saúde*, 23(5), e12755-e12755, 2023.
3. Cappare P, Sannino G, Minoli M, Montemezzi P, Ferrini F. Conventional versus Digital Impressions for Full Arch Screw-Retained Maxillary Rehabilitations: A Randomized Clinical Trial. *Int J Environ Res Public Health*. Mar 7;16(5):829, 2019.
4. Da Silva GP, De Macedo Cadidé TJ, De Oliveira IRD, & DA Costa Fonseca R. Total rehabilitation with osseointegrated implants: case report. *Revista Ciência e Saúde Online*, 4(3), 2019.
5. Sousa MDS. Artificial Intelligence in Oral Rehabilitation Digital smile planning. Master's Thesis, cespu repository. Link: < [https://repositorio.cespu.pt/bitstream/handle/20.500.11816/4314/MIMD\\_DISSE\\_RT\\_27663\\_MarianaSousa.pdf?sequence=1&isAllowed=y](https://repositorio.cespu.pt/bitstream/handle/20.500.11816/4314/MIMD_DISSE_RT_27663_MarianaSousa.pdf?sequence=1&isAllowed=y) >, May 2023.
6. Sartori EM, Weiss A, Arruda FJS, Stutz C, & De Mattias Sartori I. A. Maxillary Rehabilitation using Digital Flow – from planning to execution: Maxillary Rehabilitation using Digital Flow. *Brazilian Journal of Implantology and Health Sciences*, 5(5), 1977-1993, 2023.
7. Hiraiwa T, Aiji Y, Fukuda M, Kise Y, Nakata K, Katsumata A, Fujita H, Eichihiro A. A deep-learning artificial intelligence system for assessment of root morphology of the mandibular first molar on panoramic radiography. *Dentomaxillofac Radiol*. 48(3):20180218, 2019.
8. Nichols JA, Chan HWH, Baker MAB. Machine learning: applications of artificial intelligence to imaging and diagnosis. *Biophys Rev*. 11(1):111-08, 2019.

9. Jackson, P. C. Introduction to artificial intelligence. Courier Dover Publications, 2019.
10. Lee JH, Kim DH, Jeong SN, Choi SH. Detection and diagnosis of dental caries using a deep learning-based convolutional neural network algorithm. J Dent. 77:106-11, 2018.
11. Silva ABNS, Ribeiro LLDC, & Pessoa RS. E. Immediate implantation and immediate loading in the upper anterior area: a review of the literature. GeTeC Magazine, v. 12, no. 42, 2023.
12. Rosolen, T. Biomechanical study of implant-supported fixed prostheses in an edentulous mandible with posterior atrophy by varying the number, inclination and length of the implants and the extension of the cantilever. Link < [https://www.teses.usp.br/teses/disponiveis/58/58131/tde-06122022-120302/publico/ME\\_Thales\\_Rosolen\\_Corrigida.pdf](https://www.teses.usp.br/teses/disponiveis/58/58131/tde-06122022-120302/publico/ME_Thales_Rosolen_Corrigida.pdf) >. Doctoral dissertation, University of São Paulo, December 8, 2022.
13. Lopez CVM. PEEK on implants. Link < [https://repositorio.cespu.pt/bitstream/handle/20.500.11816/3733/MIMD\\_DISSE\\_RT\\_24890\\_V%c3%adctorL%c3%b3pez.pdf?sequence=1&isAllowed=y](https://repositorio.cespu.pt/bitstream/handle/20.500.11816/3733/MIMD_DISSE_RT_24890_V%c3%adctorL%c3%b3pez.pdf?sequence=1&isAllowed=y) >. Master's Thesis, July 27, 2021.
14. Marson G, De Sá BDL, De Farias GB. Rehabilitation of edentulous and atrophic maxilla without bone graft: Applicability of the all-on-4 technique. Brazilian Journal of Implantology and Health Sciences, v. 5, no. 5, p. 1197-1207, 2023.
15. Miranda Júnior JN, Paim RC. Relevant aspects about the applicability of immediate loading in implantodontics. JNT- Facit Business and Technology Journal. Ed. 39. Vol. 2. Pages. 293-304. ISSN: 2526-4281. October 2022.
16. De Vargas KF, Gertz LC, Rodrigues AFA, & Ozkomur A. Comparison of All-On-Four® and Four-On-Pillars techniques in rehabilitation of atrophic edentulous maxilla: 2D finite element analysis. Dialética Publisher. 2022.
17. Mintz Y, Brodie R. Introduction to artificial intelligence in medicine. Minimally Invasive Therapy & Allied Technologies, v. 28, no. 2, p. 73-81, 2019.
18. Ahmed N, Abbasi MS, Zuberi Fet al. Artificial Intelligence Techniques: Analysis, Application, and Outcome in Dentistry - A Systematic Review. Biomed Res Int. 2021.

19. Alshadidi AAF, Alshahrani AA, Aldosari LIN, Chaturvedi S, Saini RS, Hassan SAB, Ciccì M, & Minervini G. Investigation on the Application of Artificial Intelligence in Prosthodontics. *Applied Sciences*, vol. 13, no. 8, p. 5004, 2023.
20. Schwendicke F, Golla T, Dreher M, & Krois J. Convolutional neural networks for dental image diagnostics: A scoping review. *Journal of dentistry*, 91, 103226, 2019.
21. Huang C, Wang J, Wang S, & Zhang Y. A review of deep learning in dentistry. *Neurocomputing*, 126629, 2023.
22. Haidar ZS. Digital Dentistry: Past, Present, and Future. *Digital Medicine and Healthcare Technology*, 2023.
23. Nogueira BR. Extraoral scanning for facial analysis in dentistry. Doctoral Thesis, São Paulo State University (UNESP). Araraquara, 80 p. 2023.
24. Silva AMVPR Da. 3D printing processing of mandibular complete dentures. Master's Thesis, University of Coimbra, 2020.
25. Marchand-Melsom Alexander, Nguyen Mai Duong Bao. Automatic repair of OWASP Top 10 security vulnerabilities: A survey. In: *Proceedings of the IEEE/ACM 42nd International Conference on Software Engineering Workshops*. 2020. p. 23-30.
26. Silva FM, Barbosa MA, Neto NP, Fernandes NP, Santos N, De Jesus Gonçalves JV, & Lima NJLL. Oral rehabilitation of edentulous patient with protocol-type implant-supported fixed prosthesis: an integrative review. *Research, Society and Development*, 12(3), e24512340803-e24512340803, 2023.
27. Li J, Joda T, Revilla-León M, Saleh MH, Chen Z, & Wang HL. Recommendations for successful virtual patient-assisted esthetic implant rehabilitation: A guide for optimal function and clinical efficiency. *Journal of Esthetic and Restorative Dentistry*, 36(1), 186-196. 2024.
28. Edelhoff D, Schubert O, Stimmelmayer M, & Schweiger J. CAD/CAM full-mouth rehabilitation of an elderly patient: One-piece digital complete denture meets multilayered zirconia with gradient technology. *Journal of Esthetic and Restorative Dentistry*, 36(1), 174-185. 2024.