

What if drusen were not exclusive to the elderly? A case report and literature review

Comment [MS1]: Check spelling

Abstract

The different appearances of drusen in young subjects could be explained by a different structure and origin. These conditions are closely related to AMD, but their relationship has not been clearly established.

Keywords : epithelium, levothyroxine, maculardrusen, anterior segment

Comment [MS2]: Why is this keyword added? Is the drug suspected in causing Drusen?

Introduction

Drusen are small, yellowish-white deposits visible at the back of the eye. Predominantly lipid-based, they are extracellular deposits accumulated between the pigment epithelium and the collagen layer of the bruchial membrane. They usually appear after the age of 50 and represent the early stages of age-related macular degeneration (AMD) or age-related maculopathy. In some cases, drusen may be present before the age of 50. We report the case of a 32-year-old woman, radiology technician, thyroidectomized on levothyroxine, anemic on iron supplementation. There was a family history of AMD (maternal grandmother). Routine examination revealed preserved visual acuity of 10/10 ODG, emmetropia, no particularities on examination of the anterior segment, and an incidental finding of diffuse macular drusen on the fundus. Colloid drusen are large and diffuse, with no known specific genetic mutation. They are preferentially temporo-macular, with a hyporeflective center that is discreetly hyperautofluorescent (AF).

Comment [MS3]: Please check spelling

Material and methods

Comment [MS4]: Use subheading - case summary
Please give statement of ethics and mention patient consent

We report the case of a 32-year-old woman, radiology technician, thyroidectomized on levothyroxine, anemic on iron supplementation. There was a family history of AMD (maternal grandmother). Routine examination revealed preserved visual acuity of 10/10 ODG, emmetropia, no particularities on examination of the anterior segment, and an incidental finding of diffuse macular drusen on the fundus.

Comment [MS5]: Repetitive

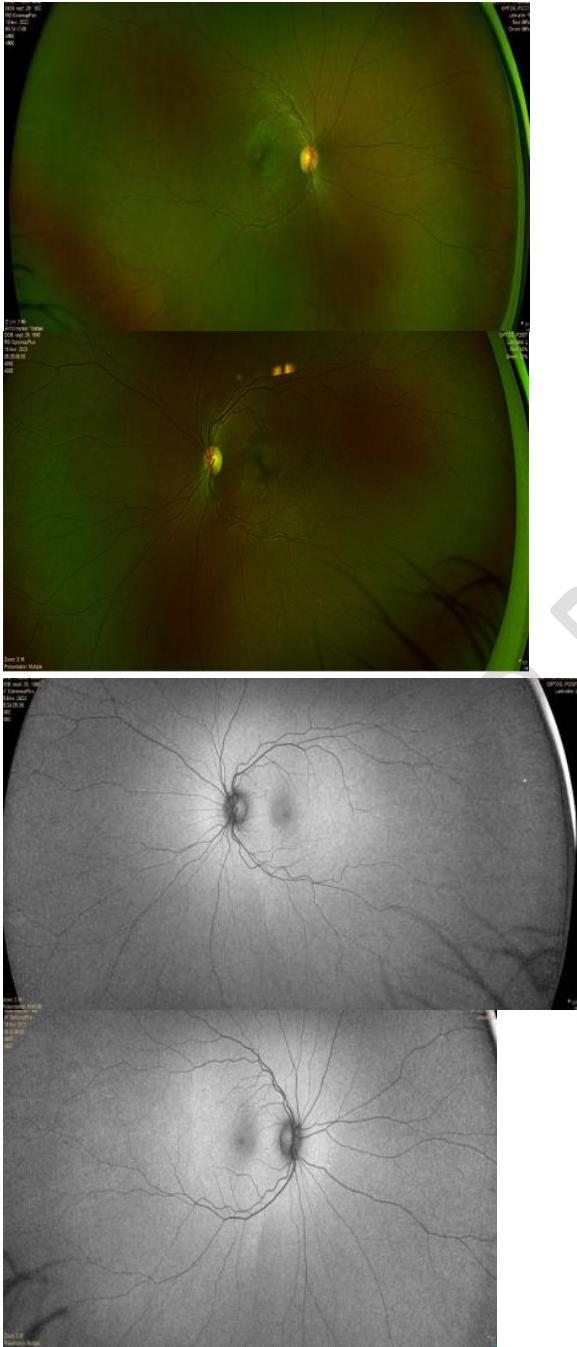

Figure 1 : funduscopical and autofluorescence aspect of colloid drusen

Comment [MS6]: Please explain the findings

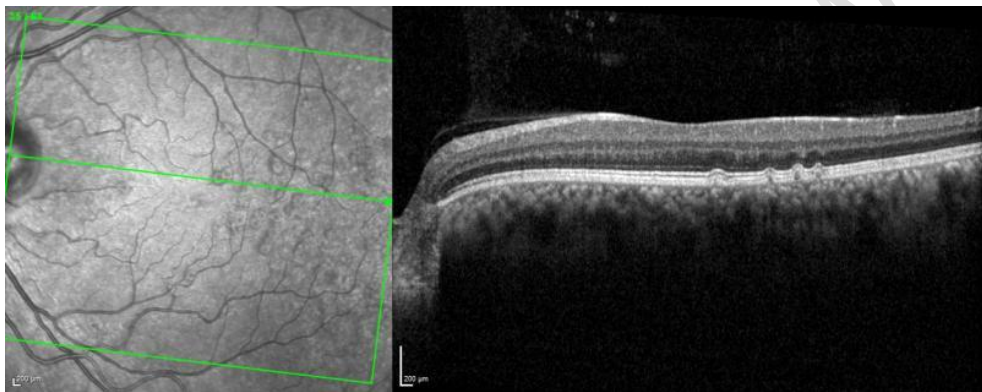
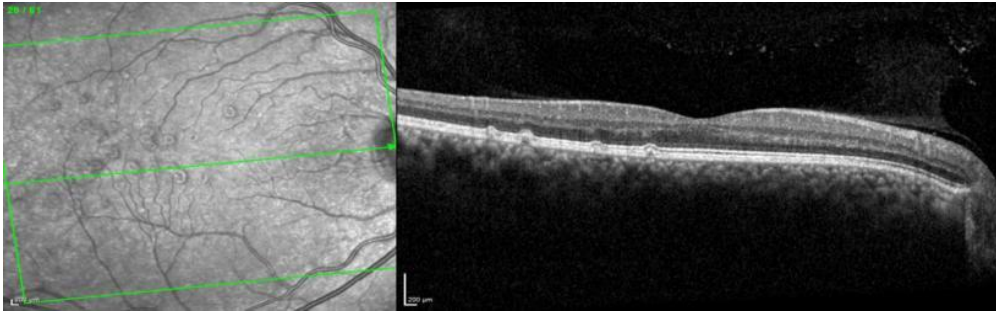


Figure 2 : oct aspect and « donut aspect » of colloid drusen

Results

An ophthalmological workup was performed. Our attitude consisted in a therapeutic abstention given the normality of the examination and the absence of complications with monitoring.

Discussion

Drusen in the young subject mainly include: cuticular drusen, dominant drusen and colloid drusen.

A prospective descriptive study including 39 patients (27 women and 12 men) was carried out at the Créteil Hospital in France . The aim of the study was to analyze the angiographic and optical coherence tomography (OCT) features of drusen in subjects under 50 years of age. All patients underwent a complete ophthalmological work-up with fluorescein (AgF) and indocyanine green (ICG) angiography and OCT (1). The mean age of the patients was 44 years. 27 patients had cuticular drusen, 5 patients had dominant drusen and 7 patients had juvenile colloid drusen.

Colloid drusen are large and diffuse, with no known specific genetic mutation. They are preferentially temporo-macular, with a hyporeflective center that is discreetly hyperautofluorescent (AF). They are hypo- then hyper-fluorescent on fluorescein angiography, and their "donut" appearance on ICG is original. They are generally benign, but rare cases of atrophy, choroidal neovessels and chronic polypoidal vasculopathy have been described.

Cuticular drusen are fine, punctate and diffuse, often associated with an accumulation of vitelline material. The AgF appearance is typical, showing early starry-sky hyperfluorescence. On oct (optical coherence tomography), a sawtooth-like appearance is found. It is a borderline form of AMD, occurring at a younger age, with a stronger genetic component(2).

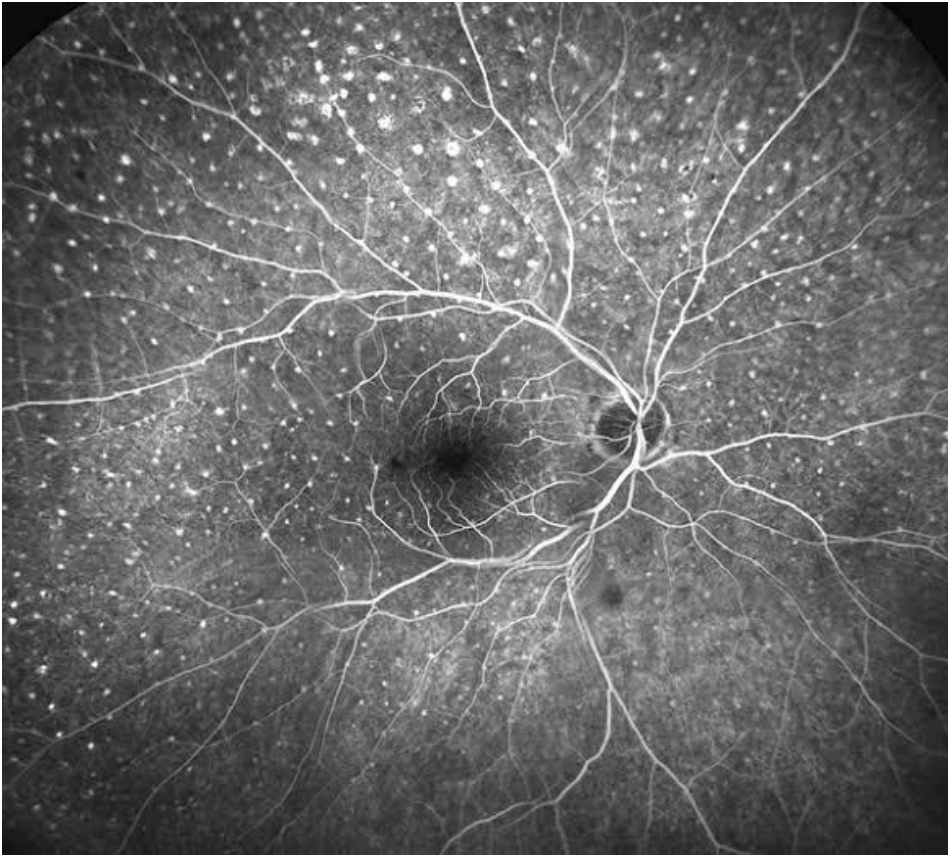


Figure 3 : On fluorescein angiography, cuticular drusen appear as a large group of small hyperfluorescent lesions scattered throughout the fundus, resulting in the “stars-in-the-sky” pattern that is characteristic of these drusen

Doyne Honeycomb retinal dystrophy or Malattia Leventinese is a monogenic dystrophy with autosomal dominant inheritance (EFEMP1 mutation), resulting in a pathological fibulin 3 protein that induces local thickening of the bruchial membrane(3). These drusen are organized in honeycomb lines radiating from the center, with a macular and peripapillary arrangement. They are hyperautofluorescent and hyperfluorescent at late times on AgF and ICG. They may become confluent and evolve into a central fibrous plaque(4). Another study reports that patients with DSJ show a decrease in macular sensitivity compared with healthy controls, assessed by microperimetry, with preservation of visual acuity. Focal loss of sensitivity correlated with structural abnormalities demonstrated on SD-OCT. Currently, there are no genetic or targeted therapies to correct the underlying EFEMP1 genetic mutation in DHRD. As a rule, patients are managed conservatively with observation, unless choroidal neovascularization develops. In this case, anti-VEGF injections such as bevacizumab have been shown to improve vision and resolve subretinal fluid. Another treatment

option is the use of lasers to eliminate the sub-retinal fluid. One study showed that low-energy argon laser treatment improved visual acuity and retinal sensitivity, and reduced drusen volume(5).

Conclusion

The different appearances of drusen in young subjects could be explained by a different structure and origin. These conditions are closely related to AMD, but their relationship has not been clearly established. Further work is needed to investigate the relationship between these different conditions. In all cases, the fundus of these patients should be regularly monitored for complications, in particular the appearance of choroidal neovessels.

Références

1 Benjamin Guigui, Nicolas Leveziel, Virginie Martinet, Nathalie Massamba, Margaret Sterkers, et al..

Angiography features of early onset drusen. *British Journal of Ophthalmology*, 2010, 95 (2), pp.238.

ff10.1136/bjo.2009.178400ff.

2 Camiel J.F. Boon , Johannes P.H. van de Ven , Carel B. Hoyng , Anneke I. den Hollander a, B. Jeroen Klevering .Cuticular drusen: Stars in the sky. *Progress in Retinal and Eye Research* ,Volume 37, November 2013, Pages 90-113

3 Stone, Edwin M., et al. "A single EFEMP1 mutation associated with both Malattia Leventinese and Doyme honeycomb retinal dystrophy." *Nature genetics* 22.2 (1999): 199-202.

4 Sohn, Elliott H., et al. "Responsiveness of Choroidal Neovascular Membranes in Patients With R345W Mutation in Fibulin 3 (Doyme Honeycomb Retinal Dystrophy) to Anti-Vascular Endothelial Growth Factor Therapy." *Archives of ophthalmology* 129.12 (2011): 1626-1628.

5 Cusumano A, Falsini B, Giardina E, Cascella R, Sebastiani J, Marshall J. Doyme honeycomb retinal dystrophy - functional improvement following subthreshold nanopulse laser treatment: a case report. *J Med Case Rep.* 2019 Jan 10;13(1):5.