

Simultaneous Discovery of Gallbladder Adenocarcinoma During Hepatic Hydatid Cyst Management: A Rare Clinical Case with Complex Implications

ABSTRACT

Hepatic hydatid cysts, rare but complex, present significant challenges in clinical management. In this case study, a 57-year-old patient with persistent pain in the right hypochondrium and bilious vomiting was diagnosed with gallbladder adenocarcinoma. The initial management of the cyst revealed the presence of gallbladder adenocarcinoma, which raised important diagnostic and therapeutic considerations. The coexistence of a hydatid cyst and gallbladder adenocarcinoma presents a complex scenario that requires a comprehensive understanding of both echinococcosis and gallbladder cancer. Possible underlying mechanisms for the coexistence of gallbladder adenocarcinoma include chronic inflammation and irritation to the gallbladder. The presence of a metastatic lymph node at the neck of the gallbladder and involved tumor margins added complexity to the case. The diagnosis of a hydatid cyst and gallbladder adenocarcinoma in the same patient presents unique challenges, as the symptoms and imaging findings could be attributed to either condition individually. Accurate diagnosis relies on a combination of imaging techniques, serological tests, and histopathological analysis. Collaborative efforts among medical professionals and institutions can contribute to the accumulation of more cases and the development of evidence-based guidelines for diagnosis and management. Further research is needed to better understand the underlying mechanisms, risk factors, and clinical implications of this rare association.

Keywords: *hydatid cyst, gallbladder adenocarcinoma, complex implication*

1. INTRODUCTION

Hepatic hydatid cysts, though rare, present intricate challenges in clinical management. This case study highlights an extraordinary instance where the initial management of a hepatic hydatid cyst incidentally unveiled the presence of gallbladder adenocarcinoma in our patient [6-10]. This rare coexistence of pathologies raises important diagnostic and therapeutic considerations.

2. CASE PRESENTATION

A 57-year-old individual with no significant medical history sought medical attention for persistent pain in the right hypochondrium and bilious vomiting, without fever or signs of systemic illness, persisting for a month. Upon examination, tenderness in the right hypochondrium was noted, prompting further investigation. The abdominal ultrasound revealed a hydatid cyst at the hilum associated with acute lithiasic cholecystitis.

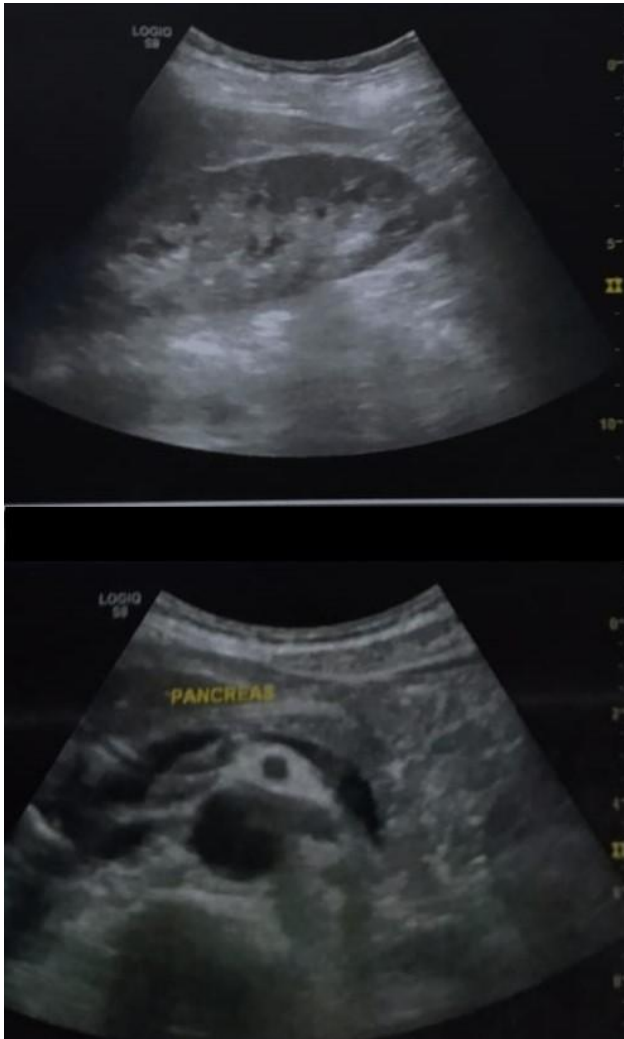

Fig. 1 Abdominal ultrasound images showing...

Complementary scanning showed a non-distended, multilithiasic gallbladder with dilation of the main bile duct and signs of cholangitis. Coeliomesenteric and right iliac lymph nodes and adenomegalies, some necrotic, were observed.

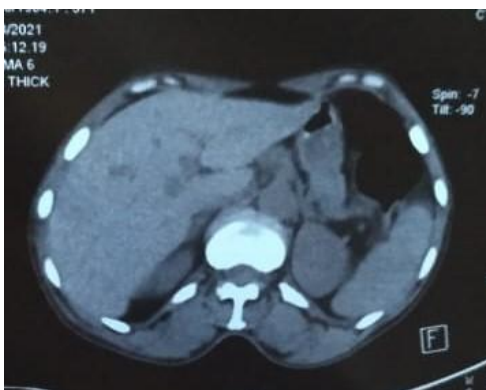

Fig. 2 CT scan images of the liver...

Biological analyses showed a positive serology for echinococcosis. Subsequent subcostal surgery revealed a markedly thickened gallbladder wall with calculi, displaced by a hydatid cyst from segment V, exerting pressure on the main

bile duct. Notably, no other hepatic lesions were identified, and there was no significant effusion.

The surgical team performed anterograde cholecystectomy, resected the prominent dome of the hydatid cyst, and placed a trans-cystic drain. Histopathological analysis confirmed a well-differentiated adenocarcinoma of the gallbladder infiltrating the perimuscular tissue with serosal perforation. Furthermore, a metastatic lymph node at the neck of the gallbladder and involved tumor margins added complexity to the case.

Staging assessment revealed multiple brain bone lesions. The patient was referred to the medical oncology department to start her chemotherapy.

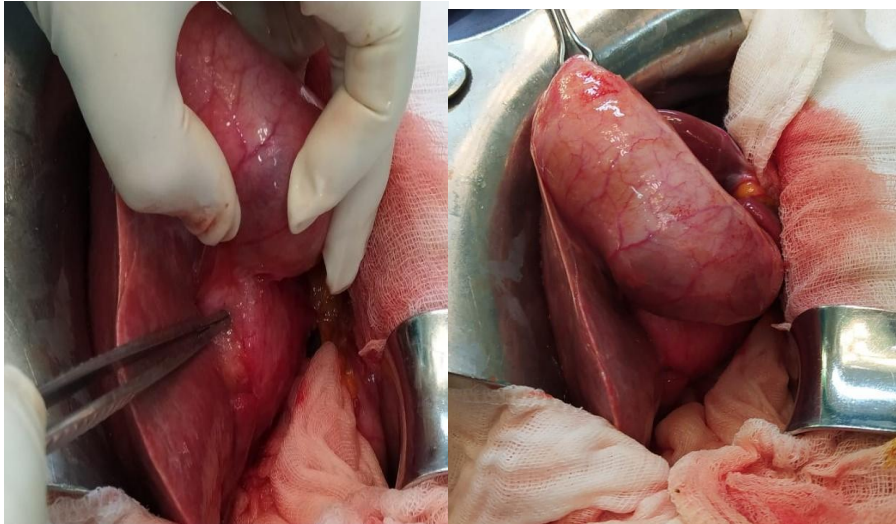


Fig. 3a&b Intraoperative images

DISCUSSION

The unique coexistence of hepatic hydatid cyst and gallbladder adenocarcinoma in our patient presents a complex scenario that requires a comprehensive understanding of both echinococcosis and gallbladder cancer. The infrequent association between these conditions raises important diagnostic and therapeutic considerations, emphasizing the need for a multidisciplinary approach.

Studies such as those by De Rosa et al. (2016) and Grosso et al. (2012) have highlighted the challenges in diagnosing and managing hepatic hydatid cysts [1,2]. These challenges are compounded when additional pathologies, such as gallbladder adenocarcinoma, are incidentally discovered during the management of the primary condition. The significance of these findings is underscored by the work of Hundal and Shaffer (2014), which emphasizes the complex epidemiology and outcomes of gallbladder cancer, particularly in cases with concurrent pathologies[3,4].

The case presented above is an intriguing and rare occurrence of a patient with both a hydatid cyst and gallbladder adenocarcinoma. This unique combination poses several challenges in terms of diagnosis, management, and treatment. In this discussion, we will explore the possible underlying mechanisms, the diagnostic difficulties, and the treatment implications for such cases.

3.1. Possible Underlying Mechanisms: The coexistence of a hydatid cyst and gallbladder adenocarcinoma raises questions about the potential relationship between these two conditions. While the exact underlying mechanisms remain unclear, several hypotheses can be considered. One possibility is that the hydatid cyst, acting as a space-occupying lesion, may have caused chronic inflammation and irritation to the gallbladder. This chronic inflammation could have predisposed the

gallbladder to the development of adenocarcinoma. Alternatively, it is possible that the presence of the hydatid cyst in the gallbladder may have triggered an immune response, leading to the development of adenocarcinoma. Further research is needed to explore these potential associations and shed light on the underlying mechanisms.

3.2. Diagnostic Challenges:

The diagnosis of a hydatid cyst and gallbladder adenocarcinoma in the same patient presents unique challenges. The initial presentation of right hypochondrial pain and bilious vomiting mimicked typical cholecystitis, leading to investigations that revealed the unexpected presence of a hydatid cyst. This highlights the importance of considering differential diagnoses and maintaining a high index of suspicion for uncommon presentations. The coexistence of the hydatid cyst and gallbladder adenocarcinoma further complicated the diagnostic process, as the symptoms and imaging findings could be attributed to either condition individually. Accurate diagnosis relied on a combination of imaging techniques, serological tests, and histopathological analysis. This case emphasizes the need for a comprehensive and multidisciplinary approach to reach an accurate diagnosis in complex cases.

3.3. Treatment Implications:

The management and treatment of simultaneous hydatid cyst and gallbladder adenocarcinoma require careful consideration of the individual characteristics of each condition. In this case, the surgical team performed an anterograde cholecystectomy and resected the prominent dome of the hydatid cyst. The presence of adenocarcinoma with lymph node involvement and metastatic lesions necessitated referral to the medical oncology department for chemotherapy. This highlights the importance of a multidisciplinary approach to develop an optimal treatment plan for such complex cases. Additionally, close monitoring and regular follow-up are essential to assess treatment response, manage potential complications, and ensure the overall well-being of the patient[5].

3.4. Future Directions:

This rare case raises several questions and highlights the need for further research. Understanding the underlying mechanisms of the coexistence of a hydatid cyst and gallbladder adenocarcinoma could provide insights into potential preventive measures and targeted treatment options. Additionally, investigating the epidemiological and clinical characteristics of similar cases can contribute to the development of evidence-based guidelines for diagnosis and management. Collaboration between different medical specialties and the sharing of experiences and findings will be crucial in advancing our understanding of this rare combination of conditions.

3. CONCLUSION

The simultaneous presence of a hydatid cyst and gallbladder adenocarcinoma is a complex and challenging scenario. Accurate diagnosis and optimal treatment require a comprehensive and multidisciplinary approach. This case report highlights the importance of considering rare differential diagnoses and the need for further research to elucidate the underlying mechanisms and improve patient management. Continuous advancements in medical knowledge and collaboration between different specialties will contribute to better outcomes for patients with similar presentations in the future.

Given the scarcity of reported cases and the limited available literature, further research is needed to better understand the underlying mechanisms, risk factors, and

clinical implications of this rare association. Collaborative efforts among medical professionals and institutions can contribute to the accumulation of more cases and the development of evidence-based guidelines for diagnosis and management.

CONSENT

As per international standards or university standards, patient(s) written consent has been collected and preserved by the author(s).

ETHICAL APPROVAL

As per international standard or university standards written ethical approval has been collected and preserved by the author(s).

REFERENCES

1. De Rosa D, Grosso G, Brancato G, et al. Hydatid cyst of the liver: A case report and literature review. *Int J Surg Case Rep.* 2016;25:109-112. doi:10.1016/j.ijscr.2016.06.031
2. Grosso G, Gruttadauria S, Biondi A, et al. Worldwide epidemiology of liver hydatidosis including the Mediterranean area. *World J Gastroenterol.* 2012;18(13):1425-1437. doi:10.3748/wjg.v18.i13.1425
3. Brunetti E, Kern P, Vuitton DA; Writing Panel for the WHO-IWGE. Expert consensus for the diagnosis and treatment of cystic and alveolar echinococcosis in humans. *Acta Trop.* 2010;114(1):1-16. doi:10.1016/j.actatropica.2009.11.001
4. Hundal R, Shaffer EA. Gallbladder cancer: epidemiology and outcome. *Clin Epidemiol.* 2014;6:99-109. doi:10.2147/CLEP.S37357
5. Shindoh J, de Aretxabala X, Aloia TA, et al. Tumor location is a strong predictor of tumor progression and survival in T2 gallbladder cancer: An international multicenter study. *Ann Surg.* 2014;259(4):733-739. doi:10.1097/SLA.0000000000000315
6. Young RH, Scully RE. Ovarian metastases from carcinoma of the gallbladder and extrahepatic bile ducts simulating primary tumors of the ovary: a report of six cases. *International journal of gynecological pathology.* 1990 Jan 1;9(1):60-72.
7. Wakai T, Shirai Y, Hatakeyama K. Radical second resection provides survival benefit for patients with T2 gallbladder carcinoma first discovered after laparoscopic cholecystectomy. *World journal of surgery.* 2002 Jul 1;26(7):867.
8. Tian YH, Ji X, Liu B, Yang GY, Meng XF, Xia HT, Wang J, Huang ZQ, Dong JH. Surgical treatment of incidental gallbladder cancer discovered during or following laparoscopic cholecystectomy. *World journal of surgery.* 2015 Mar;39:746-52.
9. Yeh CN, Jan YY, Chen MF. Management of unsuspected gallbladder carcinoma discovered during or following laparoscopic cholecystectomy. *The American Surgeon.* 2004 Mar;70(3):256-8.
10. Okumura K, Gogna S, Gachabayov M, Felsenreich DM, McGuirk M, Rojas A, Quintero L, Seshadri R, Gu K, Da Dong X.

Gallbladder cancer: Historical treatment and new management options. World Journal of Gastrointestinal Oncology. 2021 Oct 10;13(10):1317.

UNDER PEER REVIEW