

OUTCOMES OF SURGICAL THROMBECTOMY FOR ILIO-FEMORAL DEEP VEIN THROMBOSIS IN HOSPITALS IN RIVERS STATE

ABSTRACT

Background:In patients presenting with Deep Vein Thrombosis (DVT) involving the ilio-femoral veins, pulmonary embolism and post-thrombotic syndrome are major concerns. Intervening early by removing the venous thrombus significantly reduces the burden of DVT.

Objective:To assess recanalization, post-procedure development of pulmonary embolism (PE) and or post thrombotic syndrome (PTS) following surgical thrombectomy for ilio-femoral DVT.

Materials and Methods:

This is a descriptive cross-sectional study that was conducted at a public and five private healthcare facilities in Port Harcourt with data prospectively collected from March 1, 2018, to February 29, 2024 that evaluated the outcomes of surgical thrombectomy for DVT involving the ilio-femoral veins. Those with strictly below knee (popliteal vein) DVT were excluded from the study, as they were treated mainly by non-surgical means. A pre-designed semi-structured questionnaire was used to obtain variables which included patients' demography, veins involved, type of DVT, surgical approach, type of anesthesia and outcome. Results are presented as frequencies, tables, and figures. The statistical level of significance was set as p value of ≤ 0.05 .

Results:

The study involved 19 patients who had surgical thrombectomy during the period under review. There were 12 (63.16%) males and 7 (36.84%) female patients. The age range was 22-78 years. Of these, 8 (42.10%) patients had femoral or ilio-femoral DVT alone, while 11 (57.90%) patients had calf vein DVT in addition to femoral or ilio-femoral DVT. 16 patients had acute DVT and 3 patients presented with acute-on-chronic DVT. Surgical thrombectomy was done with the aid of Fogarty catheters in all cases. All the patients had combined epidural and spinal anesthesia. Recanalization was achieved in all 19 cases, no clinical PE was detected peri-operatively, however, the patients with acute on chronic DVT had significant PTS.

Conclusion:

The safety profile and recanalization rate following surgical thrombectomy for ilio-femoral DVT is very good especially when done at the acute phase of the DVT. This also significantly prevents the occurrence of post thrombotic syndrome.

KEY WORDS:Ilio-femoral Deep Vein Thrombosis, Post Thrombotic Syndrome, Pulmonary Embolism, Recanalization, Surgical thrombectomy.

1. INTRODUCTION

In patients presenting with Deep Vein Thrombosis (DVT) involving the ilio-femoral veins, pulmonary embolism and post-thrombotic syndrome are major concerns. Intervening early by

removing the venous thrombus significantly reduces the burden of DVT [1]. Based on a consensus statement derived from expert opinion and available evidence, endovascular thrombus removal for ilio-femoral DVT was recommended [2], because it achieved a significant improvement in venous patency in ilio-femoral DVT cases [3-8].

Surgical thrombectomy demonstrated favourable outcomes in patients with acute iliofemoral DVT and acute-on-chronic DVT, with predictors of success identified [9], and reduction in the risk of post-thrombotic syndrome [6]. Studies found a declining trend in PE mortality rates from 1999 to 2014. Surgical thrombectomy for ilio-femoral DVT was not specifically addressed, but a reduction in PE-related mortality indirectly suggests improved outcomes from interventions targeting ilio-femoral DVT [10-12].

In our environment, there is paucity of data on the outcome of surgical thrombectomy for ilio-femoral DVT. Hence, the study sought to evaluate recanalization, post-procedure development of pulmonary embolism (PE) and or post thrombotic syndrome (PTS) following surgical thrombectomy for iliofemoral DVT in healthcare facilities in Rivers State, Nigeria.

2. MATERIALS AND METHODS

2.1 Study site: The study was conducted at the University of Port Harcourt Teaching Hospital, Sterling Specialist Hospital, Princess Medical Centre, Lifeforte Specialist Hospital, Raziela Specialist Clinic and Palmars Hospital among patients presenting with ilio-femoral DVT.

2.2. Method: This is a descriptive cross-sectional study involving 19 patients who were managed by the same surgeon in healthcare facilities in Port Harcourt with data prospectively collected from March 1, 2018, to February 29, 2024, for ilio-femoral DVT using the purpose sampling technique. The exclusion criteria were patients with strictly below knee (popliteal vein) DVT as they were treated mainly using non- surgical methods. A specifically designed semi- structured interviewer-administered questionnaire was used to obtain patients' demography, veins involved, type of DVT, surgical approach, type of anesthesia and outcome. The patients had post-operative anticoagulation and have been followed up for a period of one month to six years.

3. RESULTS

The study involved 19 patients who had surgical thrombectomy during the period under review. There were 12 (63.16%) males and 7 (36.84%) female patients. The age range was 22-78 years. Of these, 8 (42.10%) patients had femoral or ilio-femoral DVT alone, while 11 (57.90%) patients had calf vein DVT in addition to femoral or ilio-femoral DVT. 16 patients had acute DVT and 3 patients presented with acute-on-chronic DVT. Surgical thrombectomy was done with the aid of Fogarty catheters in all cases. All the patients had combined epidural and spinal anesthesia. The patients were all anticoagulated from first day post-surgery to between three to six months. Recanalization was achieved in all 19 cases as shown by post procedure duplex venous scan. No clinical PE was detected peri-operatively, however, the patients with acute on chronic DVT had significant PTS as shown by recurrent lower limb swelling, heaviness and pain.

The age distribution shows that more (31.5%) were within the ages of 40-49 years, followed by those aged 30-39 years and 60-69 years (21.1%) each. This is shown in Table 1.

Table 1: Age distribution of Respondents

Age in years	Frequency	Percentage
20-29 years	1	5.3
30-39 years	4	21.1
40-49 years	6	31.5
50-59 years	2	10.5
60-69 years	4	21.1
70-79 years	2	10.5
Total	19	100.0

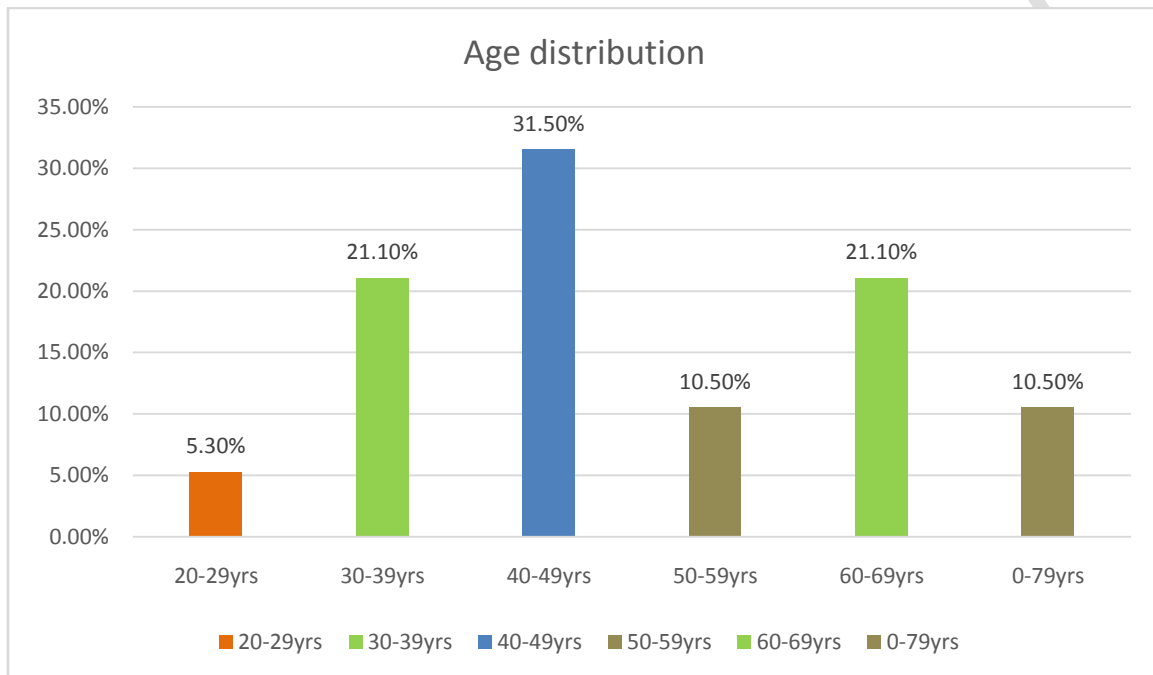


Fig 1: Bar chart showing percentage distribution of the age of participants.

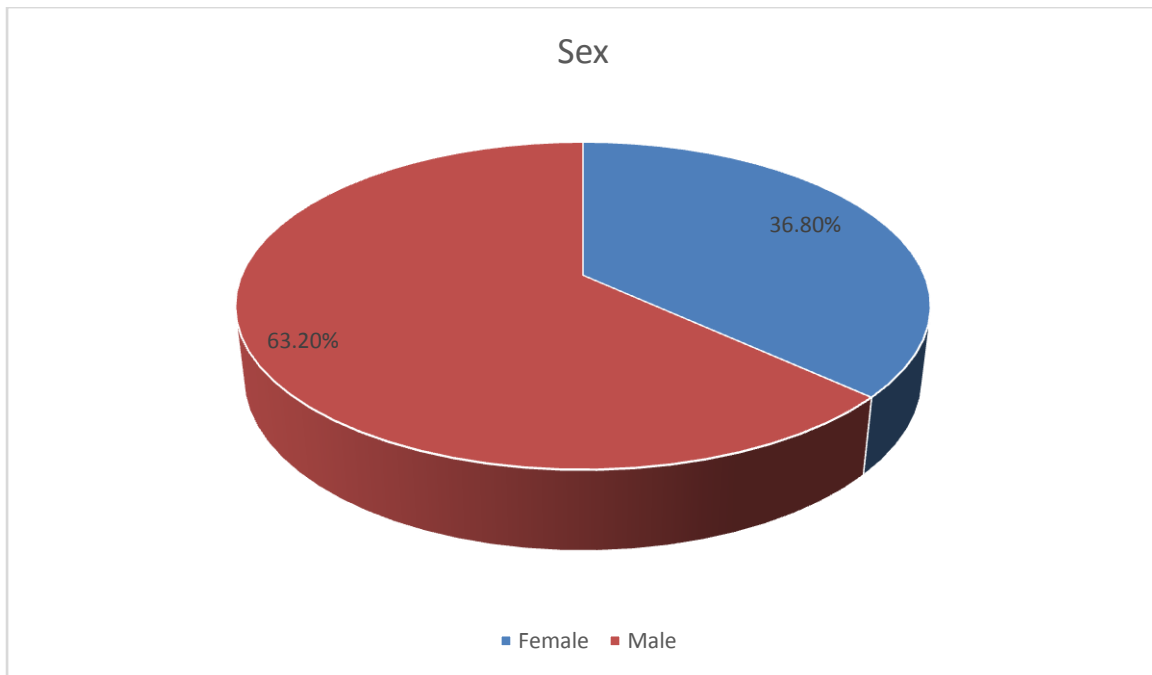


Fig 2: Pie chart showing percentage distribution of the sex of participants

Fig 2 shows the sex distribution of the participants. The result shows that more (63.2%) were males while 36.8% were females.

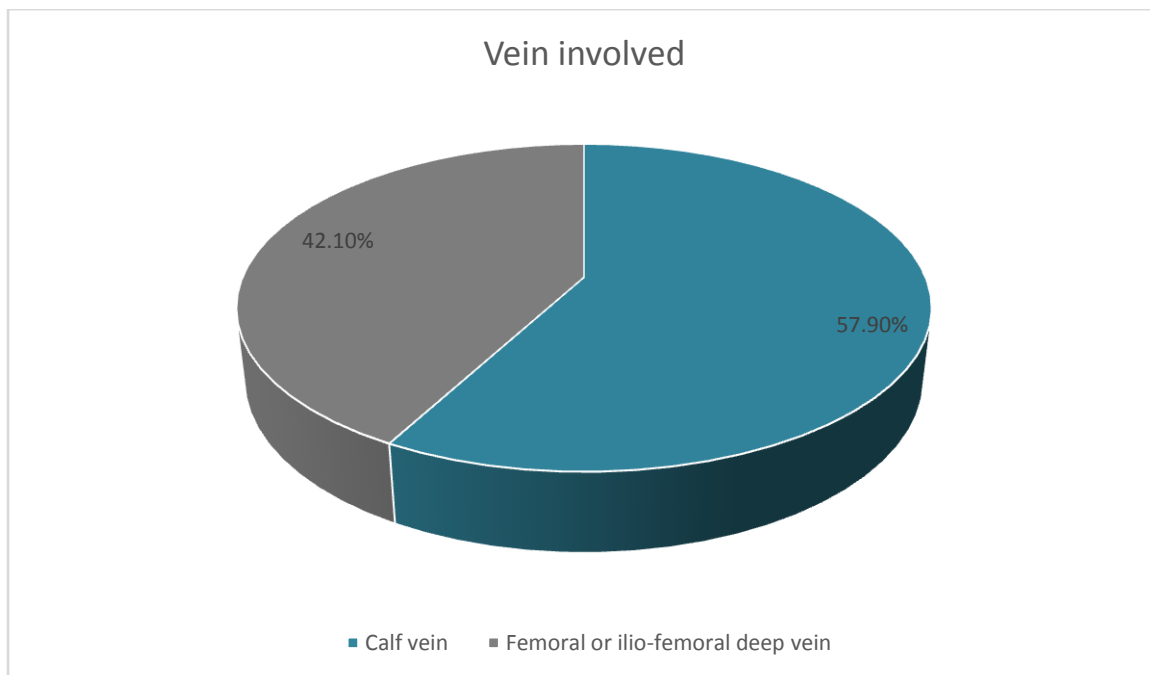


Fig 3: Pie chart showing the vein involved.

Fig 3 shows the types of vein involved in the procedure. The result shows that 57.9% patients had calf vein DVT in addition to femoral or ilio-femoral DVT while 42.1% patients had femoral or ilio-femoral DVT alone.

Table 2 shows the types of DVT. The result shows that majority (84.2%) had acute DVT while about a quarter (15.4%) of the patients had acute-on-chronic DVT.

Table 2: Percentage distribution showing type of DVT

Type of DVT	Frequency	Percentage
Acute DVT	16	84.2
Acute-on-chronic DVT	3	15.8
Total	19	100.0

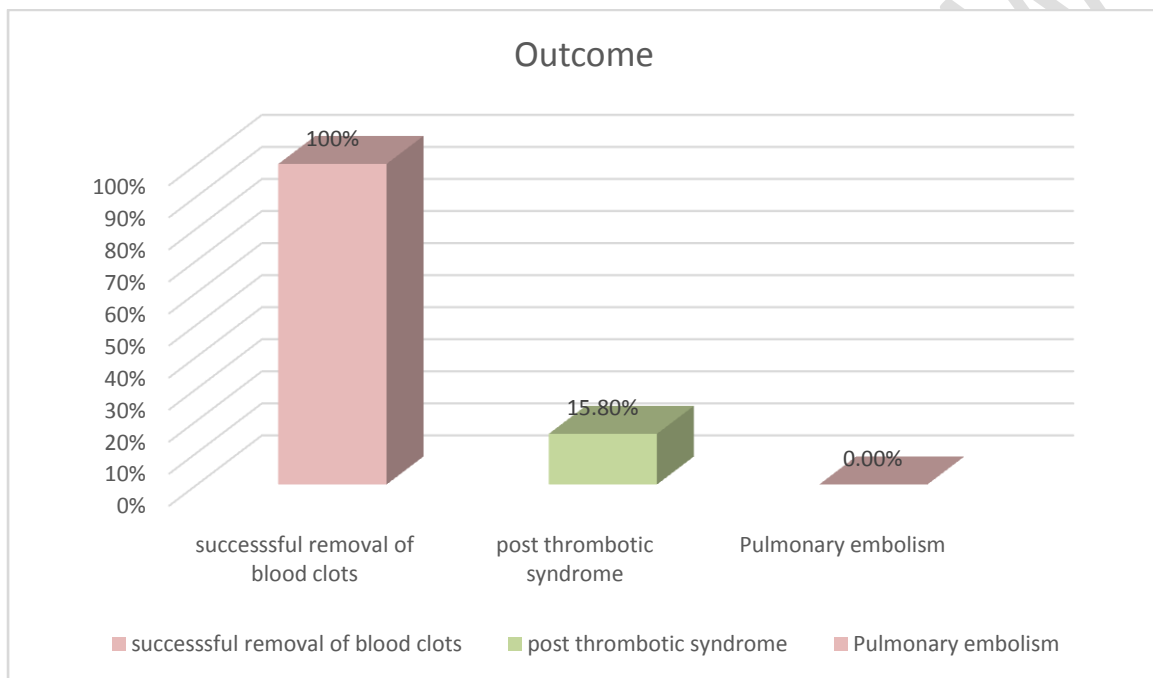


Fig 4: Bar chart showing the outcome of surgical thrombectomy for ilio-femoral deep vein thrombosis

Fig 4 shows the showing outcome of surgical thrombectomy for ilio-femoral deep vein thrombosis. The result showed that, 100% had successful removal of blood clots (thrombus) through surgical thrombectomy, 15.8% had significant post thrombotic syndrome. However, there were no cases of pulmonary embolism detected during or after the surgery.

The result in Table 3 showed that there was no significant association between age and the type of vein as $p > 0.05$ ($\chi^2 = 4.10$; $df = 5$; $p = 0.53$).

Table 3: Chi-square test showing association between age and the type of vein.

Age in years	Type of vein		Total F(%)	df	χ^2	p-value	Decision
	Femoral F(%)	Calf vein F(%)					
20-29	0(0.0)	1(9.1)	1	5	4.10	0.53	H ₀ Not rejected
30-39	2(25.0)	1(9.1)	3				
40-49	4(50.0)	3(27.3)	7				
50-59	0(0.0)	2(18.2)	2				
60-69	1(12.5)	3(27.3)	4				
70-79	1(12.5)	1(9.13)	2				
Total	8(100)	11(100)	19				

*Not significant

The result in Table 4 showed that there was no significant association between age and the type of DVT performed as $p > 0.05$ ($\chi^2 = 3.15$; $df = 5$; $p = 0.67$).

Table 4: Chi-square test showing association between age and the type of DVT.

Age in years	Type of DVT		Total F(%)	df	χ^2	p-value	Decision
	Acute F(%)	Acute-on-chronic F(%)					
20-29	1(100)	0(0.0)	1	5	3.15	0.67	H ₀ Not rejected
30-39	3(100)	0(0.0)	3				
40-49	6(85.7)	1(14.3)	7				
50-59	2(100)	0(0.0)	2				
60-69	3(75.0)	1(25.0)	4				
70-79	1(50.0)	1(50.0)	2				
Total	16(100)	3(100)	19				

*Not significant

The result in Table 5 showed that there was no significant association between gender and type of vein involved in surgery as $p > 0.05$ ($\chi^2 = 3.51$; $df = 1$; $p = 0.61$).

Table 5: Chi-square test showing association between gender and type of vein.

Gender	Type of DVT		Total F(%)	df	χ^2	p-value	Decision
	Femoral F(%)	Calf vein F(%)					
Male	7(58.3)	5(41.7)	12	1	3.51	0.61*	H ₀ Not rejected
Female	1(14.3)	6(85.7)	7				
Total	8(100)	11(100)	19				

*Not significant

The result in Table 6 showed that there was no significant association between gender and type of DVT as $p > 0.05$ ($\chi^2 = 0.19$; $df = 1$; $p = 0.89$).

Table 6: Chi-square test showing associated between gender and type of DVT.

Gender	Type of DVT		Total F(%)	df	χ^2	p-value	Decision
	Acute chronic F(%)	Acute-on- chronic F(%)					
Male	10(83.3)	2(16.7)	12	1	0.19	0.89*	H ₀ Not rejected
Female	6(85.7)	1(14.3)	7				
Total	16(100)	3(100)	19				

*Not significant

4. DISCUSSION

The findings of the study showed that more than half of the patients had calf vein DVT in addition to femoral or ilio-femoral DVT. This finding is similar to other report from a retrospective cohort study which observed that iliofemoral DVT surgery involved femoral vein alone or in combination with iliac vein [3].

The study highlighted the effectiveness of surgical thrombectomy in removal of thrombus following iliofemoral DVT, as this was achieved in all the patients. This is in concert with a previous retrospective study, which reported that percutaneous mechanical thrombectomy effectively restored graft patency in iliofemoral DVT cases [4]. A similar study also observed that both percutaneous and surgical thrombectomy techniques are effective for ilio-femoral DVT [7].

The result of this study revealed that, many of the patients had acute DVT while about a quarter had acute-on-chronic DVT. This finding gives credence to other research that reported that surgical thrombectomy is recommended for acute iliofemoral DVT and acute-on-chronic DVT in selected cases [14]. A randomized controlled trial reported that endovascular thrombus removal was superior to standard anticoagulation in reducing post-thrombotic syndrome in acute ilio-femoral DVT cases [13]. Furthermore, a systematic review showed that surgical thrombectomy is effective for acute iliofemoral DVT and should also be considered in cases of acute-on-chronic DVT [8]. An evidence-based consensus statement based on expert

opinion, recommended surgical thrombectomy for acute iliofemoral DVT and in selected cases of acute-on-chronic DVT [14-15]. Other researchers found that surgical thrombectomy demonstrated favourable outcomes in patients with acute iliofemoral DVT and acute-on-chronic DVT, with identified predictors of successful outcome [9].

With regards to the outcome of surgical thrombectomy for ilio-femoral deep vein thrombosis, all had successful removal of blood clots (thrombus) through surgical thrombectomy, with 15.8% having significant post thrombotic syndrome evidenced by recurrent limb edema and pain. However, there were no cases of pulmonary embolism detected during or after the surgery. This result corroborates other similar reports that showed higher rate of successful thrombus removal compared to anticoagulation alone in patients with iliofemoral DVT [2, 17]. The result provided clarification on the outcomes of thrombectomy for iliofemoral DVT, highlighting successful thrombus removal and reduction in the risk of post-thrombotic syndrome [18]. Other findings, based on a systematic review, showed high technical success rates in ilio-femoral DVT treatment with percutaneous mechanical thrombectomy [11]. Surgical thrombectomy is a valuable intervention for achieving successful thrombus removal and potentially reducing the risk of post-thrombotic syndrome in iliofemoral DVT [12].

The study was limited by the small sample size and the purposive sampling technique adopted. Hence, the findings from the study may not be representative of patients with DVT.

Conclusion:

The safety profile and recanalization rate following surgical thrombectomy for ilio-femoral DVT is very good especially when done at the acute phase of the DVT. This also significantly prevents the occurrence of post thrombotic syndrome.

Ethical Considerations

Ethical approval for the study was obtained from the ethics and review board of the University of Port Harcourt Teaching Hospital and from the Medical Directors of Private clinics.

REFERENCES

1. Benilde, C. & Gautiero, P. "Early thrombus removal" in iliac-femoral deep vein thrombosis for prevention of post-thrombotic syndrome. *Annals of Translational medicine*. 2019;7(Suppl 8): S343. doi: [10.21037/atm.2019.09.102](https://doi.org/10.21037/atm.2019.09.102)
2. Vedantham, S., Goldhaber, S. Z., Julian, J. A., Kahn, S. R., Jaff, M. R., Cohen, D. J. & Razavi, M. K. Quality improvement guidelines for the treatment of lower-extremity deep vein thrombosis with use of endovascular thrombus removal. *Journal of Vascular and Interventional Radiology*, 2016;27(9):1315-1325.
3. Baekgaard, N., Broholm, R., Just, S., & Jorgensen, M. (2017). Endovascular treatment of chronic iliofemoral venous occlusive disease. *CardioVascular and Interventional Radiology*. 2017;40(3):346-353.
4. Tassiopoulos, A. K., Golts, E., Oh, D., Labropoulos, N., Loh, T. M., & Deitch, J. S. Single-center experience with an innovative device for percutaneous mechanical thrombectomy of clotted arteriovenous grafts. *Annals of Vascular Surgery*. 2018;52, 198-204.

5. George, E. L., Baldassarre, F., Brieger, D., Hankey, G. J., & Misra, A. Lower extremity deep venous thrombosis: Evaluation of a clinical practice guideline. *ANZ Journal of Surgery*. 2019;89(12):1587-1593.
6. Enden, T., Haig, Y., Kløw, N. E., & Slagsvold, C. E. Long-term outcomes after additional catheter-directed thrombolysis versus standard treatment for acute iliofemoral deep vein thrombosis (the CaVenT study). *European Journal of Vascular and Endovascular Surgery*. 2022;63(1):102-110.
7. Lurie, F., Lurie, J., & Viola, V. Percutaneous and Surgical Thrombectomy for Iliofemoral Deep Venous Thrombosis. *Phlebology: The Journal of Venous Disease*. 2020;35(2_suppl):161-170.
8. Nguyen, T. N., Kang, E., Hovsepian, D. M. The Contemporary Management of Deep Vein Thrombosis in Interventional Radiology. *Techniques in Vascular and Interventional Radiology*. 2020;23(2):100673.
9. Cho, J., DeMartino, R., & Romero, M. Outcomes and Predictors of Success After Surgical Thrombectomy for Deep Venous Thrombosis. *Journal of Vascular Surgery: Venous and Lymphatic Disorders*. 2023;11(3):477-484.
10. Horlander, K. T., Mannino, D. M., & Leeper, K. V. Pulmonary Embolism Mortality in the United States: 1999–2014. *The American Journal of Medicine*. 2023;132(2):240-247.
11. Jia, Z., Wu, A., & Tam, M. A systematic review of 167 percutaneous mechanical thrombectomy interventions for the treatment of iliofemoral deep vein thrombosis. *Journal of Vascular and Interventional Radiology*. 2020;31(3):381-390.
12. Elsharawy, M., & Elzayat, E. Surgical management of acute iliofemoral deep vein thrombosis: A review of literature. *Annals of Vascular Surgery*, 2022;76, 491-500.
13. Comerota, A. J., Kearon, C. & Gu, C. Endovascular Thrombus Removal for Acute Iliofemoral Deep Vein Thrombosis. *Circulation*. 2019;139(9):1162-1173.
14. Jaff, M. R., McMurtry, M. S. & Archer, S. L. Management of Massive and Submassive Pulmonary Embolism, Iliofemoral Deep Vein Thrombosis, and Chronic Thromboembolic Pulmonary Hypertension. *Journal of the American College of Cardiology*, 2019;74(8):1043-1066.
15. Patel, I. J., Davidson, J. C. & Nikolic, B. Consensus Guidelines for Periprocedural Management of Coagulation Status and Hemostasis Risk in Percutaneous Image-guided Interventions. *Journal of Vascular and Interventional Radiology*. 2021;32(3):370-381.
16. Kahn, S. R., Comerota, A. J. & Cushman, M. The Postthrombotic Syndrome: Evidence-based Prevention, Diagnosis, and Treatment Strategies: A Scientific Statement From the American Heart Association. *Circulation*. 2022;145(3):e96-e119.
17. Kesieme E. B., Okokhere P., Eluehike S. & Isabu P. Challenges in the management of iliofemoral deep vein thrombosis in a resource limited setting: a case series. *The Pan African Medical Journal*. 2014;18:254. doi: 10.11604/pamj.2014.18.254.2569.
18. Enden, T., Resch, S. & White, C. Thrombectomy for acute iliofemoral vein thrombosis – Authors’ reply. *The New England Journal of Medicine*. 2018;378(4), 393-394.