

# **Exceptional association of pneumatosis cystoides intestinalis with ascites secondary to gastric ulcer.**

## **Abstract**

Pneumatosis cystoides Intestinalis (PCI) is a rare disease characterized by the presence of gas-filled cysts in the intestinal wall, which can affect the entire digestive tract, with a predilection for the small intestine and colon. It can be primary or secondary, associated with multiple gastrointestinal or other pathologies. Diagnosis can be challenging to establish, and only a combined radiological and endoscopic evaluation ensures proper therapeutic management, often preventing unnecessary emergency surgical interventions. The patients with pneumatosis cystoides intestinalis are usually treated conservatively; the surgical treatment is reserved for complications. We report an unusual case of pneumatosis cystoides intestinalis associated with ascites, in a 65 year-old patient who presented with chronic abdominal pain and vomiting. The abdomen CT showed multiple small air cysts in the intestinal wall, ascites, and free abdominal air. Upper gastrointestinal endoscopy showed a gastric ulcer without no evidence of malignancy on histopathological examination, but with the presence of *Helicobacter pylori*. Ascitic fluid analysis revealed an exudative pattern. The patient was treated with *Helicobacter pylori* eradication therapy along with proton pump inhibitors. The outcome was favorable with the disappearance of abdominal pain and ascites. An abdominopelvic CT scan performed after 4 months showed complete regression of cystic images and ascites. To date, very few cases of intestinal pneumatosis associated with ascites have been reported.

## **Keywords:**

Pneumatosis cystoides intestinalis – Ascites – Gastric ulcer – *Helicobacter Pylori* – Abdominal CT scan

## Introduction:

Pneumatosis cystoides Intestinalis (PCI) is a rare disease characterized by the presence of gas-filled cysts in the intestinal wall, which can affect the entire digestive tract, with a predilection for the small intestine and colon. The prevalence of PCI is difficult to determine, as patients are mostly asymptomatic. It can be primary or secondary, linked to a diverse range of gastrointestinal and non-gastrointestinal disorders. The presence of PCI may be indicated by a basic X-ray of the digestive tract revealing alterations in the intestinal wall, however, a computed tomography (CT) scan, is often required for definitive diagnosis.

The aim of our work is to report a rare case of pneumatosis cystoides intestinalis associated with ascites, resulting from a gastric ulcer.

## Case-report:

A 65-year-old patient, known case of chronic obstructive pulmonary disease (COPD), with a history of chronic active smoking, presented for chronic abdominal pain associated with vomiting evolving over 1 year, along with anorexia, asthenia, and weight loss. Clinical examination revealed a lean patient (BMI=18.1), afebrile, with ascites, abdominal tenderness, and diffuse meteorism, without palpable masses.

The abdomen CT showed multiple small air cysts in the intestinal wall (Figure 1) with ascites and moderate pneumoperitoneum. Other organs, including the liver and kidney, appeared normal (Figure 1).

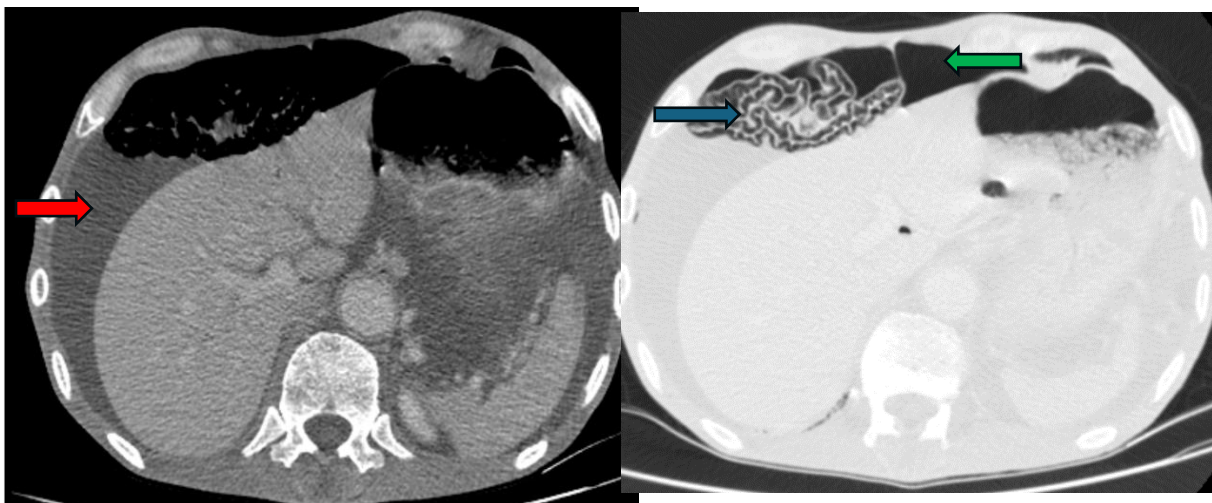


Figure 1: CT scan image demonstrating intestinal pneumatosis cystoides (blue arrow), ascites (red arrow), and pneumoperitoneum (green arrow).

The thoracic CT scan (Figure 2) revealed emphysematous lungs, with dilatations of cystic bronchi in the right upper lobe as well as a lateral-tracheal air pocket. This finding was consistent with chronic obstructive pulmonary disease (COPD).

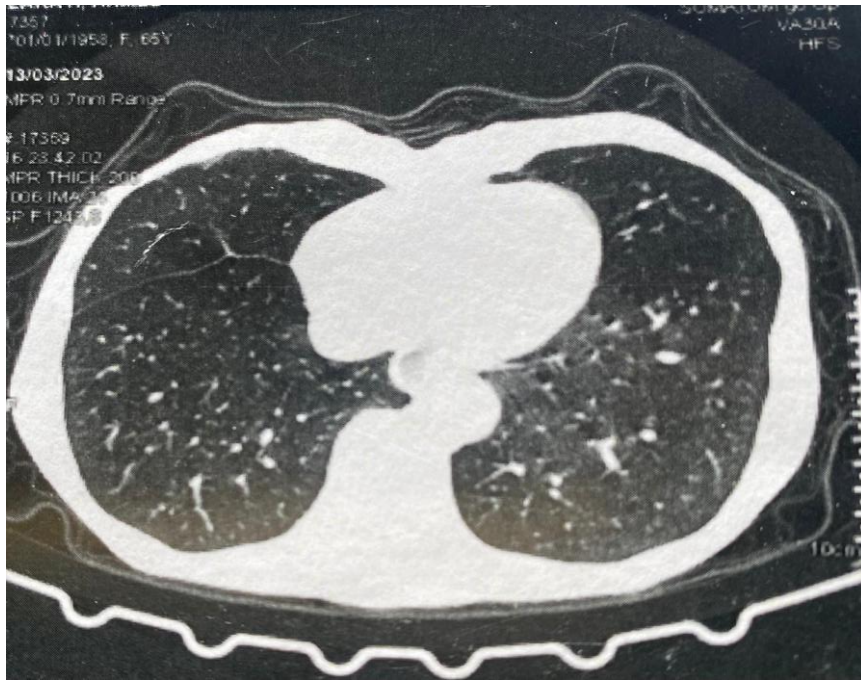

Figure 2: Thoracic CT scan showing pulmonary emphysema.

An ascitic tap was performed, revealing an exudative fluid with a protein concentration of 31 g/L, negative adenosine deaminase (ADA) assay, and negative GeneXpert MTB assay for *Mycobacterium tuberculosis*. Cytological examination of the ascitic fluid showed no abnormalities. Renal and hepatic function tests were normal.

For etiological investigation of pneumatosis cystoides intestinalis, upper and lower gastrointestinal endoscopy was performed on this patient. Upper gastrointestinal endoscopy revealed a gastric ulcer at the angularis with regular borders without signs of malignancy on histopathological examination (Figure 3). *Helicobacter pylori* was detected in biopsies. Colonoscopy showed no abnormalities.

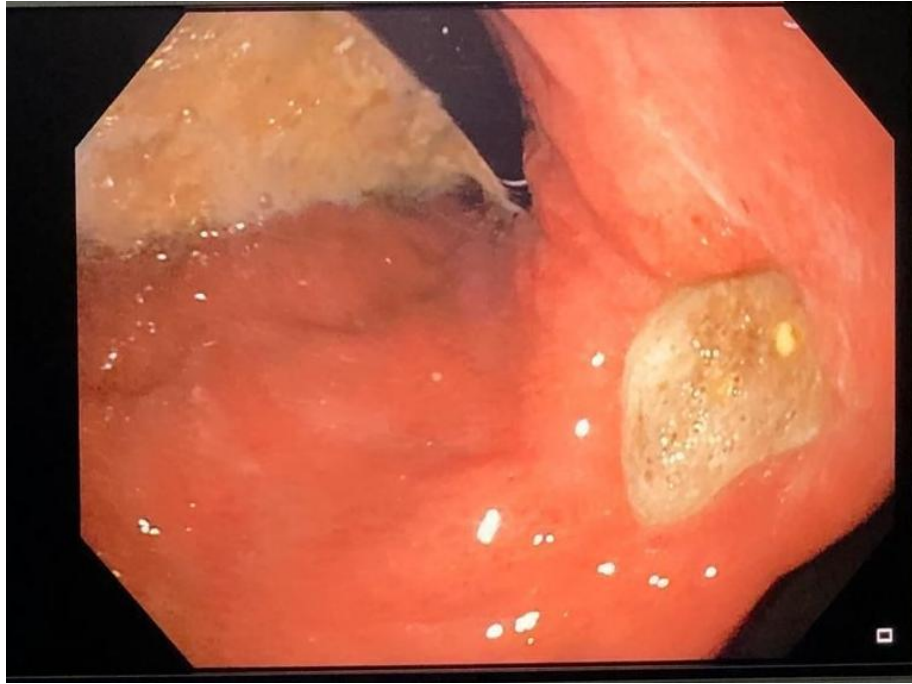


Figure 3: Gastric ulcer of the angularis

Thus, the diagnosis of intestinal pneumatosis cystoides associated with ascites and secondary to a gastric ulcer was established.

The treatment consisted of eradicating *Helicobacter pylori* (concomitant quadruple therapy: double-dose proton pump inhibitor (PPI), metronidazole, clarithromycin, and amoxicillin) for 14 days, in addition to the treatment for chronic obstructive pulmonary disease (beta-2 stimulant bronchodilators + anticholinergics). The PPI (Proton Pump Inhibitor) was extended by 2 weeks in order to complete a 4-week treatment course.

The outcome was favorable with the disappearance of abdominal pain and ascites. An abdominopelvic CT scan performed after 4 months showed complete regression of cystic images and ascites. (Figure 4)

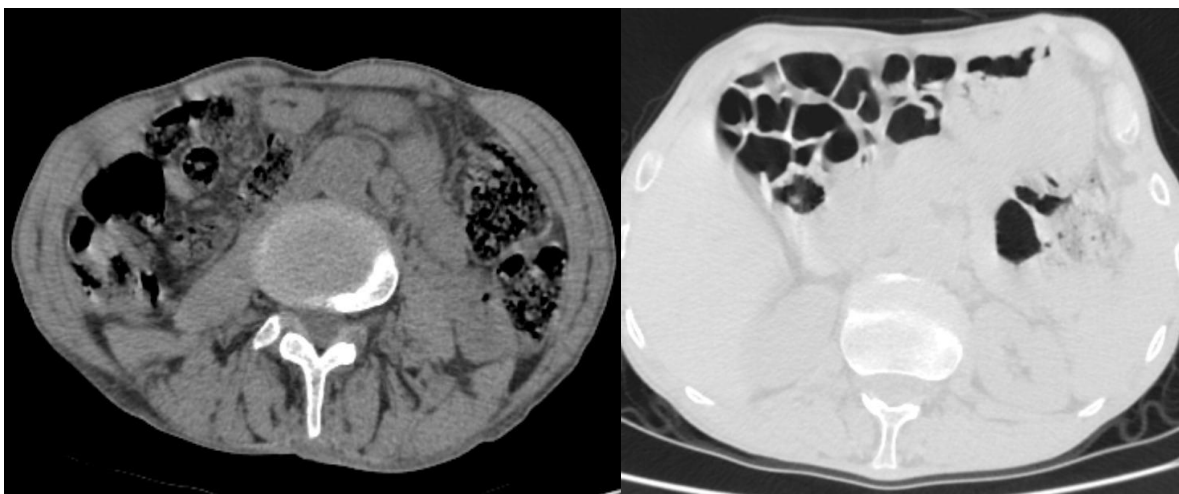


Figure 4: CT scan after 4 months

## Discussion:

Our observation illustrates a case of pneumatosis cystoides intestinalis (PCI) with ascites, secondary to a *Helicobacter pylori* positive gastric ulcer, in a patient being followed for COPD.

PCI is a rare condition, first described in 1730 by Duvernoy. It affects individuals of all ages, but is commonly reported in adults. The age of onset typically ranges between 40 and 50 years. There is a male predominance with a sex ratio that varies from 1 to 3 (1). PCI is characterized by the presence of gas-filled cysts measuring from a few millimeters to several centimeters in diameter within the mucosa or submucosa of the gastrointestinal tract. Thus, it can develop in any part of the gastrointestinal tract, although the literature describes few cases of intestinal pneumatosis cystoides occurring in the duodenum and rectum. However, the small intestine appears to be more affected than the colon, and the association of both locations is possible. (1-2)

On the physiopathogenic level, three theories have been proposed. The first theory, called "mechanical," hypothesizes that gas dissects the submucosa from the digestive lumen due to local intraluminal hyperpressure secondary to digestive obstruction (3). A second theory, the "pulmonary" theory, explains that thoracic hyperpressure, present in subjects with chronic obstructive pulmonary disease or asthma, is responsible for gas diffusion to the digestive serosa following a perivascular or perilymphatic route via a mediastinal relay (4-5). A third theory, the "bacterial" theory, suggests that proliferation of anaerobic bacteria is the cause of gas formation that penetrates the digestive wall through mucosal breach or due to mucosal hyperpermeability (6). Thus, numerous causes have been described: inflammatory bowel diseases, pulmonary or gastrointestinal obstructive diseases, malignant hematopathies, collagenoses, and peptic disease (1).

In our patient, PCI was secondary to a gastric ulcer related to chronic peptic ulcer disease associated with *Helicobacter pylori* infection, in the context of COPD.

Most cases, digestive symptoms are nonspecific, characterized by vague abdominal pain of varying intensity, diffuse or localized, accompanied by bowel disturbances. Some rare complications related to cystic volume have been described: volvulus, intussusception, perforation, and bleeding (7). In our case, the patient presented with nonspecific symptoms consistent with what is described in the literature. However, the observed ascites constitutes a distinct feature in this case.

The literature review revealed only five cases of PCI associated with ascites. The first case was described by V.M. Muyembe in 2002 (8) at a hospital in Kenya, followed by I. Serraj in 2006 (9) and K. El Hattabi in 2021 in Morocco (10). All of these cases involved patients with a history of chronic duodenal ulcers who were hospitalized for post-ulcer pyloric stenosis associated with ascites. Surgical laparotomy revealed features of intestinal pneumatosis cystoides. In four cases, the ascites resolved after etiological treatment, while one patient was lost to follow-up.

The diagnosis of PCI is mainly based on paraclinical explorations. It can already be suggested on plain abdominal radiography (AP) in the presence of rounded air-filled

images clustered in bunches like “grapes”. Two indirect signs are important to look for: the Moreau-Chilaiditi sign, which corresponds to the interposition of multiple clusters of bubbles between the liver and the right diaphragmatic dome, and a possible pneumoperitoneum indicating the rupture of a subserous cyst (11). PCI is the leading cause of pneumoperitoneum without digestive perforation. It occurs in 15% of small bowel cases and in 2% of colonic cases. Discordance between clinical and radiological signs should prompt a diagnosis of PCI, thus avoiding unnecessary surgery(12,13). However, abdominal CT scan are more sensitive in distinguishing PCI, making it the gold standard for diagnosis(14). It reveals rounded lucencies along the digestive wall without air-fluid levels, unlike intraluminal gas.

Colonoscopy allows for the identification of cysts, which appear as small, variable-sized, pseudo-polypoid rounded formations covered with a pale and transparent mucosa, sometimes ulcerated (Figure 5). Typically, the cyst collapses upon puncture or biopsy with a “popping sound” (1).

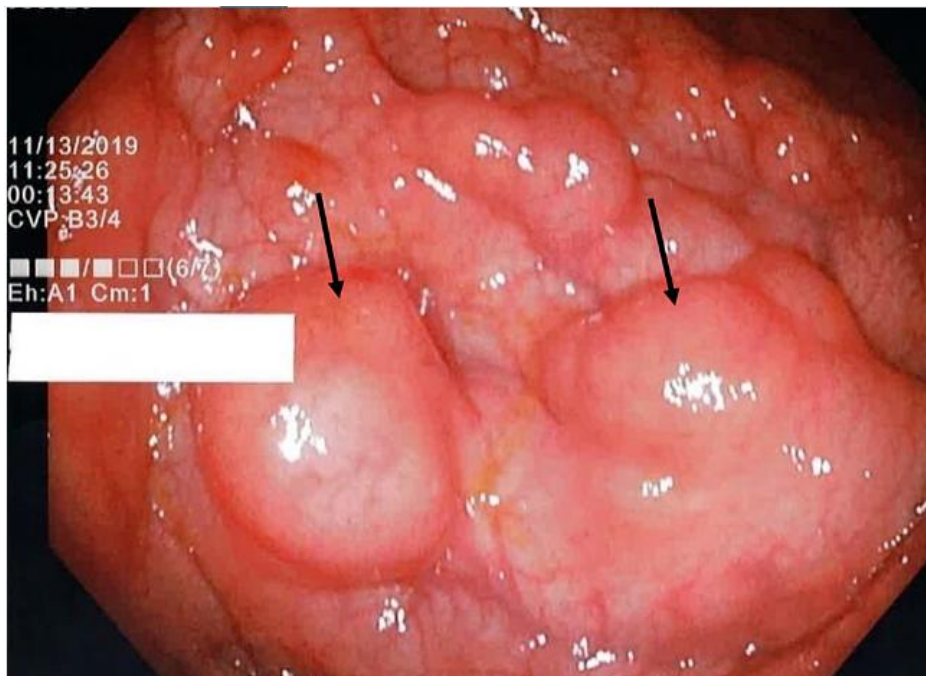


Figure 5: Colonoscopy showing images of pneumatosis cystoides intestinalis (PCI) (15)

In our case, colonoscopy revealed no abnormalities, as the lesions were predominantly located in the small intestine.

The spontaneous evolution of PCI, whether ulcerative or otherwise, is favorable in the majority of cases, with complete regression of cysts, as the treatment relies on addressing the underlying disease. Exploratory laparotomy is indicated in cases of peritoneal irritation or if persistent intestinal obstruction occurs in PCI (16).

**Conclusion :**

Pneumatosis cystoides intestinalis is a rare condition, typically diagnosed radiologically but can also be encountered unexpectedly during laparotomies. Causes can be gastrointestinal or extraintestinal, sometimes overlapping. Treatment is primarily medical, but surgical intervention may be necessary when addressing the underlying cause. The association of intestinal pneumatosis cystoides with ascites is rare. However, the underlying mechanism remains unclear.

## References:

1. Laclotte D, Bigard M. Laclotte D, Bigard M. Laclotte D, Bigard M. Pneumatose kystique intestinale. *Encycl Mèd Chir ( Elsevier Masson, Paris), Gastro-entérologie*, 9-061-A-30,2010,8pages
2. Serraj, I., El Kihal, L., Mohcine, R. *et al.* Pneumatose kystique intestinale avec ascite: association exceptionnelle. *Acta Endosc* **36**, 357–362 (2006).  
<https://doi.org/10.1007/BF03006042>
3. Heng Y, Schuffler MD, Haggitt RC, Rohrmann CA. Pneumatosis intestinalis: a review. *Am J Gastroenterol* 1995;90:1747-58
4. Ho LM, Paulson EK, Thompson WM. Pneumatosis intestinalis in the adult: benign to life-threatening causes. *AJR Am J Roentgenol* 2007; **188**:1604-13.
5. Pear BL. Pneumatosis intestinalis: a review. *Radiology* 1998;207:13-9
6. Yale CE, Balish E, Wu JP. The bacterial etiology of pneumatosis cystoides intestinalis. *Arch Surg* 1974;109:89-94.
7. Khalil PN, Huber-Wagner S, Ladurner R, Kleespies A, Siebeck M, Mutschler W. Natural history, clinical pattern and surgical considerations of pneumatosis intestinalis. *Eur J Med Res*. 2009;14(6):231–9.
8. Muyembe V.M. Pneumatosis cystoides intestinalis associated with ascites and pyloric stenosis secondary to a chronic duodenal ulcer: case report. *East Afr Med J* 2002; **79**: 667-8.
9. Serraj, I., El Kihal, L., Mohcine, R. *et al.* Pneumatose kystique intestinale avec ascite: association exceptionnelle. *Acta Endosc* **36**, 357–362 (2006).  
<https://doi.org/10.1007/BF03006042>
10. El Hattabi K, Lafkih O, Bensardi F, Elbakouri A, Bouali M, Fadil A. Pneumatosis cystoides intestinalis with pneumoperitoneum secondary to stenosing pyloro-duodenal peptic ulcer: Case series of three patients and literature review. *Int J Surg Case Rep*. 2021 Apr;81:105772. doi: 10.1016/j.ijscr.2021.105772. Epub 2021 Mar 13. PMID: 33743257; PMCID: PMC8010462.
11. Brientini F, Debilly M, Litzler JF. La Pneumatose kystique colique: un diagnostic scanographique spécifique. *J Radiol*. 1995;76(2-3):135–40
12. Rodriguez C, Le Roux Y. Pneumatose kystique colique droite r6v616e par un pneumop6ritoine. *J Chir* 2002; **139**: 117-9.
13. Hwang J. Pneumatose cystoides intestinalis with free intraperitoneal air: a case report. *Am Surg* 2003; **69**: 346-9.
14. Ho LM, Paulson EK, Thompson WM. Pneumatosis intestinalis in the adult: benign to life-threatening causes. *AJR Am J Roentgenol*. 2007;188:1604–13
15. Lommen M J, Zineldine O, Mehta T I, *et al.* (August 01, 2020) Pneumatosis Cystoides Intestinalis Identified on Screening Colonoscopy With Associated Pneumoperitoneum. *Cureus* **12**(8): e9512. doi:10.7759/cureus.9512
16. Khalil PN, Huber-Wagner S, Ladurner R, *et al.* Natural history, clinical pattern, and surgical considerations of pneumatosis intestinalis. *Eur J Med Res*. 2009;14:231–9.