

"Uncommon Encounter: Colonic Obstruction as the Initial Presentation of Metastatic Distal Pancreatic Cancer – A Case Report"

Abstract:

Background:

Pancreatic carcinoma poses a significant global health threat ranking as 6th leading cause of cancer-related deaths. Distal pancreatic cancer, located in the body and tail of the pancreas, presents unique challenges due to delayed diagnosis and often advanced stages at presentation. This case report highlights a rare occurrence of metastatic distal pancreatic cancer causing acute colonic obstruction without colonic metastasis as the primary clinical manifestation.

Case report:

A 68-year-old male with a history of diabetes and hypertension presented to the emergency department with diffuse abdominal pain, bilious vomiting, and obstipation. Computed tomography revealed a hypodense mass in the tail of the pancreas, causing desmoplastic reactions leading to severe luminal narrowing and colonic dilatation. Elevated cancer antigen (CA) 19–9 and CEA levels further indicated malignancy. Emergency exploratory laparotomy revealed an infiltrative pancreatic tumor necessitating distal pancreatectomy, splenectomy, sleeve resection of the stomach, subtotal colectomy, and rectal stump closure.

The postoperative course was unremarkable, and histopathological examination confirmed locally advanced moderately differentiated distal pancreatic carcinoma with acute colonic obstruction.

Clinical discussion:

We emphasize the aggressive nature of distal pancreatic cancer, often diagnosed at advanced stages. Locally advanced pancreatic cancer (LAPC) poses challenges for curative resection, and management focuses on disease control, symptom alleviation, and maintaining quality of life. Desmoplasia's role in pancreatic malignancy is underscored, impacting tumor microenvironment, chemoresistance, and complications like intestinal obstruction.

Conclusion:

In conclusion we stress the importance of a comprehensive, individualized approach to pancreatic cancer management. Understanding the intricate interaction between cancer cells and the microenvironment, particularly desmoplastic reactions, is evolving. Further research into diagnostic modalities and targeted treatments for desmoplastic reactions is essential for improving outcomes in pancreatic cancer.

Key words:

Distal pancreatic cancer, colonic obstruction, desmoplasia, chemoresistance, tumor microenvironment.

Introduction:

Pancreatic carcinoma is a major global health concern. The incidence on pancreatic cancer is gradually increasing standing as 12th most common cause of cancer and 6th most common cause of cancer related deaths(2). Globocan estimates revealed that there will be 495,773 diagnoses and 466,003 deaths from pancreatic cancer globally in 2020(4). pancreas and liver cancers are projected to surpass breast, prostate, and colorectal cancers to become the second and third leading causes of cancer-related death by 2030, respectively. Asia is the most affected continent with 47.1% of overall incidence. Distal pancreatic cancer specifically refers to tumors located in the body and tail of the pancreas, which is the left-sided region beyond the neck. Distal pancreatic tumors usually have a poorer prognosis compared to pancreatic head tumors attributable to their delayed presentation at an advanced stage usually associated with metastasis(5). The most common site of distant metastasis found at autopsy is the liver, followed by the peritoneum, lung and pleura, bones, and adrenal glands(6). However, metastatic pancreatic cancer has been reported in virtually every organ site. While less frequent than tumors in the pancreatic head, distal pancreatic cancers present their own set of challenges in diagnosis and management.

Metastatic pancreatic cancer to the colon is rare with only eight cases reported(7,8,9,10,11,12,13,14). To the best of our knowledge this is the 1st case of malignant pancreatic tumor presenting as acute colonic obstruction due to desmoplastic reaction without colonic metastasis as primary clinical manifestation.

Case presentation:

A 68-year-old diabetic and hypertensive male had arrived to the our emergency department (ED) with a history of diffuse abdominal pain for a week associated with bilious vomiting and obstipation for 2 days, loss of appetite and loss of weight. On examination, he was tachycardic and normotensive. Abdominal examination revealed gross distension with diffuse abdominal tenderness. Initial laboratory workup revealed elevated leukocyte count(14.3K/ml), ALP(152 IU/L) and hypoalbuminemia(3 g/dl). A computed tomography (CT) of the abdomen and pelvis showed Focal enhancing hypodense mass lesion in the tail of the pancreas with significant surrounding desmoplastic reaction causing encasement of the proximal descending colon resulting in severe luminal narrowing with significant dilatation of the transverse and ascending colon with caecal dilatation(>12cm). Infiltration of the mass lesion to the splenic hilum with loss of fat plane. Desmoplastic reaction of the lesion abutting the anterolateral aspect of the upper pole of the left kidney with loss of fat plane. Fat stranding with desmoplastic reaction of the lesion superiorly

abutting the greater curvature and adjacent fundus of the stomach with loss of fat plane. The cancer antigen (CA) 19–9 level was elevated to >500 U/ml (normal <35 U/ml) and CEA (6.81 ng/mL).

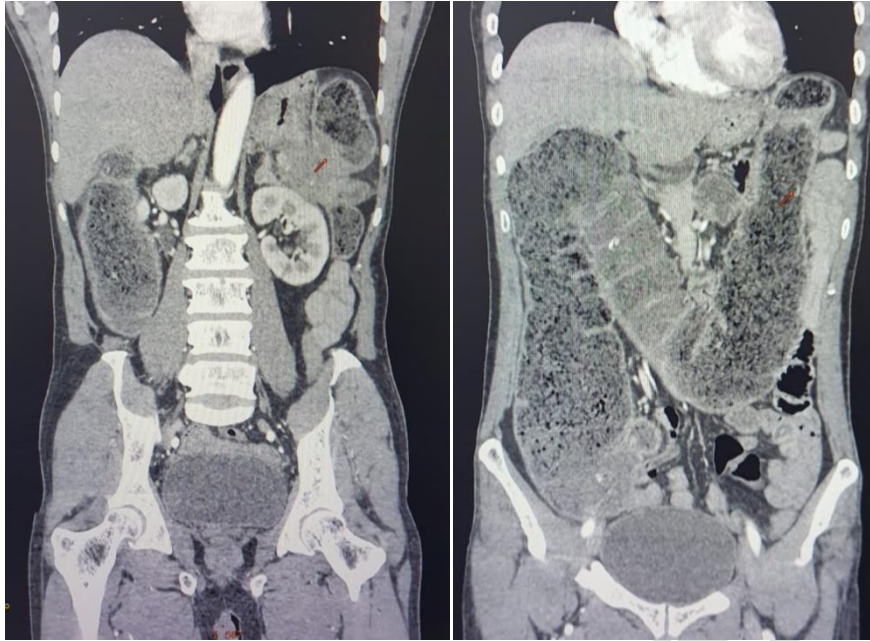


Fig.1: Distal pancreatic tumor abutting the descending colon causing obstructing, left gerota's fascia, splenic hilum.

Fig.2: gross caecal and proximal colonic dilatation due to acute obstruction.

In view of acute colonic obstruction, emergency exploratory laparotomy was deemed necessary. Preoperatively, a ryle's tube was placed, and the patient was resuscitated with isotonic fluids. The procedure was performed by the senior colorectal and Hepatobiliarypancreatic surgeon in a tertiary care hospital. An infiltrative growth measuring 5x5cm noted in distal pancreas infiltrating splenic hilum , greater curvature of stomach, splenic flexure of colon and left Gerota's fascia. Narrowing at splenic flexure of colon causing massive dilatation of transverse colon, ascending colon and caecum (Megacolon - max diameter of > 12 cms) causing doubtful ischemia of proximal dilated segment. Two to three small granular lesions noted over distal mesopancreas. Enlarged prominent common hepatic lymph nodes identified and harvested. No ascites or liver SOL or peritoneal or omental deposits. Distal pancreatectomy + splenectomy, sleeve resection of stomach with subtotal colectomy and closure of rectal stump with end ileostomy done under general and epidural anesthesia.

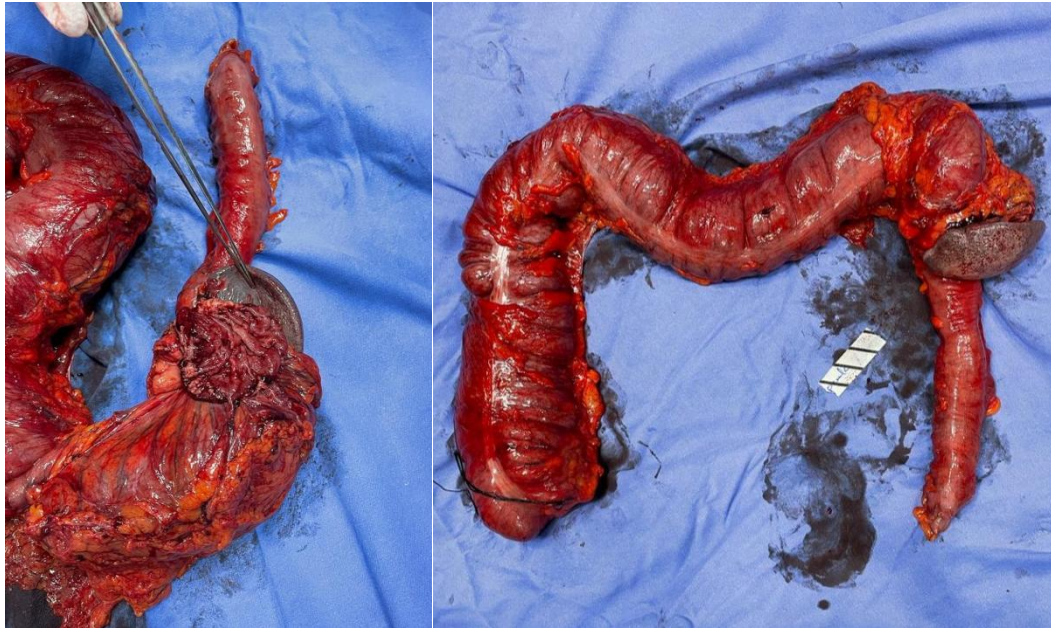


Fig.3,4: Gross specimen with distal pancreatic tumor obstructing the splenic flexure of colon, involving splenic hilum, left gerotas fascia, greater curvature of stomach

The postoperative course was unremarkable. The patient had return of small bowel function on postoperative day (POD) 1, the diet was advanced as tolerated and he was discharged on POD 7 with drain in-situ. The patient was seen in the outpatient department 1 week after his discharge and was doing well. Histopathological examination revealed Moderately differentiated adenocarcinoma - distal pancreas with stomach margin, kidney margin and splenic hilum positive for tumor deposits and section of colon negative for tumor deposits with areas of necrosis and desmoplastic tissue. 12/12 lymph nodes and omental deposits were negative for metastatic disease. The patient was referred to medical oncology for further systemic therapy. The final diagnosis is Locally advanced moderately differentiated distal pancreatic carcinoma (pT4N0M1) with acute colonic obstruction.

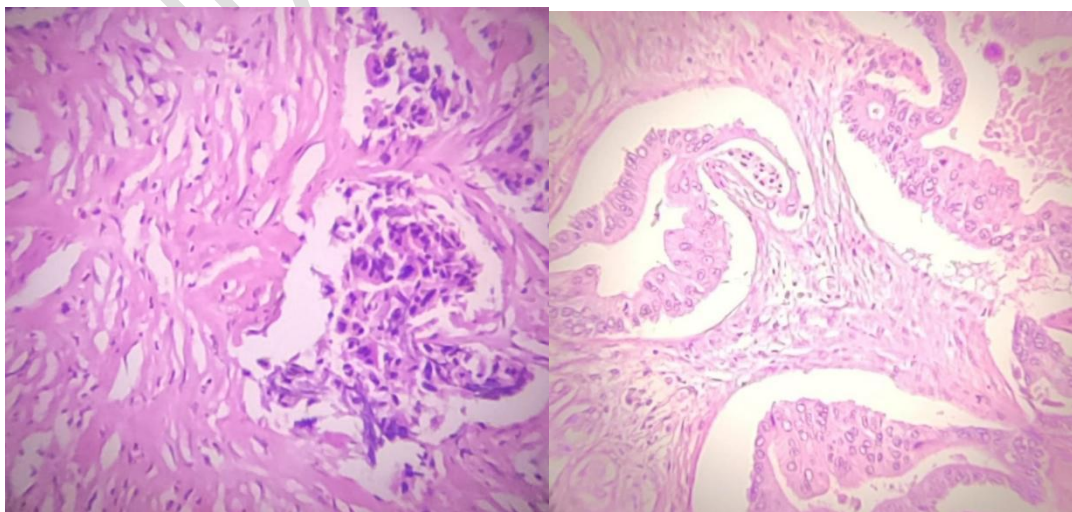


Fig.5: Infiltrating tumor cells with surrounding desmoplastic reaction
 Fig.6: Pancreatic tumor proper

CLINICAL DISCUSSION:

Distal pancreatic cancer is known for its aggressive nature, with a majority of cases being diagnosed at an advanced stage. When patients present with pancreatic cancer, fewer than 10% have tumors that are potentially curable with resection, and approximately one third have metastatic disease. More than one half of all patients with pancreatic cancer have disease that is considered locally advanced defined as a stage where the tumor has grown extensively and involves nearby structures, making it challenging to achieve complete surgical removal (resection). In LAPC, the cancer has typically spread to neighboring tissues and organs, such as blood vessels, nerves, or adjacent organs like the duodenum or stomach with no evidence of distal metastasis to other organs or distant lymph nodes(15,16). Management goals for LAPC include controlling disease progression, alleviating symptoms and maintaining the patient's quality of life rather than with curative intent.

The understanding of pancreatic cancer is progressing from a disease of malignant ductal cells-only, toward a complex system where tumor evolution is a result of interaction of cancer cells with their microenvironment which emphasized on the importance of desmoplasia in pancreatic malignancy(17). Desmoplasia is abnormal proliferation of activated pancreatic stellate cells mediated by primary signalling molecules (TGF β , PDGF AND FGF2) secreted by tumor epithelial cells and infiltrating immune cells and increased deposition of extracellular matrix constituted by collagen I, III, IV, hyaluronan, versican, fibronectin, osteonectin resulting in reduced elasticity of tumor tissue with a concomitant increase in tumor interstitial fluid pressure (IFP) Increased IFP results in a decreased rate of perfusion of therapeutic agents and consequently decreased efficacy. This desmoplastic reaction evokes biological and physiological chemoresistance for pancreatic cancer through anti-apoptotic mechanism and reduced tissue vascularity/perfusion. Excessive proliferation of the fibrotic stroma can cause loco-regional complications of pancreatic cancer like intestinal obstruction, vascular ischemia, bowel perforation(18,19).

Intense research is needed in the diagnostic modalities of desmoplasia such as molecular imaging and immunohistochemistry which can hugely impact the therapeutic decision making. Understanding the molecular and cellular mechanisms underlying desmoplastic reaction and help in develop new targeted treatment modalities for pancreatic cancer.

CONCLUSION:

A comprehensive and individualized approach is crucial for the management of pancreatic cancer, considering the type of presentation, patient's complaints, and disease status. In a case of acute bowel obstruction due to pancreatic cancer, upfront emergency surgical resection is considered as therapeutic and palliative treatment in addition to adjuvant chemoradiation. Understanding pancreatic cancer as a complex interaction between cancer cells and the microenvironment, particularly the fibrotic

stroma, is evolving. Improved diagnostic methods for desmoplastic reaction and fibrosis, such as noninvasive biomarkers and imaging tests, are needed. Advances in diagnostic methods and therapeutic strategies offer hope in addressing the challenges posed by this aggressive disease.

References:

1. McGuigan A, Kelly P, Turkington RC, Jones C, Coleman HG, McCain RS. Pancreatic cancer: A review of clinical diagnosis, epidemiology, treatment and outcomes. *World J Gastroenterol.* 2018 Nov 21;24(43):4846-4861. doi: 10.3748/wjg.v24.i43.4846. PMID: 30487695; PMCID: PMC6250924.
2. Siegel RL, Miller KD, Fuchs HE, Jemal A. Cancer statistics, 2022. *CA Cancer J Clin.* 2022 Jan;72(1):7-33. doi: 10.3322/caac.21708. Epub 2022 Jan 12. PMID: 35020204.
3. Rahib L, Smith BD, Aizenberg R, Rosenzweig AB, Fleshman JM, Matrisian LM. Projecting cancer incidence and deaths to 2030: the unexpected burden of thyroid, liver, and pancreas cancers in the United States. *Cancer Res.* 2014;74:2913–2921. [PubMed] [Google Scholar]
4. <https://gco.iarc.fr/today/data/factsheets/cancers/13-Pancreas-fact-sheet.pdf>.
5. Luo, G., Jin, K., Cheng, H., Guo, M., Gong, Y., Fan, Z. ... Yu, X. (2020). Prognosis of distal pancreatic cancers controlled by stage. *Experimental and Therapeutic Medicine*, 20, 1091-1097. <https://doi.org/10.3892/etm.2020.8795>
6. Pacheco F, Luciano E, Hebert D, Marar O. Metastatic pancreatic adenocarcinoma presenting as large bowel obstruction: A case report. *Int J Surg Case Rep.* 2023 Jan;102:107801. doi: 10.1016/j.ijscr.2022.107801. Epub 2022 Nov 23. PMID: 36502659; PMCID: PMC9763373.
7. Kelley K.M., Myer B.S., Berger J.J. Malignant large bowel obstruction: a rare presentation of metastatic pancreatic cancer. *Am. Surg.* 2016 Aug;82(8):e206–e208. PMID: 27657570.
8. Inada K., Shida D., Noda K., Inoue S., Warabi M., Umekita N. Metachronous colonic metastasis from pancreatic cancer seven years post-pancreatoduodenectomy. *World J. Gastroenterol.* 2013 Mar 14;19(10):1665–1668. doi: 10.3748/wjg.v19.i10.1665. PMID: 23539549; PMCID: PMC3602487.
9. Kim W, Lee Y. Metachronous colonic metastasis from pancreatic cancer presenting as mechanical obstruction: a case report. *Clin Imaging.* 2015 Jul-Aug;39(4):699-701. doi: 10.1016/j.clinimag.2015.01.010. Epub 2015 Jan 20. PMID: 25735449.
10. Yewale R., Ramakrishna B., Vijaykumar K., Balasundaram P., Arulprakash S., Radhakrishna P., Ramakrishna B.S. Pancreatic adenocarcinoma with synchronous colonic metastases. *ACG Case Rep. J.* 2020 Jan 7;7(1) doi: 10.14309/crj.0000000000000299. PMID: 32309493; PMCID: PMC7145160.
11. Nogueira S.T., Pinto B.L., Silva E.F., Garcia H.A., Carneiro F. Pancreatic cancer presenting as colonic disease. A rare case report. *Int. J. Surg. Case Rep.* 2018;44:4–7. doi: 10.1016/j.ijscr.2018.01.019. Epub 2018 Feb 9. PMID: 29454229; PMCID: PMC5852301.
12. Bellows C., Gage T., Stark M., McCarty C., Haque S. Metastatic pancreatic carcinoma presenting as colon carcinoma. *South. Med. J.* 2009 Jul;102(7):748–750. doi: 10.1097/SMJ.0b013e3181a8fad7. PMID: 19488001.

13. Ogu U.S., Bloch R., Park G. A rare case of metachronous skip metastasis of pancreatic cancer to the colon. *Am. Surg.* 2012 Jul;78(7):E342–E343. PMID: 22748524.
14. Pacheco F, Luciano E, Hebert D, Marar O. Metastatic pancreatic adenocarcinoma presenting as large bowel obstruction: A case report. *Int J Surg Case Rep.* 2023 Jan;102:107801. doi: 10.1016/j.ijscr.2022.107801. Epub 2022 Nov 23. PMID: 36502659; PMCID: PMC9763373.
15. DOI: 10.1200/JOP.2016.017376 *Journal of Oncology Practice* - published online before print October 11, 2016}.
16. van Veldhuisen E, van den Oord C, Brada LJ, Walma MS, Vogel JA, Wilmink JW, Del Chiaro M, van Lienden KP, Meijerink MR, van Tienhoven G, Hackert T, Wolfgang CL, van Santvoort H, Groot Koerkamp B, Busch OR, Molenaar IQ, van Eijck CH, Besselink MG; Dutch Pancreatic Cancer Group and International Collaborative Group on Locally Advanced Pancreatic Cancer. Locally Advanced Pancreatic Cancer: Work-Up, Staging, and Local Intervention Strategies. *Cancers (Basel).* 2019 Jul 12;11(7):976. doi: 10.3390/cancers11070976. PMID: 31336859; PMCID: PMC6679311.
17. Erkan, Mert and Hausmann, Simone and Michalski, Christoph and Schlitter, Melissa and Fingerle, Alexander and Dobritz, Martin and Friess, Helmut and Kleeff,DOI={10.3389/fphys.2012.00389},ISSN={1664-042X}
18. Whatcott CJ, Posner RG, Von Hoff DD, et al. Desmoplasia and chemoresistance in pancreatic cancer. In: Grippo PJ, Munshi HG, editors. *Pancreatic Cancer and Tumor Microenvironment*. Trivandrum (India): Transworld Research Network; 2012. Chapter 8. Available from: <https://www.ncbi.nlm.nih.gov/books/NBK98939/>
19. <https://onlinelibrary.wiley.com/doi/full/10.1111/cas.15890>