

Current Management of Choledocholithiasis-Narrative Review Article

Abstract

The most common management of choledocholithiasis involves the two-step method that involves the use of pre-operative endoscopic retrograde cholangiopancreatography (ERCP) followed by laparoscopic cholecystectomy in six weeks' time. But since the introduction of laparoscopic surgery, laparoscopic common bile duct exploration has been used as a single step method to treat this condition. Another method involves intraoperative endoscopic retrograde cholangiopancreatography (ERCP) and laparoscopic cholecystectomy in the same setting. As there is no consensus on management, we have conducted this review article to look at the various management options for choledocholithiasis.

Keywords-choledocholithiasis, endoscopic retrograde cholangiopancreatography, laparoscopic common bile duct exploration, open bile duct exploration and bile duct stones

Introduction

Choledocholithiasis is a complication of gallstone disease that presents with symptoms of abdominal pain, followed by passing of tea colored urine and pale stools. It is seen in about 10 to 15% of cases and it is diagnosed by elevated serum bilirubin, serum alkaline phosphatase and Alanine and Aspartate amino transferase. Confirmation of diagnosis is done with imaging by either using an ultrasound, computerized tomography, or magnetic resonance imaging. Bile duct stone can be divided into primary and secondary stone, with secondary stones being the most common cause of choledocholithiasis. (1)

The management of choledocholithiasis can be divided into endoscopic management which involves the use of endoscopic retrograde cholangiopancreatography (ERCP) and surgical management which involves laparoscopic or open common bile duct exploration. One determining factor as to which mode of management is the detection of choledocholithiasis before, during or after cholecystectomy.(2)

Endoscopic retrograde cholangiopancreatography (ERCP) can be performed as a preoperative, intraoperative, and post operative procedure. Surgical bile duct exploration can be performed as a laparoscopic common bile duct exploration and open common bile duct exploration. The surgical procedures are performed with cholecystectomy.(3)

The most common treatment option is a preoperative endoscopic retrograde cholangiopancreatography (ERCP) followed by laparoscopic cholecystectomy. The introduction of advanced laparoscopic surgical services has seen laparoscopic common bile duct exploration

being performed as a solo procedure for choledocholithiasis and it is slowly gaining ground. Another treatment option is to perform laparoscopic cholecystectomy and intraoperative endoscopic retrograde cholangiopancreatography (ERCP) in the same setting. The other treatment options include open common bile duct exploration and cholecystectomy followed by post operative endoscopic retrograde cholangiopancreatography (ERCP).(4,5)

These treatment options for choledocholithiasis can be divided into a one step or a two-step management option. The one step method involves common bile duct exploration which involves a laparoscopic or open procedure. The two-step method involves preoperative endoscopic retrograde cholangiopancreatography (ERCP) followed by laparoscopic cholecystectomy.(6,7)

Other treatment modalities for choledocholithiasis include intraoperative endoscopic retrograde cholangiopancreatography (ERCP) with concurrent laparoscopic cholecystectomy which is known as the rendezvous technique.(8)

Image I

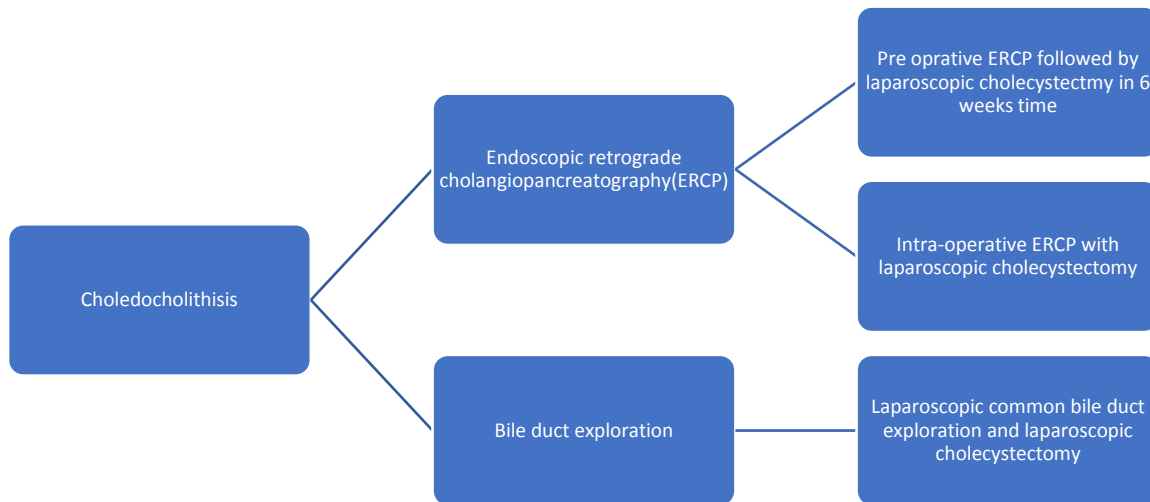


Image showing the algorithm of management of choledocholithiasis.

We have conducted this review article to look at the management of choledocholithiasis, the role of endoscopic retrograde cholangiopancreatography (ERCP) and the surgical options that include laparoscopic common bile duct exploration. The indication and complication of all these

procedures were investigated. The common algorithm of management for choledocholithiasis was also discussed here. We have conducted a literature review using PUBMED, Cochrane database of clinical reviews, Google scholar and semantic scholar looking for randomized control trials, systemic reviews, meta-analysis, observational and cohort studies from 1990 to 2024. All the articles obtained were in full text form. The following key words were used, “choledocholithiasis”, “Endoscopic retrograde cholangiopancreatography”, “laparoscopic bile duct exploration”, “open bile duct exploration “and “bile duct stones”. All articles were in English language and pediatric and pregnant patients were excluded from this review. Case reports and commentaries were excluded.

Discussion

Pre-operative endoscopic retrograde cholangiopancreatography (ERCP) followed by laparoscopic cholecystectomy.

This is the most common treatment option that is practiced in most hospitals for patients who have choledocholithiasis. Otherwise called as the two staged procedure, it involves performing an endoscopic retrograde cholangiopancreatography (ERCP) first to remove the stones in the common bile duct, and this is followed by a laparoscopic cholecystectomy in six to eight weeks’ time. Endoscopic retrograde cholangiopancreatography (ERCP) involves performing a sphincterotomy to allow passage for residual stones and in complex stones, an endoscopic balloon dilatation may be performed. The complications from this procedure include acute pancreatitis and acute cholangitis.(9–12)

The European Society of Gastrointestinal Endoscopy (ESGE) recommends performing an endoscopic sphincterotomy to allow residual stone to drain out and for large stone, an endoscopic balloon dilatation is recommended but it is associated with a higher risk of developing acute pancreatitis. Stone clearances can be achieved in up to 80% of cases.(13)

A prospective study by Zhou et al comparing all the three modalities for treatment of choledocholithiasis found that endoscopic retrograde cholangiopancreatography (ERCP) followed by laparoscopic cholecystectomy is the most popular treatment option as it is associated with reduced complication like bile leakage when it was compared with other surgical procedures.(14)

A meta-analysis by Zhu et al compared this modality against laparoscopic common bile duct exploration in the management of choledocholithiasis and this study concluded that there was no difference about the morbidity and mortality in both the intervention groups. These findings were also seen in a meta-analysis by Lu et al and Nagaraja et al who compared the two-stage versus the single stage management for common bile duct stones.(15–17)

A retrospective study by Yan et al comparing the endoscopic retrograde cholangiopancreatography (ERCP) and laparoscopic cholecystectomy against laparoscopic common bile duct exploration found that there was no difference with regards to the stone clearance, length of hospital stays and incidence of acute pancreatitis(18)

Successful clearance of common bile duct stone can be achieved in about 90% of cases in experienced hands but difficulty is encountered in cases of large stones, complex stone and altered anatomy like a previous upper gastrointestinal surgery.(14)

A meta-analysis comparing sphincterotomy plus balloon dilatation versus sphincterotomy alone by Dong et al concluded that endoscopic balloon dilatation was safer and more effective in the management of common bile duct stones. It was also associated with reduced incidence of bleeding and acute pancreatitis.(19)

Image II

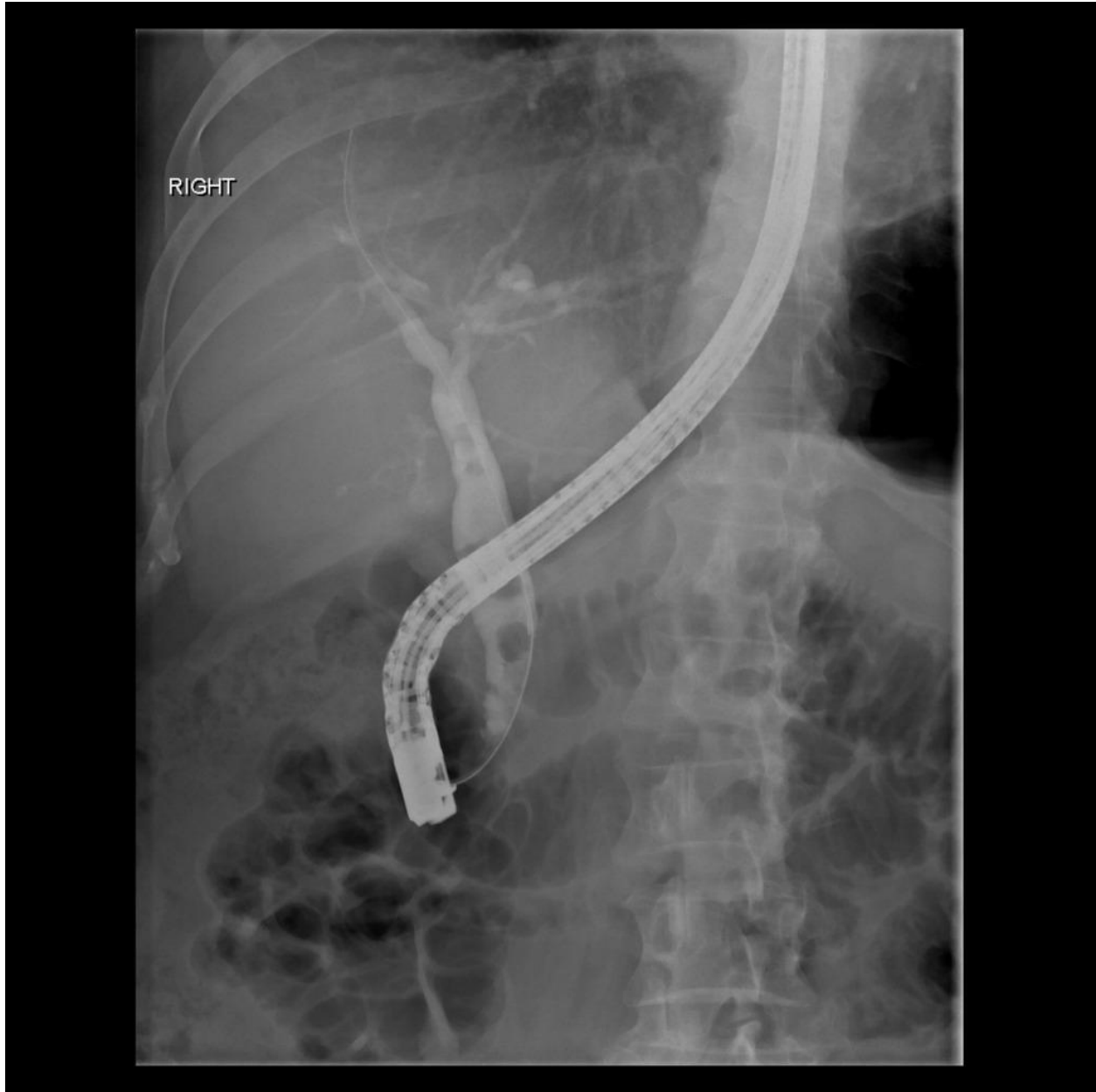

Image of endoscopic retrograde cholangiopancreatography (ERCP) with bile duct stones

Laparoscopic common bile duct exploration and cholecystectomy

This procedure involves laparoscopic exploration and removal of the common bile duct stones and cholecystectomy in a single setting. Access to the common bile duct stones can be achieved via the cystic duct or the common bile duct. A choledochal-scope is inserted, and the stones are removed. The procedure is then finished by performing a cholecystectomy. This procedure is safe and associated with reduced cost when compared to preoperative endoscopic retrograde cholangiopancreatography (ERCP), but it requires expertise in advance laparoscopy.(20–23)

Laparoscopic common bile duct exploration can also be performed in patients who have undergone failed endoscopic retrograde cholangiopancreatography (ERCP) and in a retrospective study by Kim et al resulted with a success rate of 98% and a morbidity rate of 3.4%.(24)

Closure of the choledochotomy was compared with T-tube insertion by Wang et al in his retrospective study, and he concluded that there was no difference with regards to mortality, bile leak, retained stone and hospital readmissions. Primary closure of the choledochotomy was safe.(25)

The trans-cystic approach is most used to perform common bile duct exploration but in large stone or difficult stones the trans-biliary approach is done. A T-tube is not required, and primary closure is usually performed as it is safe and effective. The rate of recurrence after performing a laparoscopic common bile duct exploration was lower than endoscopic retrograde cholangiopancreatography (ERCP).(26–28)

Laparoscopic common bile duct exploration is often underutilized due to its steep learning curve, the additional special instruments that must be used, the increase in operative time and the perception that endoscopic retrograde cholangiopancreatography (ERCP) is better.(29)

Another advantage of this procedure is the preservation of the duodenal papilla which is not cannulated and hence avoids the risk of acute pancreatitis and duodenal reflux.(30)

A meta-analysis by Wu et al comparing primary closure versus T-tube drainage in laparoscopic common bile duct exploration was safe and associated with a reduced risk of bile leak. It was also associated with reduced morbidity and mortality.(31)

A meta-analysis comparing laparoscopic common bile duct exploration versus preoperative endoscopic retrograde cholangiopancreatography (ERCP) by Nie et al was safe and associated with reduced morbidity, retained stones and risk of acute pancreatitis. This was also concluded by meta-analyses by Pan et al, Prasson et al and Singh et al.(32–35)

Table I

Study	Study type	N=number s	Pre- ERCP Success Rate (%)	Laparoscopy CBD exploration Success Rate (%)	Pre- ERCP Morbidity Rate (%)	Laparoscopy CBD exploration Morbidity Rate (%)
Nagaraja et al (2014)	Systemic review	166	73.1%	86.3%	14.8%	17.3%
Singh et al(2018)	Systemic review	1513	82.2%	88.1%	13.9%	14.6%
Yan et al(2022)	Retrospective study	60	93.8%	96.4%	3.6%	3.6%

Comparison of preoperative endoscopic retrograde cholangiopancreatography (ERCP) versus Laparoscopic common bile duct exploration

Intra-operative endoscopic retrograde cholangiopancreatography (ERCP) and cholecystectomy-The rendezvous procedure

This procedure is done in a single session where a laparoscopic cholecystectomy is performed, cannulation of the common bile duct is done via the cystic duct and a guidewire is passed down to the Ampulla. An Endoscopic retrograde cholangiopancreatography is now performed, and the guidewire is used to cannulate the common bile duct and remove the stones. Once this procedure is done, the cholecystectomy is completed.(36–38)

A meta-analysis by Lin et al compared the rendezvous procedure with pre-operative endoscopic retrograde cholangiopancreatography (ERCP) and laparoscopic cholecystectomy and they concluded that the rendezvous procedure was associated with a reduced morbidity rate, reduced acute pancreatitis rate, shorter hospital stays but longer operative time.(39)

A meta-analysis of randomized control trials by Liao et al comparing the rendezvous procedure with pre-operative endoscopic retrograde cholangiopancreatography (ERCP) and laparoscopic cholecystectomy concluded that the rendezvous procedure was associated with reduced morbidity, reduced pancreatitis rate and reduced risk of retained stones.(40)

A randomized control trial of intra-operative endoscopic retrograde cholangiopancreatography (ERCP) versus laparoscopic common bile duct exploration was conducted by Poh et al and Muhammedoglu et al and they concluded that though both procedures were effective in treating common bile duct stone, per operative endoscopic retrograde cholangiopancreatography was effective in reducing the rate of retained stones.(41,42)

The main drawback to the rendezvous procedure is the prolonged anesthesia that is required, the position of the patient as surgery is performed in the supine position and endoscopy will require repositioning the patient. The advantage of this procedure is the reduced risk of bile leak and acute pancreatitis. The clinical presentation of the patient is also important with the presentation with septic shock or acute cholangitis are contraindication to this procedure. The success of the rendezvous procedure will depend on the cooperation of the surgeon and endoscopic team, and this may be an important factor in determining it.(43–45)

Conclusions

Based on the available evidence the two-stage procedure that involves the use of preoperative endoscopic retrograde cholangiopancreatography (ERCP) followed by laparoscopic cholecystectomy is still the most common procedure for choledocholithiasis as it easier to perform and coordinate between the surgeon and endoscopist. The risk factors are less, and this allows the laparoscopic cholecystectomy to be performed later.

The laparoscopic common bile duct exploration followed by cholecystectomy has the advantage of reduced cost and reduced hospital stay, but it is an advanced laparoscopic procedure which requires training, and it is associated with the risk of bile leak. This procedure also requires additional equipment which can increase the cost of the procedure.

The rendezvous procedure which involves performing the endoscopic retrograde cholangiopancreatography (ERCP) with concurrent laparoscopic cholecystectomy is a good single step procedure, but it requires the surgeon to cannulate the cystic duct and the ability of the endoscopist to perform the procedure in the supine position. The cooperation between the surgeon and endoscopist is essential for the success of this procedure.

This makes the decision of which procedure to perform for choledocholithiasis depends on the expertise available in the respective hospital and the logistics involved. The availability of these procedures in a regional hospital is important so as not to burden patients and to simplify the management of choledocholithiasis.

Conflict of interest - none

References

1. Copelan A, Kapoor BS. Choledocholithiasis: Diagnosis and Management. *Tech Vasc Interv Radiol*. 2015;18(4):244-255. doi:10.1053/j.tvir.2015.07.008
2. Hungness ES, Soper NJ. Management of common bile duct stones. *J Gastrointest Surg*. 2006;10(4):612-619. doi:10.1016/j.gassur.2005.08.015
3. Kroh M, Chand B. Choledocholithiasis, Endoscopic Retrograde Cholangiopancreatography, and Laparoscopic Common Bile Duct Exploration. Vol. 88, *Surgical Clinics of North America*. 2008. p. 1019–31. <https://doi.org/10.1016/j.suc.2008.05.004>
4. Lahmann BE, Adrales G, Schwartz RW. Choledocholithiasis--principles of diagnosis and management. *Curr Surg*. 2004;61(3):290-293. doi:10.1016/j.cursur.2003.07.014
5. Freitas ML, Bell RL, Duffy AJ. Choledocholithiasis: evolving standards for diagnosis and management. *World J Gastroenterol*. 2006;12(20):3162-3167. doi:10.3748/wjg.v12.i20.3162
6. Rosenthal RJ, Rossi RL, Martin RF. Options and strategies for the management of choledocholithiasis. *World J Surg*. 1998;22(11):1125-1132. doi:10.1007/s002689900531
7. Williams E, Beckingham I, El Sayed G, et al. Updated guideline on the management of common bile duct stones (CBDS). *Gut*. 2017;66(5):765-782. doi:10.1136/gutjnl-2016-312317
8. Bencini L, Tommasi C, Manetti R, Farsi M. Modern approach to cholecysto-choledocholithiasis. *World J Gastrointest Endosc*. 2014;6(2):32-40. doi:10.4253/wjge.v6.i2.32
9. Easler JJ, Sherman S. Endoscopic Retrograde Cholangiopancreatography for the Management of Common Bile Duct Stones and Gallstone Pancreatitis. *Gastrointest Endosc Clin N Am*. 2015;25(4):657-675. doi:10.1016/j.giec.2015.06.005
10. Szary NM, Al-Kawas FH. Complications of endoscopic retrograde cholangiopancreatography: how to avoid and manage them. *Gastroenterol Hepatol (N Y)*. 2013;9(8):496-504.
11. Cianci P, Restini E. Management of cholelithiasis with choledocholithiasis: Endoscopic and surgical approaches. *World J Gastroenterol*. 2021;27(28):4536-4554. doi:10.3748/wjg.v27.i28.4536
12. Sanders DJ, Bomman S, Krishnamoorthi R, Kozarek RA. Endoscopic retrograde cholangiopancreatography: Current practice and future research. *World J Gastrointest Endosc*. 2021;13(8):260-274. doi:10.4253/wjge.v13.i8.260
13. Manes G, Paspatis G, Aabakken L, et al. Endoscopic management of common bile duct stones: European Society of Gastrointestinal Endoscopy (ESGE) guideline. *Endoscopy*. 2019;51(5):472-491. doi:10.1055/a-0862-0346
14. Zhou Y, Zha WZ, Wu XD, et al. Three modalities on management of choledocholithiasis: A prospective cohort study. *Int J Surg*. 2017;44:269-273. doi:10.1016/j.ijssu.2017.06.032

15. Zhu HY, Xu M, Shen HJ, et al. A meta-analysis of single-stage versus two-stage management for concomitant gallstones and common bile duct stones. *Clin Res Hepatol Gastroenterol*. 2015;39(5):584-593. doi:10.1016/j.clinre.2015.02.002
16. Lu J, Cheng Y, Xiong XZ, Lin YX, Wu SJ, Cheng NS. Two-stage vs single-stage management for concomitant gallstones and common bile duct stones. *World J Gastroenterol*. 2012;18(24):3156-3166. doi:10.3748/wjg.v18.i24.3156
17. Nagaraja V, Eslick GD, Cox MR. Systematic review and meta-analysis of minimally invasive techniques for the management of cholecysto-choledocholithiasis. *J Hepatobiliary Pancreat Sci*. 2014;21(12):896-901. doi:10.1002/jhbp.152
18. Yan Y, Sha Y, Yuan W, Yuan H, Zhu X, Wang B. One-stage versus two-stage management for acute cholecystitis associated with common bile duct stones: a retrospective cohort study. *Surg Endosc*. 2022;36(2):920-929. doi:10.1007/s00464-021-08349-6
19. Dong SQ, Singh TP, Zhao Q, Li JJ, Wang HL. Sphincterotomy plus balloon dilation versus sphincterotomy alone for choledocholithiasis: a meta-analysis. *Endoscopy*. 2019;51(8):763-771. doi:10.1055/a-0848-8271
20. Kenny R, Richardson J, McGlone ER, Reddy M, Khan OA. Laparoscopic common bile duct exploration versus pre or post-operative ERCP for common bile duct stones in patients undergoing cholecystectomy: is there any difference?. *Int J Surg*. 2014;12(9):989-993. doi:10.1016/j.ijso.2014.06.013
21. Sánchez A, Otaño N, Rodríguez O, Sánchez R, Benítez G, Schweitzer M. Laparoscopic common bile duct exploration four-task training model: construct validity. *JLS*. 2012;16(1):10-15. doi:10.4293/108680812X13291597715709
22. Memba R, González S, Coronado D, et al. Single-stage approach for the management of choledocholithiasis with concomitant cholelithiasis. Implementation of a protocol in a secondary hospital. *Surgeon*. 2019;17(6):351-359. doi:10.1016/j.surge.2018.12.001
23. Salama, A.F., Abd Ellatif, M.E., Abd Elaziz, H. *et al*. Preliminary experience with laparoscopic common bile duct exploration. *BMC Surg* **17**, 32 (2017). <https://doi.org/10.1186/s12893-017-0225-y>
24. Kim H, Shin SP, Hwang JW, Lee JW. Outcomes of laparoscopic common bile duct exploration (LCBDE) after failed endoscopic retrograde cholangiopancreatography versus primary LCBDE for managing cholecystocholedocholithiasis. *J Int Med Res*. 2020;48(10):300060520957560. doi:10.1177/0300060520957560
25. Wang Y, Huang Y, Shi C, et al. Efficacy and safety of laparoscopic common bile duct exploration via choledochotomy with primary closure for the management of acute cholangitis caused by common bile duct stones. *Surg Endosc*. 2022;36(7):4869-4877. doi:10.1007/s00464-021-08838-8
26. Zhang, Wj., Xu, Gf., Huang, Q. *et al*. Treatment of gallbladder stone with common bile duct stones in the laparoscopic era. *BMC Surg* **15**, 7 (2015). <https://doi.org/10.1186/1471-2482-15-7>

27. Al-Habbal Y, Reid I, Tiang T, et al. Retrospective comparative analysis of choledochoscopic bile duct exploration versus ERCP for bile duct stones. *Sci Rep.* 2020;10(1):14736. Published 2020 Sep 7. doi:10.1038/s41598-020-71731-2
28. Petelin JB. Laparoscopic common bile duct exploration. *Surg Endosc.* 2003;17(11):1705-1715. doi:10.1007/s00464-002-8917-4
29. Tanase A, Russell TB, Platt T, Griffiths EA, Aroori S; CholeS study group, West Midlands Research Collaborative. The single-stage management of bile duct stones is underutilised: A prospective multicentre cohort study with a literature review. *Ann Hepatobiliary Pancreat Surg.* 2022;26(4):333-338. doi:10.14701/ahbps.22-001
30. Ebner S, Rechner J, Beller S, Erhart K, Riegler FM, Szinicz G. Laparoscopic management of common bile duct stones. *Surg Endosc.* 2004;18(5):762-765. doi:10.1007/s00464-003-9029-5
31. Wu X, Yang Y, Dong P, et al. Primary closure versus T-tube drainage in laparoscopic common bile duct exploration: a meta-analysis of randomized clinical trials. *Langenbecks Arch Surg.* 2012;397(6):909-916. doi:10.1007/s00423-012-0962-4
32. Nie S, Fu S, Fang K. Comparison of one-stage treatment versus two-stage treatment for the management of patients with common bile duct stones: A meta-analysis. Vol. 10, *Frontiers in Surgery.* Frontiers Media S.A.; 2023. <https://doi.org/10.3389/fsurg.2023.1124955>
33. Pan L, Chen M, Ji L, et al. The Safety and Efficacy of Laparoscopic Common Bile Duct Exploration Combined with Cholecystectomy for the Management of Cholecysto-choledocholithiasis: An Up-to-date Meta-analysis. *Ann Surg.* 2018;268(2):247-253. doi:10.1097/SLA.0000000000002731
34. Prasson, P., Bai, X., Zhang, Q. *et al.* One-stage laproendoscopic procedure versus two-stage procedure in the management for gallstone disease and biliary duct calculi: a systemic review and meta-analysis. *Surg Endosc* **30**, 3582–3590 (2016). <https://doi.org/10.1007/s00464-015-4657-0>
35. Singh AN, Kilambi R. Single-stage laparoscopic common bile duct exploration and cholecystectomy versus two-stage endoscopic stone extraction followed by laparoscopic cholecystectomy for patients with gallbladder stones with common bile duct stones: systematic review and meta-analysis of randomized trials with trial sequential analysis. *Surg Endosc.* 2018;32(9):3763-3776. doi:10.1007/s00464-018-6170-8
36. Ghazal AH, Sorour MA, El-Riwini M, El-Bahrawy H. Single-step treatment of gall bladder and bile duct stones: a combined endoscopic-laparoscopic technique. *Int J Surg.* 2009;7(4):338-346. doi:10.1016/j.ijsu.2009.05.005
37. Elgeidie A, Atif E, Elebidy G. Intraoperative ERCP for management of cholecystocholedocholithiasis. *Surg Endosc.* 2017;31(2):809-816. doi:10.1007/s00464-016-5036-1
38. Jones M, Johnson M, Samourjian E, Schlauch K, Ozobia N. ERCP and laparoscopic cholecystectomy in a combined (one-step) procedure: a random comparison to the standard (two-step) procedure [published correction appears in *Surg Endosc.* 2013 Jun;27(6):1913. Slauch, Karen [corrected to Schlauch, Karen]]. *Surg Endosc.* 2013;27(6):1907-1912. doi:10.1007/s00464-012-2647-z

39. Lin Y, Su Y, Yan J, Li X. Laparoendoscopic rendezvous versus ERCP followed by laparoscopic cholecystectomy in the management of cholecystocholedocholithiasis: a systemic review and meta-analysis. *Surg Endosc.* 2020;34(9):4214-4224. doi:10.1007/s00464-020-07698-y
40. Liao Y, Cai Q, Zhang X, Li F. Single-stage intraoperative ERCP combined with laparoscopic cholecystectomy versus preoperative ERCP Followed by laparoscopic cholecystectomy in the management of cholecystocholedocholithiasis: A meta-analysis of randomized trials. *Medicine (Baltimore).* 2022;101(10):e29002. Published 2022 Mar 11. doi:10.1097/MD.00000000000029002
41. Poh BR, Ho SP, Sritharan M, et al. Randomized clinical trial of intraoperative endoscopic retrograde cholangiopancreatography versus laparoscopic bile duct exploration in patients with choledocholithiasis. *Br J Surg.* 2016;103(9):1117-1124. doi:10.1002/bjs.10207
42. Muhammedoğlu B, Kale IT. Comparison of the safety and efficacy of single-stage endoscopic retrograde cholangiopancreatography plus laparoscopic cholecystectomy versus two-stage ERCP followed by laparoscopic cholecystectomy six-to-eight weeks later: A randomized controlled trial. *Int J Surg.* 2020;76:37-44. doi:10.1016/j.ijsu.2020.02.021
43. March B, Burnett D, Gani J. Single-stage laparoscopic cholecystectomy and intraoperative endoscopic retrograde cholangiopancreatography: is this strategy feasible in Australia? Vol. 86, ANZ Journal of Surgery. Blackwell Publishing; 2016. p. 874–7. <https://doi.org/10.1111/ans.13676>
44. ElGeidie AA. Single-session minimally invasive management of common bile duct stones. *World J Gastroenterol.* 2014;20(41):15144-15152. doi:10.3748/wjg.v20.i41.15144
45. Baloyiannis I, Tzovaras G. Current status of laparoendoscopic rendezvous in the treatment of cholelithiasis with concomitant choledocholithiasis. *World J Gastrointest Endosc.* 2015;7(7):714-719. doi:10.4253/wjge.v7.i7.714