

Clinico-Hematological Effects of Nanosilver Administration in Wistar Rats

ABSTRACT

This study evaluated the haematological effects of the oral administration of silver nanoparticle in Wistar rats. A total of 35 rats of six weeks of age, of either sex, were randomly divided into two groups. Group 1 was kept as control and comprised of 20 rats. Group II comprised of 15 rats and the rats were orally administered silver nanoparticle mixed in distilled water at no-observed-adverse-effect level (NOAEL) dose rate of 30 mg/kg body weight/day daily for 90 days of experiment. Blood was collected from 5 rats from each group at 0, 30th, 60th and 90th days post-treatment. A traditional Manual method was used to measure Hematological parameters and data analyzed by one-way ANOVA (post hoc Dunnett's test). The hematological parameters studied were significantly altered in treatment group as compared to control animals. Morphology of erythrocytes indicates normocytic hypochromic anaemia. Our results indicated that the silver nanoparticles have adverse effects on general clinical condition and hematological parameters of rats at NOAEL dose.

Key words: Hematological parameters, Nanosilver, NOAEL dose, Wistar rats.

INTRODUCTION

Nanotechnology is one of the most fascinating fields of science and technology in the 21st century. Nanotechnology is expanding as a rapidly rising field with its application in science and technology aimed at developing innovative materials on the nanoscale (Albrecht *et al.*, 2006). Many metals and alloys of metals have been used as effective medicines to cure various diseases. Nanotechnology has provided us with solutions for early disease detection and cure of diseases such as cancer and metabolic disorders (Sanhai *et al.*, 2008). The popularity of nanotechnology is increasing due to its positive benefits, but there are certain serious concerns about its possible health risks (Ema *et al.*, 2010). Toxicities linked with NPs are not limited to industrial or medicinal uses (Bahadur *et al.*, 2016). Water, soil, and air are all pathways through which NPs infiltrate the environment when humans engage in various activities. In addition, studies have shown that NPs

can enter organisms by ingestion or inhalation and can travel throughout the body to numerous organs and tissues where they can exert reactive toxicological effects.

Silver nanoparticles (AgNPs) have risen to the top of the list of engineered nanoparticles developed owing to their possible commercial applications (Natsukiet *al.*, 2015). Due to their distinct physical and chemical characteristics, AgNPs are being employed more often in a variety of industries, including those involving food, medicine, consumer goods, and industry. Silver (particularly in the form of soluble silver compounds) has toxic effects in both animals and humans, in addition to its antibacterial properties. In humans, acute symptoms of silver ion overexposure include gastrointestinal damage, abdominal pain, diarrhoea, and convulsions (Skalska and Strużyńska, 2015). Argyria has been documented in people working in the silver mining, manufacturing, or packaging industries (Al-Gurabiet *al.*, 2015). Furthermore, animal studies have shown that chronic low-dose administration of silver ions causes silver granule accumulation in the eyes, heart enlargement, anaemia, and pathological changes in the liver and kidneys (Drake and Hazelwood, 2005). Keeping in view the above facts, the present study was planned to evaluate the effects of nanosilver administration on general health and hematological parameters in Wistar rats at no-observed-adverse-effect level (NOAEL) dose.

MATERIALS AND METHODS

Thirty five Wistar rats of either sex, six week old, were procured from Indian Veterinary Research Institute, Bareilly, India. The rats were kept under standard managemental conditions. All the rats were acclimatized for a period of seven days prior to experiment. Rats were randomly divided in two groups, group I with 20 rats as control group and group II with 15 rats as treatment group. The silver nanoparticles used in this study were having aerodynamic particle size of less than 90 nm and molecular weight is 107.87. The silver nanoparticles, as silver nitrate, were homogenized by sonication just prior to administration and were gavaged once daily for 90 days, at the NOAEL dose of 30mg/kg body weight/day (Kim *et al.*, 2010). Rats of both the groups were observed daily for development of any untoward clinical signs, change in behaviour and mortality throughout the period of experimentation. Blood samples were collected from 5 rats of each group (control and treated) at 0, 30th, 60th and 90th day post-treatment (DPT) in EDTA vials as per standard protocol and haematological parameters were studied (Benjamin, 1997). The data was analysed by using standard statistical procedure (Snedecor and Cochran, 1994).

RESULTS AND DISCUSSION

Clinical Signs and Body Weight

No apparent clinical signs were present in the control rats throughout the period of experiment. In silver nanoparticle treatment, most of rats were dull, lethargic and anorectic. Mean body weights (gm) of the rats from both the groups measured at different time intervals. The weights of the rats treated with silver nanoparticles increased according to duration of study but when compared with control animals there was a significant decrease in their body weight (Table 1). There was gradual and significant increase in mean body weight in group I rats at 30th, 60th and 90th day of experiment. The nanosilver administration produced significant changes in the body weight of the rats when administered at NOAEL dose. Similar changes were also observed by Sulaiman *et al.* (2015) and De Jong *et al.* (2013) in rats. This might be one of the symptoms of toxic events consequent upon the exposure to silver nanoparticles.

Haematological Findings

The effect of nanosilver administration on haematological parameters of rats is presented in Table 1. The nanosilver administration has significant effects on haematological parameters. The level of Hb, PCV, TEC, Lymphocytes and absolute lymphocyte count (ALC) decreased significantly, whereas other parameters TLC, neutrophil, monocyte MCV, MCH, MCHC, and absolute neutrophil count (ANC) increased significantly. Laloy *et al.* (2014) and AL-Baker *et al.* (2020) also reported similar observations in humans and rats, respectively. The decrease in haemoglobin values might be due to hypochromic anaemia, which is also evident by the morphology of the RBCs in the present study. Our observation on PCV corroborates with the reports of De Jong *et al.* (2013) and AL-Baker *et al.* (2020).

There was a significant decrease in mean TEC values at 60th and 90th day in treatment group as compared to control. Similar findings have also been reported by Valiet *et al.* (2020) in common carp fish, where high dose exposure of nanosilver shown to cause blood toxicity. The reduced TEC values may be due to interaction of silver nanoparticles with blood cells, leading to destruction of membrane and thus causing blood toxicity (Choi *et al.*, 2010). The nanosilver toxicity generates ROS, which causes damage of essential cellular molecules like DNA and results in apoptosis of the affected cells followed by anaemia due to diminished life span of red blood cells (Luca *et al.*, 2007). Several authors have suggested that silver nanoparticles link

themselves to sulfur and phosphorus containing biomolecules like DNA or other biological moieties and that cause cell toxicity (George *et al.*, 2012). AL-Baker *et al.* (2020) reported similar decrease in TEC. There was significant increase in mean TLC values at 60th and 90th day in treatment group as compared to control. The nanostructure can induce immune response by increasing the TLC count. The increase in TLC after exposure was possibly due to an increase in immunogenic response (Duffinet *et al.*, 2007; Verma *et al.*, 2020). These findings are in confirmation with the findings of earlier studies where silver nanoparticle administration significantly increased the TLC count (Attai, 2016).

Mean values of neutrophil and monocyte count were significant increased in treatment group as compared to control animals at 30th, 60th and 90th DPT, whereas lymphocyte was significantly decreased at 30th, 60th and 90th DPT, in group II as compared to group I. When silver nanoparticles enter the body, the immune system considers them as foreign particle and shows an immediate response (Shin *et al.*, 2007). This results in increase in WBC. These observations are in accordance with previous studies by Tiwari *et al.* (2011). Neutrophils act as first line of defense against drugs or chemicals. The increase in neutrophil count might be due to increase in immune response produced by silver nanoparticles.

There was significant increase in mean MCV and MCH value at 60th and 90th DPT in group II rats as compared to group I. There was no significant difference in mean MCHC value at any time interval in group II as compared to group I. The results of present study are in agreement with those of AL-Baker *et al.* (2020).

Absolute Neutrophils and Lymphocyte Count (ANC, ALC)

There was significant increase in mean ANC values at 60th and 90th DPT, in treated group as compared to control. Singh and Sharma (2004) and Ibrahim and Harabawy (2015) also reported that heavy metals exposure induced changes in differential count of white blood cells and caused lymphocytosis, neutrophilia in *Clarias gariepinus* and *Anabas testudineus* fish.

Mean values of ALC were significantly decreased at 60th and 90th DPT in group II rats as compared to group I rats. The decrease in total lymphocyte count might be attributed to cytotoxic effect on lymphocyte. The increase in neutrophil count might be attributed to their compensatory increase against the lymphocyte count. The decrease of ALC might be due to the malfunctioning of the hematopoietic system caused by exposure to silver nanoparticles causing stress

(Abarghoeiet *al.*, 2016). Similar observations were also made by Cheraghiet *al.* (2013) in silver nanoparticles exposed Wistar rats.

Total Thrombocyte Count (TTC)

There was significant increase in mean TTC value at 90th DPT in group II as compared to control group I. The thrombocytes count measures the adequacy of thrombocytes numbers to provide initial hemostasis. AL-Baker *et al.* (2020), reported that 561×10^3 total thrombocyte count. It is similar to our result. Thrombocytes have important role in coagulation of blood, so the increase in platelets counts lead to intravascular thrombus formation, which is also evident from the histopathological examination of liver of treated group that revealed presence of thrombus in the blood vessel of liver (Kumar, 2021).

Morphology of Erythrocytes

The peripheral blood smear of group II rats showed normocytic hypochromic anaemia with increased central pallor area within the erythrocyte (stomatocytes) at 60th and 90th DPT (Fig. 1). These alterations in morphology of erythrocytes may indicate the effect of the nanoparticles on haemoglobin synthesis during erythrocytes maturation in the bone marrow. The abnormal morphology of BCRs occur due to disturbances in function of bone marrow which caused by pathological processes of this will lead to formation of macrocytic RBC (Guyton and Hall, 2000).

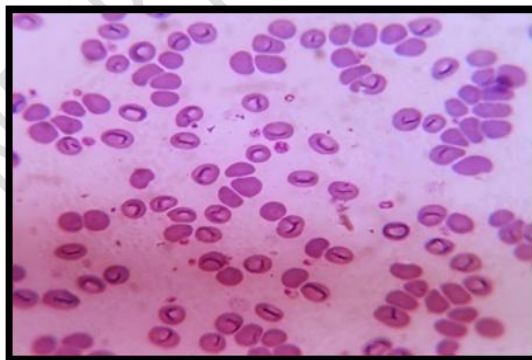


Fig. 1: Blood smear of rat treated with silver nanoparticles showing stomatocytes at 90th day post-treatment (Giemsa stain, x 100)

CONCLUSION

Nano-silver treatment significantly altersthe body weight and haematological parameters of Wistarrats. However, this study is evidence indicating that nanosilver has adverse effects on general health in Wistar rats at NOAEL dose for a period of 90 days.

Ethical Approval

Before commencing the study, permission from IAEC (Institutional animal ethics committee) was taken for this experiment.

REFERENCES

- Abarghoei, S., Hedayati, A., Ghorbani, R., Miandareh, H.K., &Bagheri, T. (2016). Histopathological effects of waterborne silver nanoparticles and silver salt on the gills and liver of goldfish *Carassiusauratus*. *International Journal of Plasma Environmental Sciences*,13(7), 1753-1760.
- Al-Gurabi, M.A., Ali, D., Alkahtani, S., &Alarifi, S. (2015). *In vivo* DNA damaging and apoptotic potential of silver nanoparticles in Swiss albino mice. *OncoTargets and Therapy*, 8, 295-302.
- Al-Baker, A., Al-Kshab, A.A., & Ismail, H.K. (2020). Effect of silver nanoparticles on some blood parameters in rats. *Iraqi Journal of Veterinary Sciences*, 34(2), 389-395.
- Albrecht, M.A., Evan, C.W., &Raston, C.L. (2006). Green chemistry and the health implications of nanoparticles. *Green Chemistry*, 8(5), 417-432.
- Attaei, F. (2016). Blood toxicity of silver nanoparticles in pregnant Wistar rats. *Iranian Journal of Pediatric Hematology and Oncology*, 7(4), 124-128.
- Bahadar, H., Maqbool, F., Niaz, K.,& Abdollahi, M.(2016). Toxicity of nanoparticles and an overview of current experimental models. *Iranian Biomedical Journal*, 20(1), 1-11.
- Benjamin, M.M. (1997). *Outline of Veterinary Clinical Pathology*. 3rdedition. Kalyani Publications, New Delhi, India, pp 54-56.
- Cheraghi, J., Hosseini, E., Hoshmandfar, R.,&Sahraei, R. (2013). Hematologic parameters study of male and female rats administrated with different concentrations of silver nanoparticles. *International Journal of Agriculture and Crop Sciences*, 5(7), 789-796.
- Choi, J.E., Kim, S., Ahn, J.H., Youn, P., Kang, J.S., Park, K.,&Ryu, D.Y. (2010). Induction of oxidative stress and apoptosis by silver nanoparticles in the liver of adult zebrafish. *Aquatic Toxicology*, 100(2), 151-159.
- De Jong, W.H., Van Der Ven, L.T., Sleijffers, A., Park, M.V., Jansen, E.H., Van Loveren, H.,&Vandebriel, R.J. (2013). Systemic and immunotoxicity of silver nanoparticles in an intravenous 28 days repeated dose toxicity study in rats. *Biomaterials*, 34(33), 8333-8343.

- Drake, P.L., & Hazelwood, K.J. (2005). Exposure-related health effects of silver and silver compounds: a review. *Annals of Occupational Hygiene*, 49 (7), 575-585.
- Duffin, R., Tran, L., Brown, D., Stone, V., & Donaldson, K. (2007). Proinflammatory effects of low-toxicity and metal nanoparticles *in vivo* and *in vitro*: Highlighting the role of particle surface area and surface reactivity. *Inhalation Toxicology*, 19(10), 849-856.
- Ema, M., Kobayashi, N., Naya, M., Hanai, S., & Nakanishi, J. (2010). Reproductive and developmental toxicity studies of manufactured nanomaterials. *Journal of Reproductive Toxicology*, 30(3), 343-352.
- George, T.I., Etzell, J.E., Bradley, K.T., Clarke, M.R., Crossey, M.J., Davis, B.H., & Salansky, S. (2012). *Hematology, Clinical Microscopy, and Body Fluids Glossary*. College of American Pathologists, USA, pp.1-64.
- Guyton, C.A., & Hall, J.E. (2000). *Textbook of Medical Physiology*. 10th edn. London: Academic Press, pp. 730-801.
- Ibrahim, A.T.A., & Harabawy, A.S. (2015). The ability of vitamin E, selenium and water to improve and recover the hematological, biochemical and hormonal parameters of mercury-exposed catfish *Clarias gariepinus* (Burchell, 1822). *Egyptian Academic Journal of Biology*, 7(2), 1-19.
- Kim, Y.S., Song, M.Y., Park, J.D., Song, K.S., Ryu, H.R., Chung, Y.H., & Yu, I.J. (2010). Subchronic oral toxicity of silver nanoparticles. *Particle and Fibre Toxicology*, 7(1), 1-11.
- Kumar, N. (2021). Clinicopathological studies on nanosilver administered Wistar rats. *MVSc Thesis*. GB Pant University of Agriculture and Technology, Pantnagar, India.
- Laloy, J., Minet, V., Alpan, L., Mullier, F., Beken, S., Toussaint, O., & Dogné, J.M. (2014). Impact of silver nanoparticles on haemolysis, platelet function and coagulation. *Journal of Nanomedicine*, 4(1), 4.
- Luca, G., Gugliotta, T., Parisi, G., Romano, P., Geraci, A., Romano, O., & Romano, L. (2007). Effects of nickel on human and fish red blood cells. *Bioscience Reports*, 27(4-5), 265-273.
- Natsuki, J., Natsuki, T., & Hashimoto, Y. (2015). A review of silver nanoparticles: synthesis methods, properties, and applications. *International Journal of Materials Applications*, 4(5), 325-332.
- Sanhai, W.R., Sakamoto, J.H., Canady, R., & Ferrari, M. (2008). Seven challenges for nanomedicine. *Journal of National Nanotechnology*, 3(5), 242-244.
- Shin, S.H., Ye, M.K., Kim, H.S., & Kang, H.S. (2007). The effects of nanosilver on the proliferation and cytokine expression by peripheral blood mononuclear cells. *International Immunopharmacology*, 7, 1813-1818.

- Singh, R.K., & Sharma, B. (2004). *In vivo* alteration in protein metabolism by subacute carbafuran intoxication in the freshwater teleost, *Clarias batrachus*. *Bulletin of Environmental Contamination and Toxicology*, 73(5), 919-926.
- Skalska, J., & Strużyńska, L. (2015). Toxic effects of silver nanoparticles in mammals does a risk of neurotoxicity exist. *Folia Neuropathologica*, 53(4), 281-300.
- Snedecor, G.W., & Cochran, W.G. (1994). *Statistical Methods*, 8th edn., The Iowa State University Press, Ames, Iowa, USA. 507 p.
- Sulaiman, F.A., Adeyemi, O.S., Akanji, M.A., Oloyede, H.O.B., Sulaiman, A.A., Olatunde, A., & Salawu, M.O. (2015). Biochemical and morphological alterations caused by silver nanoparticles in Wistar rats. *Journal of Acute Medicine*, 5(4), 96-102.
- Tiwari, D.K., Jin, T., & Behari, J. (2011). Dose-dependent in-vivo toxicity assessment of silver nanoparticle in Wistar rats. *Toxicology Mechanisms and Methods*, 21(1), 13-24.
- Vali, S., Mohammadi, G., Tavabe, K. R., Moghadas, F., & Naserabad, S.S. (2020). The effects of silver nanoparticles (Ag-NPs) sublethal concentrations on common carp (*Cyprinus carpio*): Bioaccumulation, hematology, serum biochemistry and immunology, antioxidant enzymes, and skin mucosal responses. *Ecotoxicology and Environmental Safety*, 194, 110353.
- Verma, M. K., Ahmad, A. H., Pant, D., Rawat, P., & Kumar, N. (2020). Ameliorative effect of *Chenopodium album* in cyclophosphamide-induced oxidative stress and hematologic toxicity. *Pharma Innovation*, 9(12), 402-406.

Table 1: Mean body weight and haematological parameters in different groups of rats at different time interval of the experiment

Parameters studied	Days Post-Treatment							
	0 Day		30 th Day		60 th Day		90 th Day	
	Group I	Group II	Group I	Group II	Group I	Group II	Group I	Group II
Body weight(g)	217.0±1.54 ^{Aa}	217.0±1.54 ^{Aa}	237.6±4.58 ^{Bb}	235±6.32 ^{Cb}	245.4±4.81 ^{Dc}	238.2±4.49 ^{Ec}	259.2±6.70 ^{Fd}	243.6±6.31 ^{Gd}
Hb (g/dL)	12.32±0.34 ^{Aa}	12.32±0.34 ^{Aa}	12.94±0.34 ^{Ba}	13.6±0.50 ^{Ba}	13.36±0.19 ^{Ca}	12.64±0.45 ^{Ca}	14.04±0.37 ^{Da}	10.98±0.26 ^{Eb}
PCV(%)	38.2±0.96 ^{Aa}	38.2±0.96 ^{Aa}	39.4±2.18 ^{Ba}	40.8±1.15 ^{Ba}	41.6±0.50 ^{Ca}	31.76±5.05 ^{Db}	40.2±0.86 ^{Ea}	33.4±1.32 ^{Fc}
TLC (10 ³ /μL)	12.24±0.98 ^{Aa}	12.24±0.98 ^{Aa}	13.08±0.52 ^{Ba}	14.64±0.49 ^{Bb}	12.26±0.26 ^{Ca}	13.16±0.50 ^{Da}	13.24±0.37 ^{Ea}	14.70±0.36 ^{Fa}
TEC (10 ⁶ /μL)	8.48±0.270 ^{Aa}	8.4±0.27 ^{Aa}	8.76±0.30 ^{Ba}	8.5±0.74 ^{Ba}	8.74±0.27 ^{Ca}	7.6±1.06 ^{Db}	7.24±0.34 ^{Ea}	6.7±0.46 ^{Fc}
Neutrophil (%)	19.0±1.30 ^{Aa}	19.0±1.30 ^{Aa}	20.2±3.13 ^{Ba}	22.0±1.58 ^{Cb}	20.6±1.72 ^{Da}	24.0±1.87 ^{Ec}	19.8±2.70 ^{Fa}	25.4±3.14 ^{Ga}
Lymphocyte (%)	72.8±1.06 ^{Aa}	72.8±1.06 ^{Aa}	74.0±1.97 ^{Ba}	72.2±1.77 ^{Ca}	74.80±1.63 ^{Da}	68.8±1.59 ^{Ec}	72.40±2.76 ^{Fa}	67.0±3.016 ^{Gd}
Monocyte (%)	4.6±0.40 ^{Aa}	4.6±0.40 ^{Aa}	2.6±0.67 ^{Bb}	3.0±0.70 ^{Bb}	3.8±0.37 ^{Cc}	2.8±0.58 ^{Dc}	4.8±0.37 ^{Ea}	3.6±0.50 ^{Fa}
MCV (fL)	45.25±2.09 ^{Aa}	45.25±2.09 ^{Aa}	45.20±3.22 ^{Ba}	46.42±4.47 ^{Ba}	47.76±1.86 ^{Ca}	51.64±4.50 ^{Da}	44.6±2.04 ^{Ea}	51.66±3.60 ^{Fb}
MCH (pg)	14.54±0.67 ^{Aa}	14.54±0.67 ^{Aa}	14.76±0.49 ^{Ba}	16.54±1.68 ^{Ba}	15.32±0.65 ^{Ca}	17.66±1.98 ^{Db}	15.54±0.53 ^{Ea}	16.52±1.29 ^{Fa}
MCHC (%)	32.25±0.84 ^{Aa}	32.25±0.84 ^{Aa}	33.20±1.92 ^{Ba}	33.32±0.85 ^{Ba}	32.08±0.25 ^{Ca}	33.84±1.24 ^{Ca}	33.96±0.84 ^{Da}	32.00±0.89 ^{Da}
ANC (10 ³ /μL)	2.29±0.15 ^{Aa}	2.29±0.15 ^{Aa}	2.52±0.33 ^{Ba}	3.08±0.20 ^{Ba}	2.53±0.23 ^{Ca}	3.13±0.31 ^{Db}	2.56±0.34 ^{Ea}	3.70±0.52 ^{Fa}
ALC (10 ³ /μL)	8.90±0.75 ^{Aa}	8.90±0.75 ^{Aa}	9.06±0.63 ^{Ba}	8.10±0.33 ^{Ba}	9.12±0.29 ^{Ca}	7.39±0.45 ^{Db}	9.50±0.45 ^{Ea}	7.18±0.45 ^{Fc}
TTC (10 ³ /μL)	560.2±64.86 ^{Aa}	560.2±64.86 ^{Aa}	599.8±35.1 ^{Ba}	588.8±32.65 ^{Ba}	674.4±19.0 ^{Ca}	664.8±58.1 ^{Ca}	688.4±45.55 ^{Da}	788.4±59.3 ^{Eb}

*Alphabetical letters (A, B, C, D, E, F and G) indicate significant (P<0.05) difference between groups at a particular DPT (Day Post-Treatment), whereas different alphabetical letters (a, b and c) indicate significant (P<0.05) difference within day in a particular group.