

From Dormant Debris to danger: Unveiling spilled Gallstones intriguing Transformation into Preperitoneal Abscess

ABSTRACT

Background:

Laparoscopic cholecystectomy is one of the most commonly performed surgery worldwide. Gall Stone spillage during surgery can occur either due to perforation of the gall bladder or during Gall bladder extraction from the port. We are presenting a case of unusual port site complication following laparoscopic cholecystectomy.

Case Summary:

A 42-year-old gentleman, presented with complaints of swelling in the upper abdomen for 6 months, not associated with any other symptoms. Past h/o Cholecystectomy 5 years back. O/E Previous laparoscopic port site scar completely healed well, palpable cystic intra abdominal mass above the umbilicus, freely mobile in all directions which was non-tender. On further evaluation with an Ultrasound and Contrast-enhanced Computed Tomography scan (CECT) of the abdomen diagnosed as intra-peritoneal cyst. The decision was made to proceed with Laparoscopic excision. Intra operatively, the cyst was arising from the preperitoneal space of the anterior abdominal wall, containing pus and retained Gall stone.

Conclusion:

Most of the patients with retained gallstones remains asymptomatic, they can present at any time with variable symptoms. This can be prevented by avoiding Gall bladder perforation and the use of an endo bag for gall bladder retrieval from the port.

Key words – Retained Gallstones, port site abscess, laparoscopic cholecystectomy, spilled gallstones.

1. INTRODUCTION

Laparoscopic cholecystectomy is the procedure of choice for patients with gall stones having symptoms. Spillage of stones occur due to perforation of the gall bladder either during the surgery or while retrieving the gall bladder without endo bag. These lost stones can lead to subsequent complications like adhesion, abscess or

fistula formation. We hereby present a rare, unusual case of pre peritoneal anterior abdominal wall abscess secondary to retained gall stones.

2. PRESENTATION OF CASE

We present a 42-year-old gentleman who underwent cholecystectomy 5 years ago with complaints of swelling in the upper abdomen for 6 months. He noticed the swelling incidentally and there was no increase in size since the time of onset. He did not have any gastrointestinal symptoms or fever.

His clinical examination revealed a palpable mass of 7 x 7 cm at supra umbilical region with ill-defined margins and restricted mobility in all directions. On further evaluation with ultrasound scan of the abdomen showed, well defined midline supra umbilical cystic lesion of 62 x 52 x 44.4 mm, in front of aorta having an echogenic structure with posterior acoustic shadow. He underwent cross sectional imaging with CECT scan which showed a well-defined intra peritoneal cyst with a peripheral calcified mural nodule measuring 50 x 61 x 57 mm (anterior-posterior x cephalo-caudal x medio-lateral) and there was no communication with any major vessel (fig -1). The diagnose that was considered based on the imaging was intraperitoneal cyst.

After having detailed discussion with the patient and family, we proceeded with the laparoscopic excision of the intra peritoneal cyst.

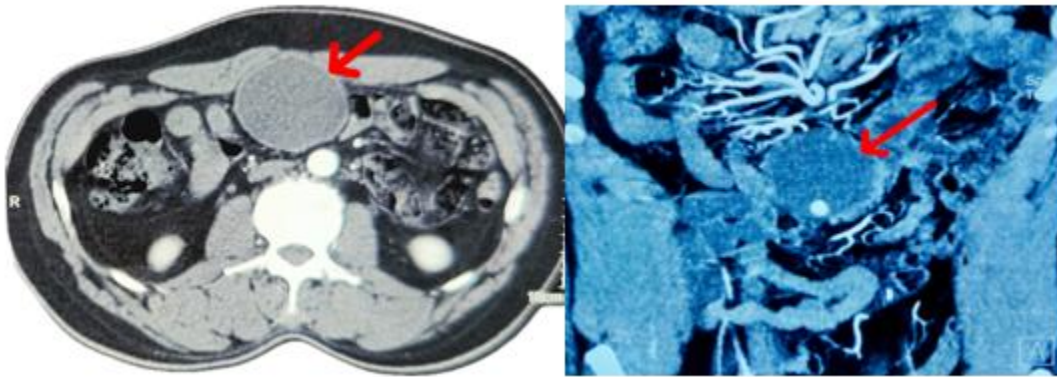


Figure 1 – CECT image depict as intraperitoneal cyst with calcified mural nodule

Under general anesthesia, the patient was in the supine. After standard preoperative maneuvers, Veress needle was inserted at the palmar's point and pneumoperitoneum was created. A 10-mm camera port was inserted 3 cm below the umbilicus (fig-2). Diagnostic laparoscopy was done and found to have the cystic swelling arising from the anterior abdominal wall (fig-2) with omental adhesion to the cyst wall. A 5-mm working port was inserted in the palmar's point and one more in left mid-clavicular line at the level of 10 mm port. Adhesiolysis done by sharp dissection with diathermy. The peritoneum of anterior abdominal wall incised 3 cm from the cyst wall and dissection continued. The cyst was freed from the rectus muscle, and it was preperitoneal space of origin (fig-3). The cyst was completely excised, and specimen retrieved in a bag. It contained a retained gall stones with pus (fig-4). The patient recovered well postoperatively and discharged on the Post operative day 1. On follow-up patients was doing well.

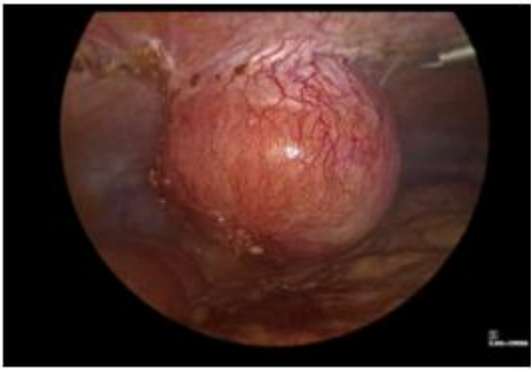

Figure 2 – Cystic swelling arising from anterior abdominal wall.

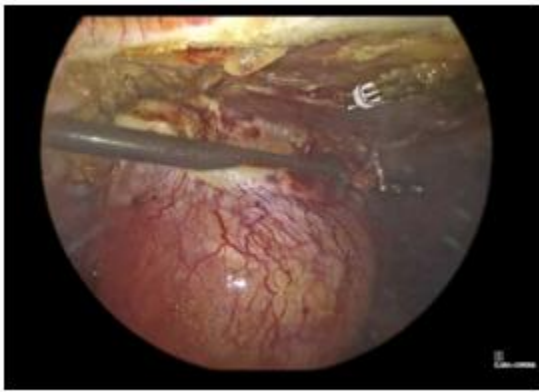

Figure 3 – Cyst is free from the rectus muscle and origin from preperitoneal space.

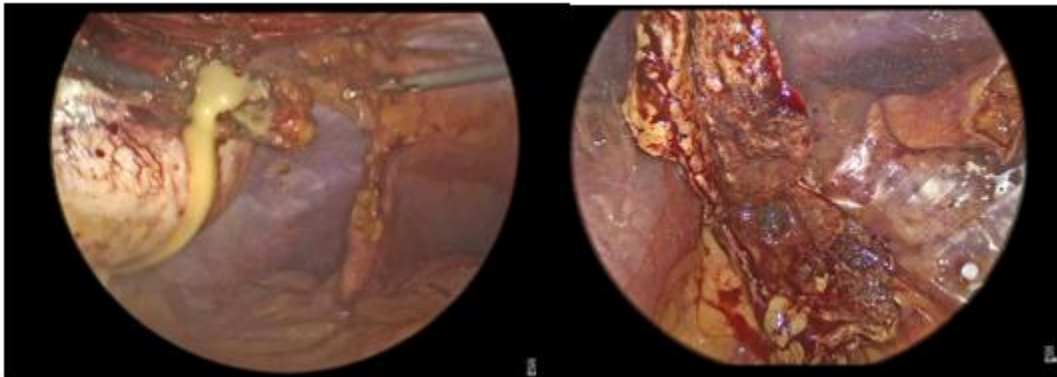

Figure 4 - containing pus and retained gall stone.

3. DISCUSSION

Gall stones spillage during laparoscopic cholecystectomy is a common problem. In a review article by Woodfield et al, the incidence of gall stones spillage during laparoscopic cholecystectomy was 7.3% and in 2.4% of the patients the stones are not fully retrieved (1). These spilled stones can result in complications like abscess, fistula formation or systemic sepsis. However, the incidence of these complications are extremely rare, with incidences ranging from 0.08% to 5% (2).

Nooghabi et al. in his review article mentioned that the risk factors for increased incidence of retained stones and bile spillage during laparoscopic cholecystectomy were inflamed gall bladder, old age patients, obesity, male gender and also the presence of the extensive adhesions (3). These factors increase the risk of the iatrogenic gallbladder perforation. The spillage of the gall stones can also occur during the specimen extraction from the port site. This can be prevented with the use of an Endo bag. Use of endo bag can also avoid the contamination and the retention of the stones at the port site (4). Any stone spillage that occurs during the dissection or the retrieval of the specimen should be removed completely, and it is advised also to irrigate the port site to cleanse it.

Sometimes it's impossible to locate all spilled gall stones, and also difficult to predict how the patients may present with subsequent complications. The clinical presentation varies from being asymptomatic to minor nonspecific abdominal symptoms and rarely they can have sepsis secondary to the infection (5).

Grass et al. in their case report, described a patient presented with the periumbilical swelling at previous laparoscopic cholecystectomy at port site. On evaluation with imaging, confirmed a retained stone with collection at the umbilical port site which was managed surgically by extraction of the stones and the drainage of the abscess (6). In another case report by Faisal Syed et al. described a case of 58-year-old male presented as lump in the right upper quadrant after 8 years of laparoscopic cholecystectomy and on further evaluation found to have intramuscular abscess secondary to gallstones (7).

Roy huynh et al. reported a 17-year-old female with history of laparoscopic cholecystectomy 3 months ago presented with a painful peri umbilical mass. Her operative notes revealed a difficult in the retrieval of the endobag from the umbilical port site. On further imaging with CECT abdomen, an intra abdominal collection communicating with umbilicus. On diagnostic laparoscopy, findings were pus in the peritoneal cavity with the retained gallbladder containing gallstones. Extraction of the retained gall bladder with gallstones, followed by the peritoneal lavage was performed (8).

Reuban et al. in their case report a 67-year-old female underwent percutaneous cholecystostomy for Septic shock with severe acute cholecystitis. 8 weeks later she underwent an interval laparoscopic subtotal cholecystectomy. In the post operative care, she developed an intra abdominal abscess, which required the Ultrasonography guided placement of percutaneous drain. 5 days after the removal of drain, she presented with an abscess in the right abdominal wall. A CT scan revealed a Retained gall stones in the abdominal wall. It was Managed by Incision and drainage of abscess with the extraction of the gall stones (9).

In the literature, patients presented with symptoms due to retained gallstone vary from 5 months to 20 years after laparoscopic cholecystectomy, without any specific time interval. A high index of suspicion is required in patients who present with cystic swelling at the port site, persistent abdominal pain or intra-abdominal abscess following years after laparoscopic cholecystectomy (10). In patients who present late after the initial surgery, it can mimic other cystic lesions in imaging as happened in our case. We present this case to emphasize the importance of removal of gall bladder in bag which will reduce the chance of this potential complication.

4. CONCLUSION

Most of the patients with spilled gallstones remain asymptomatic. A small proportion of patients can present with abscess or fistula formation at a later date following laparoscopic cholecystectomy. These can be prevented by avoiding gall bladder perforation during dissection and the use of an endo bag for gall bladder retrieval from the port. Meticulous suction and irrigation with careful inspection for complete removal of spilled gall stones is essential to prevent this complication.

Highlights

- In most of the cases the retained gallstones remain asymptomatic.
- Patients' clinical presentation may vary from palpable mass to abdominal pain, months to year following laparoscopic cholecystectomy.
- Even with the CT scan, diagnosing a complication related to retained gallstones can be challenging in sometimes, as observed in our case.
- This can be prevented by use of Endobag for the retrieval of the gallbladder with stones, but care should be taken not to tear or rupture the endobag during retrieval.

CONSENT

As per international standards or university standards, patient(s) written consent has been collected and preserved by the author(s).

ETHICAL APPROVAL

As per international standards or university standards, written ethical approval has been collected and preserved by the authors.

REFERENCES

1. Woodfield JC, Rodgers M, Windsor JA. Peritoneal gallstones following laparoscopic cholecystectomy: incidence, complications, and management. Surg Endosc. 2004;18:1200–1207

2. Hand AA, Self ML, Dunn E. Abdominal wall abscess formation two years after laparoscopic cholecystectomy. *J Soc Laparoscop Robot Surg* 2006;10:105–7.
3. Nooghabi AJ, Hassanpour M, Jangjoo A. Consequences of lost gallstones during laparoscopic cholecystectomy: a review article. *Surg Laparoscopy Endoscopy Percutaneous Tech.* 2016; 26(3): 183–192.
4. Heywood S, Wagstaff B, Tait N. An unusual site of gallstones five years after laparoscopic cholecystectomy. *Internat J Surg Case Rep.* 2019; 56: 107–109.
5. Mehmood S, Singh S, Igwe C, Obasi CO, Thomas RL. Gallstone extraction from a back abscess resulting from spilled gallstones during laparoscopic cholecystectomy: a case report. *J Surg Case Rep* 2021;7:1–3.
6. Grass F, Fournier I, Bettschart V. Abdominal wall abscess after cholecystectomy. *BMC Res Notes.* 2015;8:334.
7. Faisal Syed, Gaik Si Quah, Angelina Di Re, Port site intramuscular abscess from retained gallstone post laparoscopic cholecystectomy – an unusual complication, *Journal of Surgical Case Reports*, Volume 2023, Issue 1, January 2023:rjac611.
8. Roy Huynh, Mark Magdy, Lucia Saliba, Ken Loi : Retained gallbladder secondary to retrieval bag rupture during laparoscopic cholecystectomy—A case report, *International Journal of Surgery Case Reports*, Volume 59, 2019, Pages 101-106, ISSN 2210-2612.
9. Reuban Toby D’cruz, Vishal G Shela :Ectopic retained gallstone causing an abdominal wall abscess; *Ann Hepatobiliary Pancreat Surg* 2019 May;23(2):197-9.
10. Gabrielle Perrotti, Paul O’Moore, Orlando Kirton ; Hey, you forgot something! The Management of Symptomatic Retained Gallstones, *Surgery in Practice and Science*, Volume 8, 2022, 100052, ISSN 2666-2620.