

Case study

‘ARARE CASE OF INTRA AND EXTRA PERITONEAL URINARY BLADDER RUPTURE FOLLOWING MOTOR VEHICLE ACCIDENT (MVA); OUR EXPERIENCE AND REVIEW OF LITERATURE.’

Abstract:

Introduction: Bladder injuries are uncommon (approximately 1.6% of blunt abdominal trauma victims). Signs that raise the index of suspicion for bladder rupture include gross hematuria, pelvic fracture, acute kidney injury and little to no urine output with catheterization. A static or computed tomography (CT) cystogram should be performed and can be used to diagnose bladder injury. American urological association (AUA) guidelines recommend that intraperitoneal bladder ruptures be surgically repaired and uncomplicated extraperitoneal bladder injuries be managed conservatively with catheter placement.

Case Report: We report a case of 24-year-old male, victim of MVA, brought by ambulance in an unconscious state, with GCS-3/15, nonrecordable pulse and BP, right testes eviscerated through right inguinal lacerated wound, after primary survey, physiological optimization through fluid resuscitation and immobilization by slabs to address pelvic, left tibial, left radial fractures done. Clinical signs raised suspicion of intra and extraperitoneal bladder rupture. Patient regained consciousness after initial resuscitation and prepared for exploration. Intraperitoneal as well as extraperitoneal rupture of urinary bladder repaired along with right orchidopexy. Course of the patient in surgical ward was uneventful followed by transfer to orthopedic unit for management of skeletal injuries after successful removal of all the drains and suprapubic catheter.

Discussion: Urinary bladder injury though uncommon of all blunt abdominal trauma cases when presented with classical signs and symptoms should be evaluated and be managed by multidisciplinary team approach to maximize the outcome, reducing morbidity and mortality related to all injuries either conservatively or surgically when indicated.

Conclusion: We present a rare case of intra and extraperitoneal urinary bladder rupture following MVA assessed, resuscitated, and managed surgically with uneventful postoperative recovery.

Introduction: Historically earliest cases of bladder rupture were documented in 1826 where mode of injury was polytrauma due to construction site accident in one case and hitting a fence post while moving with speed (foot race) in the other¹. Bladder injuries are uncommon approximately 1.6% of blunt abdominal trauma victims², approximately 60% are extraperitoneal and approximately 30% are intraperitoneal and the remaining are both intra and extra peritoneal³. Earlier studies have reported that bladder injury shares 0.36% of all blunt abdominal trauma cases⁴ out of which 80% were extraperitoneal 15% intraperitoneal and 5% both intra and extraperitoneal⁵. Patients with bladder injury often are victims of motor vehicle accidents (MVA) with suprapubic pain and guarding, gross haematuria, little to no urine on per urethral catheterisation, pelvic fracture and acute kidney injury. Mechanism of trauma is usually a high-energy force that disrupts the bony pelvis or a penetrating injury, (60% to 85% blunt trauma and 15% to 40% are from a penetrating injury). Some sports activities having high-velocity contact and collision, the most common being cycling and others like martial arts, softball, snowboarding, football, rugby, gymnastics, and hockey have capability to cause significant abdominal and subsequent bladder injury because of acceleration, deceleration, and spearing⁶. A static or computed tomography (CT) cystogram should be performed and can be used to diagnose bladder injury⁷. American urological association (AUA) guidelines recommend that intraperitoneal bladder ruptures be surgically repaired and uncomplicated extraperitoneal bladder injuries be managed conservatively with catheter placement⁷.

Case Report: We report a case of 24-year-old male, victim of MVA, brought by ambulance in an unconscious state, with GCS-3/15, nonrecordable pulse and BP, right testes eviscerated through right inguinal lacerated wound, left inguinal lacerated wound had a blood clot, after primary survey, physiological optimization through fluid resuscitation and immobilization by slabs to address pelvic, left tibial, left radial fractures done. Patient regained consciousness after initial resuscitation and had guarded abdomen, no urine output but only hemorrhagic drain on per urethral catheterization and acute kidney injury (serum creatinine-2.6), bilateral pubic rami fracture which raised suspicion of intra and extraperitoneal bladder rupture. Laboratory investigations revealed leukocytosis. After preoperative investigations patient was prepared for surgical exploration. Radiological investigation like Xray/CT cystogram was not possible. Intra operative findings (Fig 1) revealed intraperitoneal as well as extraperitoneal rupture of urinary bladder near the dome which we repaired surgically along with right orchidopexy. After the blood clot from the left inguinal lacerated wound dislodged,

we appreciated only the left pubic ramus fracture and no other injury to femoral vessels or spermatic cord. Drains were kept in situ in pouch of Douglas, preperitoneal space of Retzius, subcutaneously on bilateral inguinal region and a suprapubic urinary catheter. Patient was transferred to ICU for post operative observation, started on per oral liquids since post-op day-2, tolerated solid food after that, passed stools on post-op day-4, subsequent laboratory data showed improvement in parameters. Total length of stay in ICU was for 4 days then shifted to general ward. We had to change per urethral catheter several times due to urinary casts and UTI (Pus cells 30-40, RBCs 20-25, Bacteria- many) and for that reason suprapubic catheter was in situ for about 10 days in which it required multiple times bladder wash through both the catheters along with appropriate antibiotics coverage according to sensitivity. Peritoneal drain was removed on post-op day-3 and preperitoneal drain on post-op day-12, otherwise course of the patient in surgical ward was uneventful followed by transfer to orthopedic unit for management of skeletal injuries after successful removal of all the drains and suprapubic catheter. Patient was operated for left radial and left tibial fractures and managed conservatively for pelvic rami fractures. Per urethral catheter was removed after 3 weeks. Total length of hospital stay exceeded a month after that patient was discharged. On follow up for 3 months we did not encounter any complications.

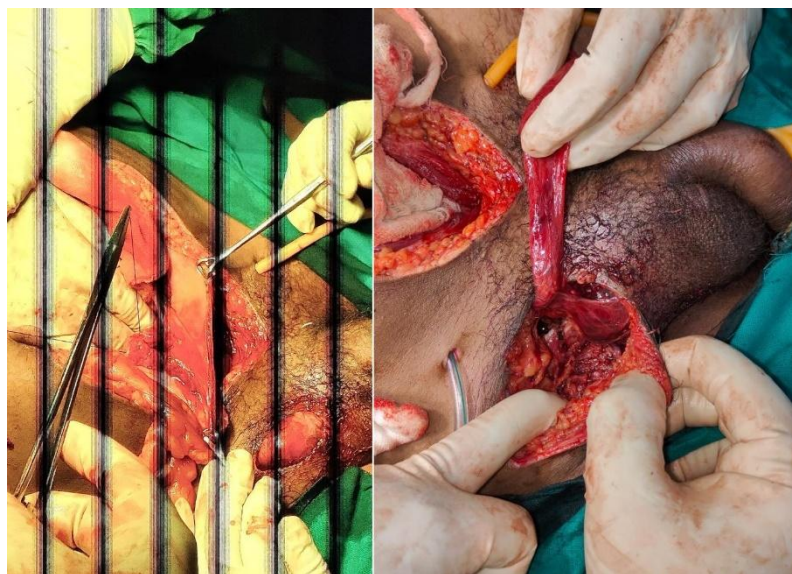


Fig 1; L: Intra operative picture showing intraperitoneal rent on bladder wall being repaired (peritoneum held by Babcock forceps). **R:** Lacerated wound in Right inguinal area showing right superior pubic ramus fracture, right testis being held by assistant (suprapubic catheter and preperitoneal drain in situ).

Discussion: Our patient was brought to ER by ambulance in an unconscious state without anyone who was accompanying the patient hence history and alleged mode of trauma was unknown. However, on careful physical examination and radiological assessment we were able to appreciate the above-mentioned significant injuries. Prompt resuscitation improved the condition and neurological state which allowed us to re assess and take a decision to proceed for further intervention. We acknowledge that availability of resources and integrated effort by other specialties would have helped a lot in planning and managing the case in a better way.

With respect to motor vehicle collisions, deceleration against seatbelt restraints represent a common injury mechanism. In these cases, the weak and mobile bladder dome ruptures, and remaining forces distribute throughout the abdomen, often causing multiorgan injury⁵. Urologic injury often occurs in context of multisystem trauma that requires close cooperation with trauma surgeons, however immediate interventions for acute urologic injuries often require flexibility in accordance with damage control principles in critical ill patients⁷. Clinical signs of bladder injury are relatively nonspecific; however, a triad of symptoms is often present: gross haematuria, suprapubic or abdominal pain or tenderness, and difficulty in voiding or inability to void⁶. Free urine in the abdomen and pelvis leads to acute renal failure and sepsis, which is responsible for mortality rates over 20% when not promptly identified⁸. FAST scan can identify free fluid in the pelvis⁹ but as it does not differentiate between fluid and blood both Xray and CT cystography are highly sensitive and specific available for the diagnosis or exclusion of bladder rupture^{10,11}.

Management part of the intraperitoneal rupture of bladder necessitates surgical repair as it can cause serious complication due to translocation of microorganisms from urine into peritoneum also the traumatic rupture causes bigger rents (as compared to penetrating injuries) which does not allow spontaneous healing without surgical repair. However uncomplicated extraperitoneal bladder injuries can be managed using urethral catheter

drainage⁷. Follow up cystography is not necessary in simple intraperitoneal repairs while more complex repairs and those cases of extraperitoneal rupture which were managed by only catheter drainage should be done to confirm the healing¹².

Postoperative adequate urine output and an unblocked freely draining bladder catheter is important to prevent catheter-associated urinary tract infections (CAUTI), especially with the highly susceptible patient population seen in trauma and critical care settings¹³. Antibiotic prophylaxis can reduce the incidence of CAUTI throughout the duration of an indwelling catheter². Nursing care for proper catheter bag placement and twice-daily perineal care reduces CAUTI as much as 70% in trauma patients¹⁴. Post operatively for many days we had more than 4 litres of urine output by our patient for which we only kept a close watch on serum electrolytes and compensation of volume loss by encouraging oral intake. This is likely due to “post obstructive polyuria” as a normal physiologic response to eliminate volume and solutes that accumulated⁵. Leaving the catheter in place two to three weeks is standard as most uncomplicated bladder injuries will heal within that time frame⁷.

Conclusion: We present a rare case of intra and extraperitoneal urinary bladder rupture following MVA assessed, resuscitated, and managed surgically with uneventful postoperative recovery. Total length of hospital stay exceeded a month due to post operative CAUTI managed successfully and discharged without any other complications for a period of 3 months on follow up.

References:

1. Bell. Fracture of the Pelvis and Rupture of the Bladder. *Lond Med Phys J.* 1827 May;2(11):417-418. PMID: 30495511; PMCID: PMC5674583
2. Gomez RG, Ceballos L, Coburn M, Corriere JN Jr, Dixon CM, Lobel B, McAninch J. Consensus statement on bladder injuries. *BJU Int.* 2004 Jul;94(1):27-32. doi: 10.1111/j.1464-410X.2004.04896.x. PMID: 15217426
3. Brandes S, Borrelli J Jr. Pelvic fracture and associated urologic injuries. *World J Surg.* 2001 Dec;25(12):1578-87. doi: 10.1007/s00268-001-0153-x. PMID: 11775195
4. Matlock KA, Tyroch AH, Kronfol ZN, McLean SF, Pirela-Cruz MA. Blunt traumatic bladder rupture: a 10-year perspective. *Am Surg.* 2013 Jun;79(6):589-93. PMID: 23711268
5. Elkbuli A, Ehrhardt JD, Hai S, McKenney M, Boneva D. Management of blunt intraperitoneal bladder rupture: Case report and literature review. *Int J Surg Case Rep.* 2019;55:160-163. doi: 10.1016/j.ijscr.2019.01.038. Epub 2019 Feb 1. PMID: 30739872; PMCID: PMC6369329
6. Guttman I, Kerr HA. Blunt bladder injury. *Clin Sports Med.* 2013 Apr;32(2):239-46. doi: 10.1016/j.csm.2012.12.006. Epub 2013 Feb 8. PMID: 23522505
7. Morey AF, Brandes S, Dugi DD 3rd et al: Urotrauma: AUA guideline. *J Urol* 2014, 192: 327
8. Ridinger HA, Kavitt RT, Green JK. Urinary ascites and renal failure from unrecognized bladder rupture. *Am J Med.* 2012 Sep;125(9):e1-2. doi: 10.1016/j.amjmed.2012.01.019. Epub 2012 Jun 27. PMID: 22748402
9. Bain K, Kassapidis V, Meytes V, Glinik G. FAST examination diagnosing bladder rupture following blunt pelvic trauma. *BMJ Case Rep.* 2018 Mar 21;2018:bcr2017223933. doi: 10.1136/bcr-2017-223933. PMID: 29563130; PMCID: PMC5878300
10. Vaccaro JP, Brody JM. CT cystography in the evaluation of major bladder trauma. *Radiographics.* 2000 Sep-Oct;20(5):1373-81. doi: 10.1148/radiographics.20.5.g00se111373. PMID: 10992026
11. Quagliano PV, Delair SM, Malhotra AK. Diagnosis of blunt bladder injury: A prospective comparative study of computed tomography cystography and conventional retrograde cystography. *J Trauma.* 2006 Aug;61(2):410-21; discussion 421-2. doi: 10.1097/01.ta.0000229940.36556.bf. PMID: 16917459
12. Inaba K, McKenney M, Munera F, de Moya M, Lopez PP, Schulman CI, Habib FA. Cystogram follow-up in the management of traumatic bladder disruption. *J Trauma.* 2006 Jan;60(1):23-8. doi: 10.1097/01.ta.0000200096.44452.8a. PMID: 16456432
13. Shaver B, Eyerly-Webb SA, Gibney Z, Silverman L, Pineda C, Solomon RJ. Trauma and Intensive Care Nursing Knowledge and Attitude of Foley Catheter Insertion and Maintenance. *J Trauma Nurs.* 2018 Jan/Feb;25(1):66-72. doi: 10.1097/JTN.0000000000000344. PMID: 29319654
14. Elkbuli A, Miller A, Boneva D, Puyana S, Bernal E, Hai S, McKenney M. Targeting Catheter-Associated Urinary Tract Infections in a Trauma Population: A 5-S Bundle Preventive Approach. *J Trauma Nurs.* 2018 Nov/Dec;25(6):366-373. doi: 10.1097/JTN.0000000000000403. PMID: 30395037