

Case report

Solitary Breast Cysticercosis Simulating Benign Tumor in a Young Female

Abstract

Cysticercosis is a systemic disease caused by ingestion of larval form of pork tapeworm. It is a major health problem of many developing countries where the disease spreads expeditiously due to poor sanitation practice and where pigs roam freely and eat human excreta. Neurocysticercosis has been well established worldwide but localization of infective larval form in various other tissues like skeletal muscles, subcutis and eye have also been documented lately. We, herein, describe a rare case of solitary breast cysticercosis in a young vegetarian female from northern part of India.

Keywords : Breast; Cysticercosis; Histopathology

Introduction

Human cysticercosis is an increasingly common parasitic infection caused by dissemination of the metacestode of *Taenia solium* or pork tapeworm. It is a major health problem of many developing countries where the disease spreads expeditiously due to poor sanitation practice. The common sites of involvement are brain, skeletal muscle, subcutaneous tissue and eye. Breast is an unusual site and only a handful of cases have been reported in the literature till today. [1],[2],[3],[4] Herein, we describe an isolated case of breast Cysticercosis in a young unmarried vegetarian female.

Case report

A 28-year-old unmarried female, a strict vegetarian by diet presented with 11 months old history of painless lump in the upper outer quadrant of left breast. Initially, it was of the size of a pea but gradually progressed to achieve the size of a tennis ball. It was associated with off and on fever of low grade but not allied to cyclical changes, axillary mass or any nipple discharge. Her medical and family history was insignificant. Physical examination revealed a 4 x 3.5 cms lump that was non tender, mobile, soft to firm with unremarkable skin changes. Clinical diagnosis of fibroadenoma was considered and Cytological and Radiological

investigations were advised. Mammography was suggestive of calcified cyst with an echogenic nidus. Fine needle aspiration cytology was inconclusive. Hematological examination revealed mildly raised total leucocyte count. The lump was excised and sent for histomorphological examination.

Grossly, a greyish-white soft tissue piece measuring 3.5 x 3 cms was received. Outer surface was fibrofatty and cut surface showed a glistening white cyst measuring 2.8 x 2.5 cms[Figure1]. On light microscopy, a mural nodule composed of cyst with diagnostic scolices was observed. The cyst was characteristically lined by three layers - outer cuticular layer, middle cellular layer and inner fibrillary layer of small canaliculi [Figure 2a]. The surrounding tissue revealed several foreign body type giant cells and plenty of eosinophils, lymphocytes and plasma cells[Figure 2b].

Subsequently the patient was given a course of albendazole for four weeks.

Discussion

Cysticercosis is a zoonotic disease that was prevalent in Egyptian and Greek cultures in ancient times. However, the first report on human cysticercosis was described by Rumler in 1558 during the autopsy of an epileptic patient who had liquid filled vesicles adherent to the meninges. Since then neurocysticercosis is considered as one of the leading causes of adult – onset seizures all over the world.^[5] It has now emerged as one of the major public health problem in most developing countries with poor sanitation practice, where pigs are raised by traditional methods and left to move freely and eat human excreta. Presently, an estimated 50-100 million people are suffering from cysticercus infection worldwide. This is probably an underestimate since many infections remain undetected. Zones of endemic disease include Central and South America, India, China, Southeast Asia, and sub-Saharan Africa.^[6]

Man is the definitive host while pigs act as intermediate host in the life cycle of *T. solium*. Human cysticercosis develops as a result of ingestion of larval stage through fecal-oral transmission or perhaps through autoinfection. The eggs are sticky and can get stuck to the fingers of tapeworm carriers who are the transmitters of the disease even in population not consuming contaminated pork. Our patient was a vegetarian by diet from an Indian race and so probably the source of infection in her case was contaminated food or water.

Viable cysticercus suppresses the host immune mechanism by inhibiting the complement activation and cytokine production. However, over the years the parasite loses its ability to control host defences and the inflammatory response hence produced causes degeneration of the cysticercus when the clinical manifestations develops. Since the incubation period in cysticercosis is much prior to the appearance of clinical symptoms, the infected patients are often asymptomatic. Moreover, its rare occurrence in the breast and non specific clinical manifestations pose great hindrance in the diagnosis repeatedly. A study from Nepal reported 62 cases of cysticercosis, of which five were in breast but all were initially presumed cases of fibroadenoma.^[7] Extensive literature search revealed less than a dozen cases of breast cysticercosis from Indian subcontinent.^[8] Many times Imaging gives a clue to diagnosis by detecting calcified cysts but confirmation requires demonstration of parasite on histology. Nevertheless, in endemic zones, a differential diagnosis of cysticercosis must be considered in breast masses as it is a preventable disease.

References

1. Kunkel JM, Hawksley CA. Cysticercosis presenting as a solitary dominant breast mass. *Hum Pathol.* 1987;18:1190–91.
2. Amatya BM, Kimula Y. Cysticercosis in Nepal; A histopathologic study on sixty two cases. *Am J Surg Pathol.* 1999;23:1276–79.
3. Sah SP, Jha PC, Gupta AK, et al. An incidental case of breast cysticercosis which was associated with a fibroadenoma. *IJPM.* 2001;44(1):59–61.
4. Geetha TV, Krishnanand BR, Pai CG. Cysticercosis of the breast: A rare presentation. *J. Nep Med Assoc.* 2000;39:184–85.
5. Del Brutto OH, Santibañez R, Noboa CA, Aguirre R, Diaz E, Alarcón TA. Epilepsy due to neurocysticercosis: analysis of 203 patients. *Neurology.* 1992;42:389–92.
6. Wu W, Qian X, Huang Y, Hong Q. A review of the control of clonorchiasis sinensis and Taenia solium taeniasis/cysticercosis in China. *Parasitol Res.* 2012 Oct 5.
7. Amatya BM, Kimula Y. Cysticercosis in Nepal: A histopathologic study of sixty-two cases. *Am J Surg Pathol.* 1999;23: 1276–9.
8. Sahai K, Kapila K, Verma K. Parasites in fine needle breast aspirates: Assessment of host tissue response. *Postgrad Med J.* 2002;78:165–7.

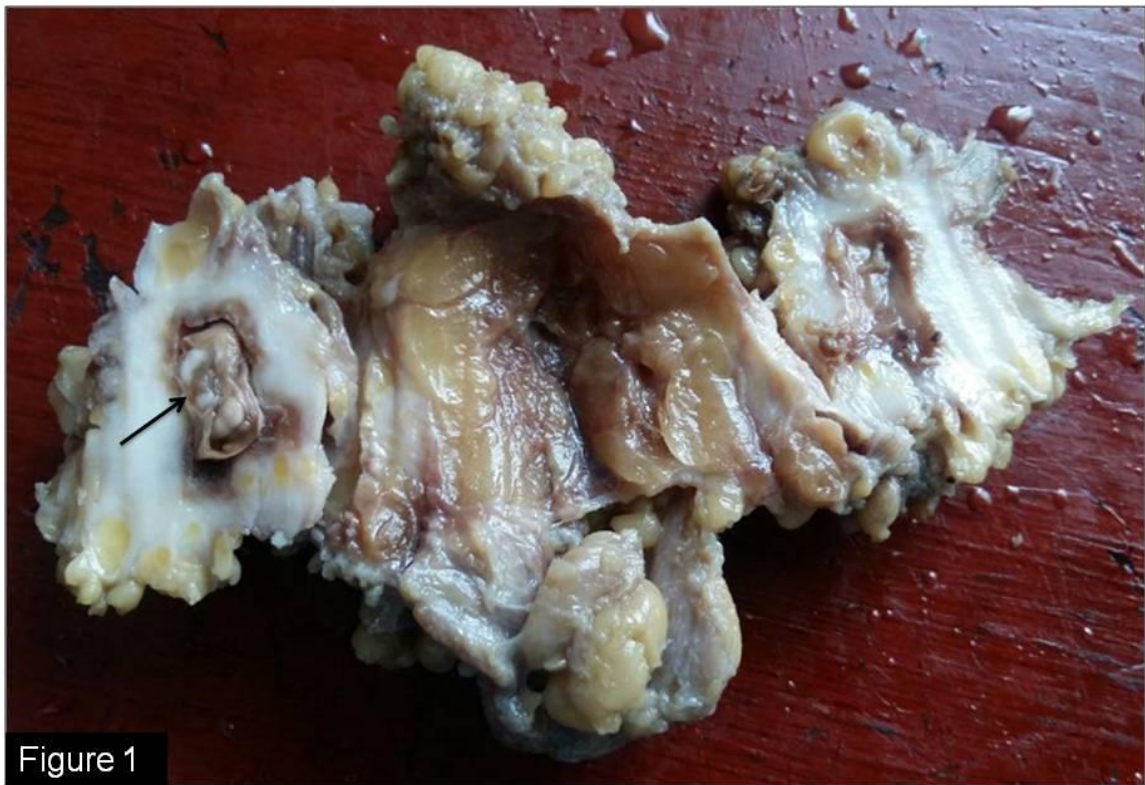

Figure 1

Fig1 Gross photograph of left breast lump showing a glistening white cystic area (marked with black arrow)

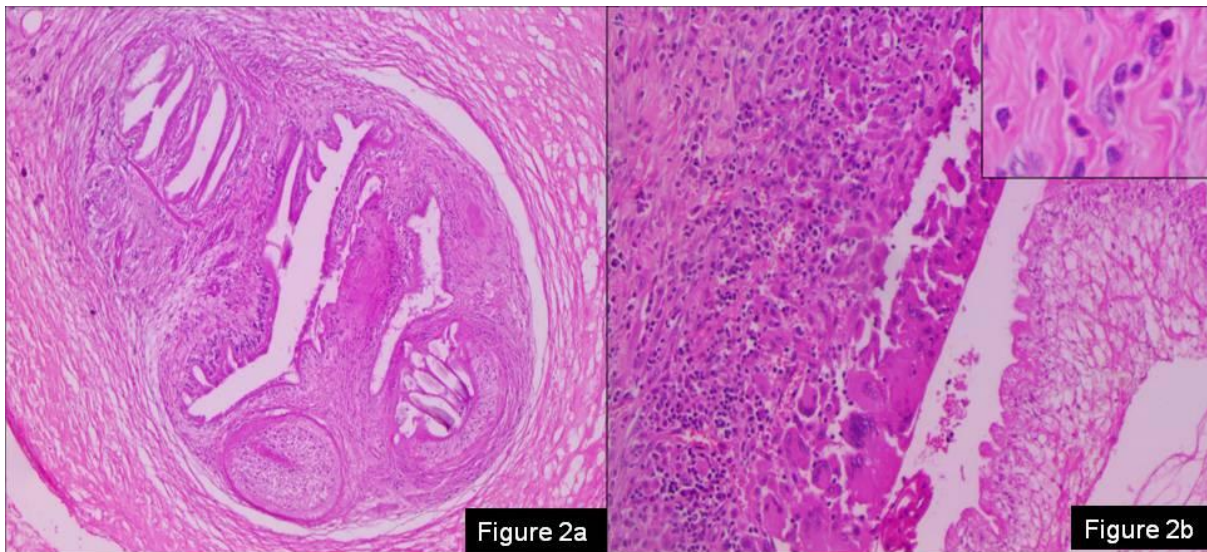


Fig 2a Photomicrograph of a three layered cyst with diagnostic scolices(H&E, x40)

Fig 2b Photomicrograph showing foreign body giant cells, histiocytes, lymphocytes and plenty of eosinophils (Inset) (H&E, x20)

UNDA