

# Clinical Evaluation of Injectable Platelet-Rich Fibrin (i-PRF) and Albumin Gel (ALB-GEL) as Autologous Tissue Regenerators in Facial Aesthetics on Hemifaces

---

## ABSTRACT

**Abstract:** Cutaneous ageing is a natural process associated with advancing age, potentially resulting in negative consequences on individuals' self-esteem. The primary manifestations of this process are the emergence of wrinkles, spots, dehydration, sagging, and loss of tissue vitality. In recent years, there has been a significant increase in the pursuit of more natural treatments for facial rejuvenation. In this context, using ALB-Gel and i-PRF stands out as a biological and autologous material. **Materials and Methods:** The measurement of the dermis using a 16 MHz ultrasound device and photographic documentation allowed for evaluating the technique's efficacy in reducing signs of ageing and nasolabial fold depth. The clinical study was conducted with 13 female participants aged 35 to 55 who underwent a session of ALB-Gel and i-PRF application in the right hemiface nasolabial fold region and i-PRF in the left hemiface. A paired t-test with a significance level of 5% was used in the statistical analysis. The scores on the Self-Perception Index were also statistically assessed using the Wilcoxon test at 5% to verify significant improvement. Additionally, new frontal and profile D and E photos were taken and compared with the initial images. **Results:** For the right hemiface nasolabial fold, a  $P < 0.0074$  was observed to compare initial and final signs; for the left hemiface, a  $P < 0.1259$  was obtained. These statistical results evidence a significant increase in dermal thickness in the right hemiface nasolabial fold (D) region after intradermal application of ALB-Gel and i-PRF; in the left hemiface nasolabial fold (E) region, treated only with i-PRF, no significant change in dermal thickness was observed. The statistical analysis conducted for the Self-Perception Index revealed a  $P < 0.0001$ , indicating a highly significant improvement in participant perception post-treatment. **Conclusion:** The intradermal application of ALB-Gel and i-PRF in a single session significantly increased dermal thickness, indicating this is a simple and low-cost alternative for dermal restructuring.

*Keywords: Platelet-rich fibrin, ageing, rejuvenation, ultrasonography.*

## 1. INTRODUCTION

The skin is the largest organ of the human body, accounting for 16% of body weight; it is responsible for protection, nourishment, and pigmentation, acting as a thermal insulator, offering protection against various environmental agents, and serving sensory functions [1]. The skin is composed of collagen, a protein that provides strength and resilience to this organ. It is produced from precursors - pro-collagen, which are expressed through the coding of genes by dermal fibroblasts [2]. Collagen accounts for approximately 25% to 30% of the total body protein and is responsible for the elasticity and integrity of the skin [3]. As we age, the natural production of collagen decreases, resulting in cutaneous ageing [4].

Skin ageing is a natural process that involves multiple factors (intrinsic and extrinsic). The intrinsic or chronological factor corresponds to the natural wear of cells. In contrast, extrinsic factors include exposure to UV rays, pollution, smoking, alcohol consumption, and lifestyle, with these factors significantly accelerating ageing [5]. In this process, the body undergoes

inevitable morphological and physiological changes that manifest molecular changes at the cellular, histological, and anatomical levels [6].

Collagen and elastin are products of fibroblast synthesis that undergo degradation with excessive exposure to the sun and other extrinsic factors, causing wrinkles and loss of skin elasticity [7]. The cellular mechanisms of ageing are closely linked to the telomeric hypothesis observed by Hyflick (1997), that is, with each cell division, chromosomes undergo changes that prevent proper cell replication [8]. The Hayflick limit explains the fact that fibroblasts lose part of their telomere with each cell division, which can be used as biological markers of this process [9].

Ageing is characterised by changes in gene expression and increased oxidative stress, causing DNA anomalies [10,12].

Practice in aesthetic medicine offers numerous conventional treatments using materials that often fail to deliver the results promised by manufacturers [13]. Products produced by laboratories, no matter how bioidentical they may be, can have immediate and delayed reactions such as persistent and intermittent late oedema (PLIE) [14,15]. In this context, platelet concentrate contains a supra-physiological quantity of platelets; these release growth factors that stimulate tissue repair and skin rejuvenation. Platelet growth factors are extracellular signalling molecules capable of stimulating a cascade of events such as fibroblast cell division, cell migration, gene expression (differentiation of mesenchymal cells), chemotaxis, promotion of angiogenesis, and cell migration [16]. This biomaterial has been used therapeutically to regulate essential processes in skin rejuvenation [17].

Platelet-Rich Plasma (PRP) and Platelet-Rich Fibrin (PRF) are autologous biotherapies used in Regenerative Aesthetic Medicine. PRP is obtained by centrifuging the patient's blood in the presence of an anticoagulant to concentrate the platelets, which are rich in growth factors and are frequently used to promote tissue healing and regeneration. PRF, a second-generation platelet concentrate, not only concentrates platelets and leukocytes but also forms a fibrin matrix that allows a slower and more sustained release of growth factors, providing a prolonged regenerative effect. Both concentrates can serve as a biological basis for the formation of a gel obtained under the influence of high temperatures. This gel acquires properties that allow an even slower absorption into the tissue, serving as a more enduring scaffold to keep the platelets and leukocytes at the desired location and optimise the delivery of growth factors to the injured tissue. While PRP and PRF focus on the concentration and delivery of regenerative factors, the gel form adds a structural dimension to the treatment, potentially enhancing the efficacy of regenerative therapy [44].

Platelet-Rich Fibrin (PRF), cited by Choukroun (2001) and introduced to the scientific community by Dohan and Choukroun in a series of articles in 2006, aimed to present a biological material free of anticoagulants known as healing inhibitors [19,20]. PRF introduced a new concept for obtaining platelet concentrates without exogenous chemical additives, becoming a key in tissue engineering by providing three critical factors: cells, growth factors, and scaffolding [21]. Its role in the healing process has shown efficacy, as cells and growth factors, crucial in this process, are found in large quantities in the fibrin matrix [20,22]. This protocol, also known as L-PRF (Leukocyte Platelet-Rich Fibrin), was obtained under high centrifugal force, characterising fibrin of high density and cellular concentration. Numerous publications have highlighted the benefits of PRF in the regenerative practice of soft and hard tissues [23]. New protocols were also established, altering the relative centrifugal force (RCF) and centrifugation time. In 2014, a new type of PRF obtained at low force, A-PRF (Advanced Platelet-Rich Fibrin) and A-PRF+, resulted in a more porous fibrin with lower density and more dispersed cellular settlement [24,25]. In 2015, Mourão and colleagues

mentioned in a technical note about i-PRF (Injectable Platelet Rich Fibrin). Still, this protocol was only well elucidated in subsequent publications by Miron et al. (2017) and Wang et al. (2018). The use of plastic tubes without activators and additives and modifications in speed and centrifugation time slowed down the coagulation time [20,26]. The result was a product containing fibrinogen and thrombin, which remained fluid for about 20 minutes at room temperature before forming fibrin, making it a suitable injectable material for facial rejuvenation [27]. Currently, with temperature control, i-PRF in the field of facial aesthetics allows for an even longer working time [28].

In 2018, Mourão et al. discussed a preliminary study on a new technique for obtaining a gel through the denaturation of albumin present in plasma. In this technique, the platelet-poor plasma (PPP), mainly containing albumin, is heated for 10 minutes at 75°C, allowing the denaturation of this material and forming an albumin gel named ALB-Gel [29]. The denaturation process restructures the proteins into a denser protein structure with extended resorption properties [29,30]. However, it is already known that, after heat treatment, PRF or PPP lose their regenerative power, as cells and growth factors are unable to withstand the denaturation process through heating. Thus, a reintroduction of the buffy coat (platelet-rich layer) removed from the tube after centrifugation is mixed with ALB-Gel (heated and cooled PPP), decellularising this biomaterial, then named ALB-PRF [29,31].

Volumisation of the soft tissues of the face is one of the most effective procedures for reducing wrinkles and filling in deeper furrows in some regions of the face, previously achievable only through surgery [32]. However, despite the advantages of injectable fillers, their high cost and risks of inflammation from foreign materials to the human body must be considered [33].

Several researchers from different health fields have reported the use of ALB-Gel and i-PRF in relation to surgical treatments, such as oral, maxillofacial, and aesthetic treatments [13,30,34–36]. Regarding the use of ALB-Gel and i-PRF in facial rejuvenation and volumisation, some studies have been emerging in the scientific community; however, there is still a significant need for research, especially concerning the durability time of this gel in vivo.

With the growing expansion in the field of Aesthetic Medicine, the growth factors contained within platelet concentrates emerge as a promising therapy, regulating relevant processes in tissue restructuring and, consequently, in cutaneous rejuvenation. This novel and in vivo study aims to elucidate the results obtained with the use of ALB-Gel and i-PRF at high centrifugal force in rejuvenation and volumisation in the nasolabial fold area, utilising a system that combines objective (skin analysis) and subjective (self-perception questionnaire and photos) approaches. The effects of applying ALB-Gel and i-PRF separately on the right hemiface and i-PRF alone on the left hemiface via intradermal route were evaluated to compare which protocol presents a better result as a volumiser, biostimulator, and autologous tissue restorer in this region.

## **2 MATERIALS AND METHODS**

The study was submitted and approved by the Ethics and Research Committee of the University of Paraíba Valley, Sao Paulo, Brazil (Opinion 5.398.140/CAAE 56591922.5.0000.5503) in accordance with the regulations of the National Health Council by resolution 466/2012. All participants included in this study were aware of the procedures they would undergo and signed an Informed Consent Form (ICF).

The following inclusion criteria were used: female individuals aged between 35 and 55 years, with the presence of signs of cutaneous ageing such as sagging, loss of dermal thickness, and nasolabial folds. Pregnant women, individuals allergic to the components of the pre-procedure ointment (dermomax), lactating women, individuals with neoplasms, anaemias, diabetes, deep vein thrombosis, autoimmune diseases, infectious processes, the recent application of botulinum toxin or fillers, dermatological disease at the site, tanned skins from sunbathing or artificial tanning, and individuals who had undergone recent surgery (up to 30 days before) and/or use of anti-inflammatory drugs (NSAIDs), antibiotics, and anticoagulants were excluded.

A total of 13 participants were selected for the present study. The participants underwent a session of application of ALB-Gel and i-PRF separately in the nasolabial fold region on the right hemiface (ALB-Gel was applied first, followed by i-PRF at the same location and in the same layer) as the test group. In the nasolabial fold region on the left hemiface, i-PRF was applied alone as the control group. In both protocols, a 22 G cannula was used for application in the reticular dermis (deep dermis). After a 21-day interval, the patients returned for evaluation of the results. For subsequent comparison, the face was photographed in a frontal position, with right (D) and left (E) profiles.

The participants underwent skin ultrasound examinations in the nasolabial fold region, right hemiface (D), and left hemiface (E), performed by the same examiner, with a 16 MHz linear transducer (VINNO Technology, Suzhou Co., Ltd) to measure dermal thickness, subsequently analysing the relationship between the initial and final signs for each volunteer.

Prior to the commencement of the procedure, the participant was pre-treated with Dermomax anaesthetic cream for 30 minutes. The protocol began with a venous puncture of the participant using a 21 G scalp to collect three tubes of 9 ml each, totalling 27 ml of total blood. The collection was performed in a PET plastic tube, without additives and anticoagulants, with a sterile white cap from the company (VACUETTE®, Greiner Bio-One). The collected material was processed in a centrifuge (IntraSpin, Intra-Lock, FL, USA) for 3 minutes at 2700rpm/700g RCF, with the rotor radius to the bottom of the tube (Rmax) being 8.5 cm, according to the protocol previously described (37). After centrifugation, we collected the area called "the buffy coat", corresponding to approximately 1.5 ml per centrifuged tube, totalling a volume of 4.5 ml. The infiltrate was separated with a sterile plastic pipette and placed in a sterile plastic petri dish, avoiding contact with metal, oxygen, or any instrument that could trigger the coagulation process. We collected the upper part of the infiltrate, called platelet-poor plasma (PPP), approximately 1 ml per tube in a 3 ml syringe. We placed the syringe with PPP in the heater (Thermal Filler, Model BS 92 BPR, BiancoLab, BR) and subjected it to heating at 75°C for 10 minutes to obtain the gel according to the protocol described by (31). After cleansing the face with 2% chlorhexidine, we injected 1 ml of i-PRF in the form of intradermotherapy and 1 ml of ALB-Gel using a 22 G cannula in the retro-injection technique into the deep dermis (reticular dermis) in the nasolabial fold region of the right hemiface. We used the same technique on the left hemiface but only injected 1 ml of i-PRF alone.

Participants were instructed to i) not manipulate the application area for at least 12 hours, ii) avoid exposure to the sun or excessive temperatures for seven days, and iii) avoid using anti-inflammatory drugs in the seven days following the procedure. Additionally, from the day after the procedure, further recommendations were: i) use sunscreen with at least SPF 30 on the application area for 30 days (apply twice a day); ii) not use makeup or cosmetics in the area for 24 hours; iii) avoid contact with hot water in the first 24 hours after the procedure; iv) avoid the use of alcoholic beverages for 24 hours; v) avoid the use of acids on the site in the first 48 hours; and vi) return on the day and time scheduled for their next session.

Twenty-one days after treatment, participants underwent a new skin ultrasound examination to measure whether there was an increase in dermal thickness and quantify this increase in each right (D) and left (E) hemiface. A paired t-test with a significance level of 5% was used for this statistical analysis. In addition, new frontal and profile D and E photos were taken and compared with the initial images. The results were displayed in photographs to allow evaluation through visual comparison, with records taken before and after the procedure accompanied by graphs and tables.

Participants also answered a subjective self-perception questionnaire with four questions (for "yes" or "no" responses) regarding the quality of the skin, considering the perception of improvement in the presence of wrinkles, sagging, expression lines, and hydration after treatment. To quantify the responses, the Self-Perception Index was created, for which each response was worth 0 (no) or 1 (yes), so each participant's total score would be between zero and four. Based on the responses, the occurrence of a significant difference between the volunteers' scores and the value zero (which would correspond to the absence of any perceived improvement) was evaluated. For this, the scores on the Self-Perception Index also underwent statistical evaluation, employing the Wilcoxon test at 5% to verify the occurrence of significant improvement.

### 3 RESULTS

The thickness of the dermis was measured using 16 MHz ultrasound in the nasolabial fold regions of the right hemiface (D) and left hemiface (E) before starting the treatment and 21 days after the application of the technique. In Figures 1A, 1B, 2A, 2B, 3A, 3B, 4A, and 4B, we can observe an increase in the thickness of the superficial dermis, which is hypoechoic (grey), and the deep dermis, which is echogenic (white).

Figures 1A and 1B: Representation before and after treatment with i-PRF and ALB-Gel. The dermis is thicker in Figure (1B), demonstrating a positive response to the treatment with 1 ml of i-PRF and 1 ml of ALB-Gel.

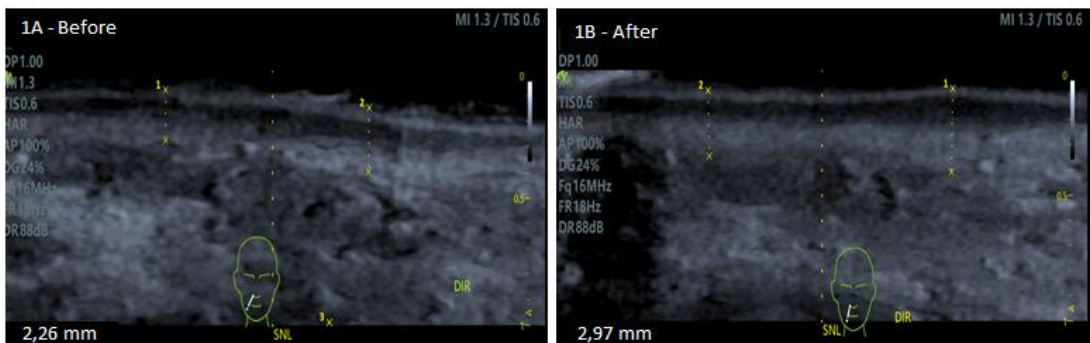
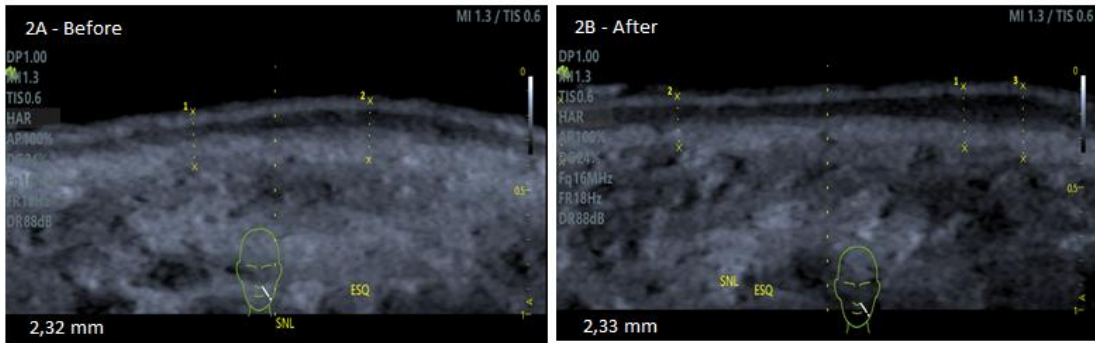
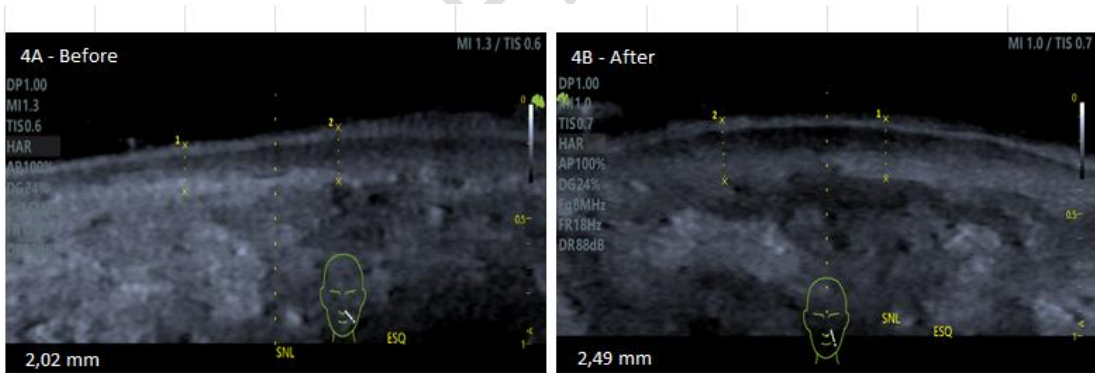
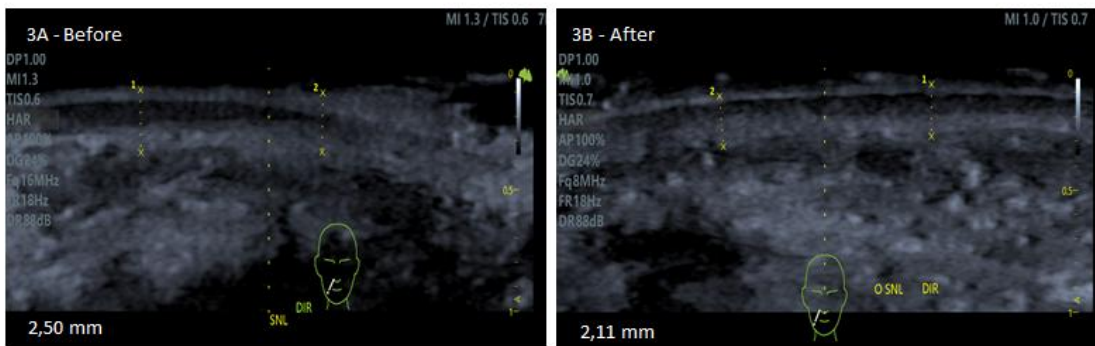


Figure 2 :2A and 2B: express before and after treatment with i-PRF



Source: The author (2022)

Figures 3A and 3B: Representation before and after treatment with i-PRF and ALB-Gel. In Figure (3B), the dermis appears to have lost thickness, indicating that other structures must be observed.



Source: The author (2022)

Figure 4 :4A and 4B: Representation before and after treatment with i-PRF

Below, Table 1 presents the results of the measurements and analyses conducted separately on the right hemiface and the left hemiface.

Table 1: Measurements of the nasolabial fold region (values in millimetres) before and after application, right hemiface and left hemiface.

Patient	Right hemiface		Left hemiface	
	Pre-application	Post-application	Pre-application	Post-application

1	2,50	2,11	2,02	2,49
2	2,52	2,48	2,52	2,65
3	1,68	2,64	1,71	2,01
4	1,94	2,20	1,88	2,03
5	2,20	2,42	2,89	2,22
6	2,26	2,97	2,32	2,33
7	2,48	2,64	2,62	2,69
8	2,20	2,44	2,45	2,48
9	2,47	2,96	2,50	2,85
10	2,11	2,48	2,06	2,30
11	2,42	2,76	2,51	2,80
12	1,81	2,00	1,74	1,90
13	2,06	2,34	2,22	2,34
Median	2,20	2,48	2,32	2,34
Mean	2,20	2,50	2,26	2,39
Standard deviation	0,28	0,30	0,36	0,31

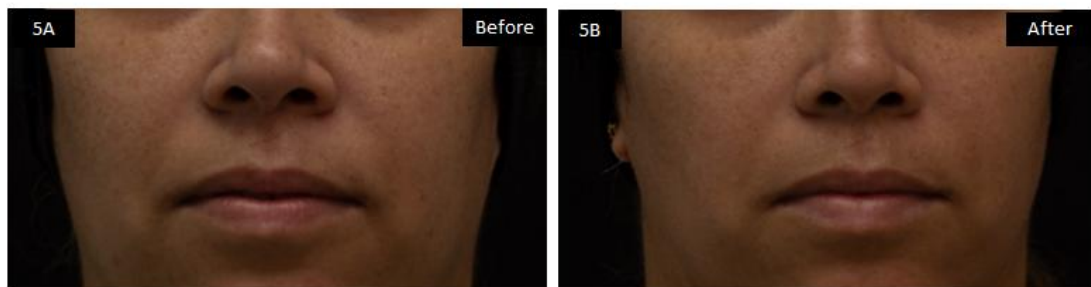
Source: The author (2022)

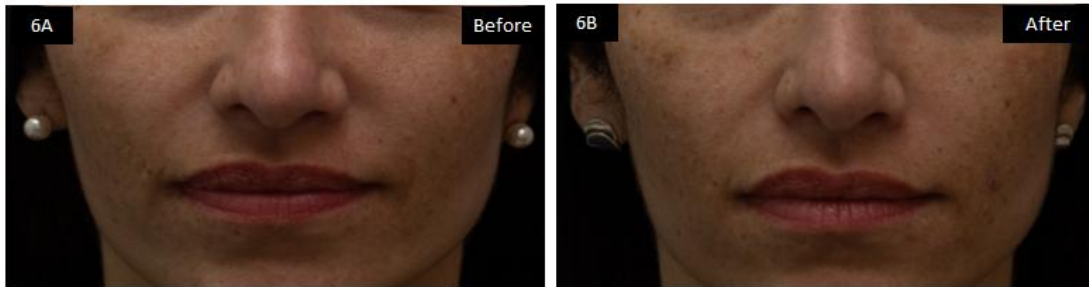
For each hemiface, a paired t-test was then applied for statistical analysis, with the initial value being the measurement of dermal thickness before treatment and the final value being the measurement of dermal thickness 21 days after the application of the technique. The paired t-test assumes a normal distribution of values, applying a two-tailed model with statistical significance at  $P < 0.05$ .

The paired t-test revealed that for the right hemiface of the nasolabial fold region,  $P < 0.0074$ ; for the left hemiface of the nasolabial fold region,  $P < 0.1259$  was observed. These statistical results indicate a significant increase in dermal thickness in the right hemiface (D) of the nasolabial fold treated with 1 ml of ALB-Gel and 1 ml of i-PRF; on the other hand, the left hemiface (E), treated only with i-PRF, did not show a significant change in dermal thickness (the thickness increase occurs within the margin of error indicated by the standard deviation).

Photographic records allowed for the subjective visualisation of the treatment's efficacy on signs of ageing such as wrinkles, sagging, skin vitality, pore changes, and the overall quality of the skin, as seen in figures 5A, 5B patient six and figures 6A, 6B patient 1.

Figures 5A, 5B: Pre-application: improvement in the overall appearance of the skin.



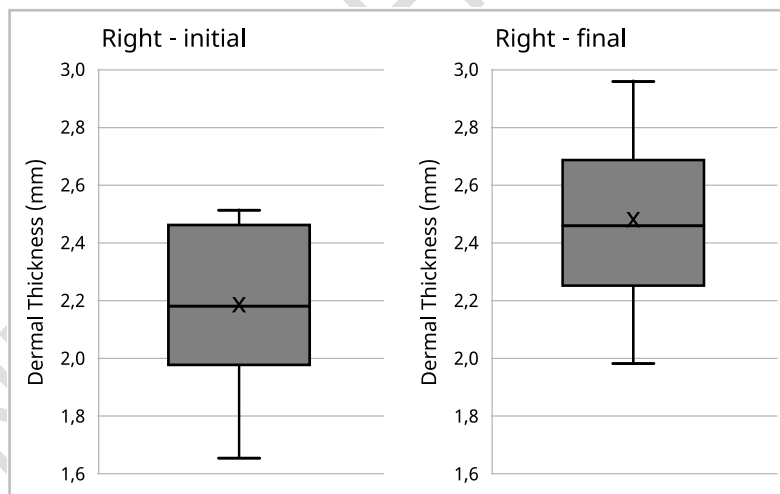


Source: The author (2022)

Figures 6A, 6B: Post-application: improvement in the overall appearance of the skin

Figures 7 and 8 assist in visualising the obtained results, presenting the box plots for the measurements (in millimetres) related to the nasolabial fold, respectively, on the right hemiface (Figure 7) and left hemiface (Figure 8). In each of these figures, the diagram of the initial measurement is presented on the left and the final measurement on the right, allowing for the visualisation of the significant increase in dermal thickness, especially notable in Figure 9.

Figure 7: Box plots of the epidermal thickness (in millimetres) pertaining to the right hemiface of the nasolabial fold. On the left is the initial value; on the right is the final value. The horizontal line within the box represents the median, and the "x" marks the mean.

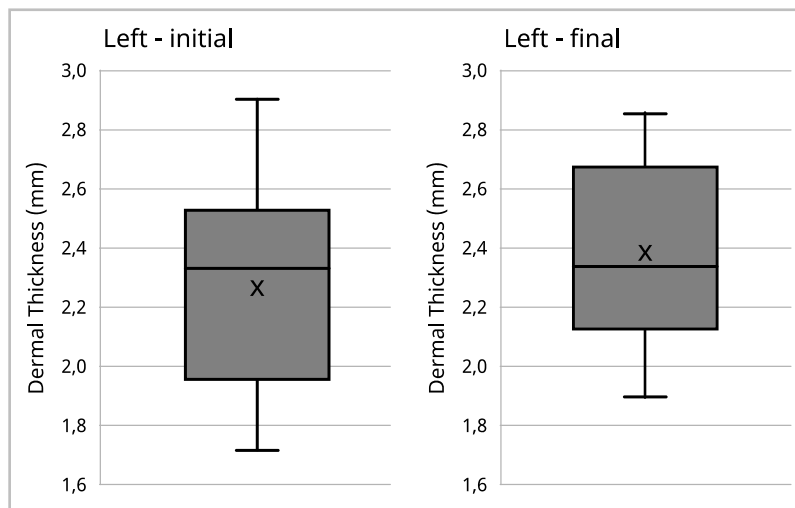


Source: The author (2022)

The treatment on the right hemiface (ALB-Gel followed by i-PRF) results in a clear upward shift of the "value box" (boxplot), which is particularly noticeable when observing the internal horizontal line (representation of the median), which jumps from 2.2mm (initial right value) to about 2.5mm (final right value). Thus, the final box plot has little overlap of values with the initial box plot in Figure 7, confirming the significant increase in thickness indicated by the paired t-test.

In the case of the left hemiface (i-PRF), the upward shift of the box plot is more subtle; in particular, the internal horizontal line (representation of the median) remains essentially constant, around 2.3mm (Figure 8). Furthermore, there is a significant overlap of values between the initial and final box plots, such that the statistical test cannot indicate a substantial increase in thickness in this hemiface.

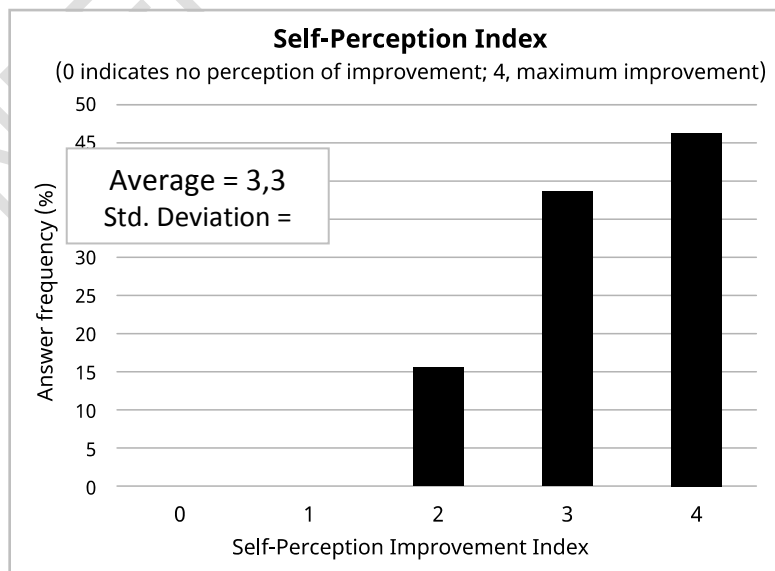Figure 8: Box plots of the epidermal thickness (in millimetres) pertaining to the left hemiface of the nasolabial fold. On the left is the initial value; on the right is the final value. The horizontal line within the box represents the median, and the "x" marks the mean.



Source: The authors (2022)

Subsequently, Figure 9 displays the distribution of the Self-Perception Index of improvement in skin condition based on responses to the applied questionnaire, with scores ranging from zero to four, where zero indicates "no improvement" and four, "maximum improvement."

Figure 9: Self-Perception Index before and after treatment.



Source: The authors (2022)

The self-perception of improvement was quite significant, reaching an average of 3.3 and a mode of 4 (the maximum possible value).

The statistical analysis conducted for the Self-Perception Index resulted in  $P < 0.0001$ , proving the participants' perception of effective improvement.

## DISCUSSION

The nasolabial fold region represents an essential mark of anti-aesthetic expression resulting from changes in the pillars of ageing: bone, fat, and dermis. This site is always requested for therapies traditionally used in Aesthetic Medicine.

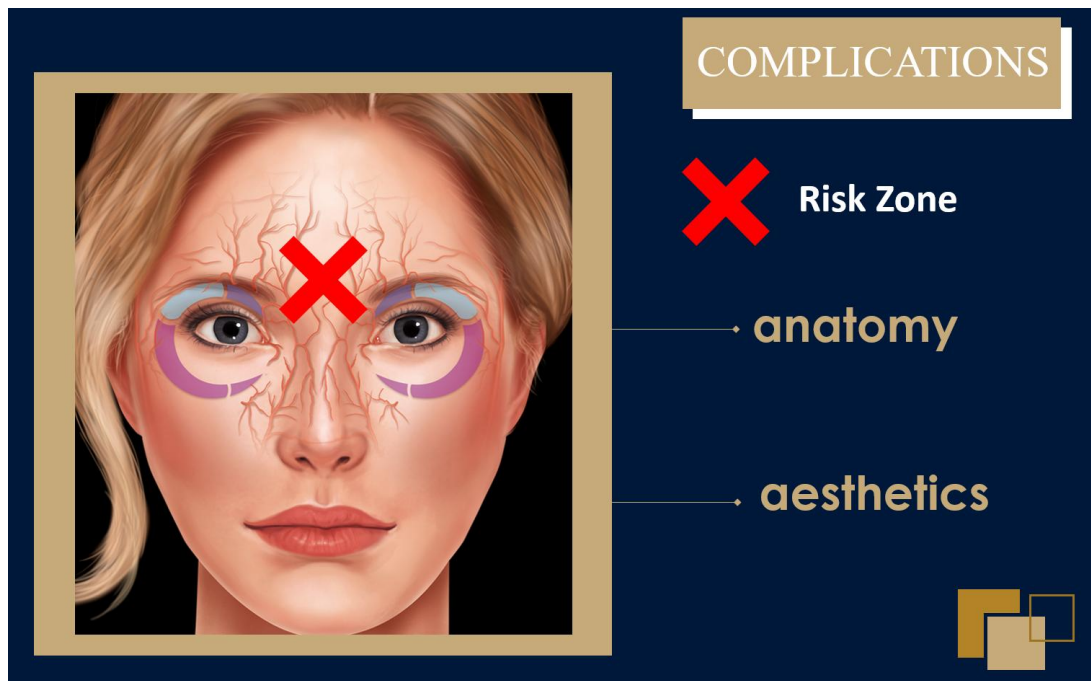
The most commonly used therapies for this region resort to fillings with hyaluronic acid and synthetic collagen biostimulators, aiming to increase dermal thickness in this area, improve the extracellular matrix, and restructure collagen and elastic fibres in general.

The effect of platelet concentrates in attracting cells such as fibroblasts to improve the function of restructuring the dermis is already known. The impact of growth factors in attracting new vessels and bringing excellent nutrition conditions to the tissues is also well recognised. With a restructured dermis rich in vessels, platelet concentrates become a superb therapy. They are natural, low-cost, and easy to apply to restore facial aesthetics without the use and complications of synthetic materials. In this line of thought, we tested platelet-rich fibrin in two different forms of application as well as other molecular structures. The injectable form of PRF, i-PRF, has few tissue-filling characteristics; however, it has a high biological commitment to stimulating and restoring tissues. On the other hand, albumin gel has a low potential for cellular biostimulation compared to i-PRF. Still, it has the potential to be absorbed over a longer time, possibly occupying dermal space and thereby biostimulating the skin for a more extended period. These two materials can be configured and mixed to be individualised for different clinical scenarios. Nonetheless, their mixed and homogenised use, called ALB-PRF, clinically responds with an initial increase in dermal contour, an expected absorption of the liquid form of PRF in a few days, which has evidenced an early volumetric loss in our clinical experience. As an application strategy, aiming to eliminate this initial volumetric loss and count on the stimulus of injectable PRF, associated with the filling effect of albumin gel (ALB-Gel), we delivered the injectable form with intradermotherapy done with a 30 G1/2 needle, and subsequent application of the pure gel done with a 22G cannula. A comparison was made with injectable PRF in a split face.

The literature needs to present evidence of the effectiveness of platelet concentrates in gel form, that is, the biological restructuring and dermal volumising effect. Some South American countries are prohibited from using traditional hyaluronic acid for facial volumisation. As an alternative, the use of PRP in the form of "plasma gel dermal filler" found in the literature is also infrequent. Anitua et al. presented two works on this subject on biological characterisation, dermal thickening, and clinical results only in 2018, already showing good outcomes with evident dermal thickening.

There are already some cases in the literature of necrosis and vascular occlusion likely caused by PRP in gel form in glabellar regions [38]. Despite the liquid form of the concentrates being entirely safe, the use of gel forms, whether PRP or PRF, requires proper technique and care and should be applied in anatomically and aesthetically safe areas since no substance degrades the gel, unlike hyaluronidase for hyaluronic acid. In Figure 10, we can observe the risk area.

Figure 10: Zone of complications requiring caution during applications.



Source: Adapted from the book " *Complicações na estética corporal e facial e o uso da ultrassonografia* "(43)

For the viability of application in this technique, we used a high-force centrifugation protocol to have well-separated cellularised and acellular areas in a single blood sample, as Mayron showed in his work. The portion near the red area is cellularised (buffy coat). It has excellent biological potential, as it is rich in platelets and leukocytes and is used for the composition of injectable PRF. In the same tube, the upper part contains an acellular sample, which will be heated to obtain ALB-Gel. This heating causes cell death and denatures molecular elements. Therefore, it is necessary to use the most acellular portion possible to avoid injecting these cellular remnants into the tissue, which may have some inflammatory potential. Low-force protocols keep the entire volume of centrifuged blood highly cellularised, making it impossible to separate these areas from obtaining PRF-GEL, contraindicating its use for this technique. Although it is evident that the exclusion of dead cells from the concentrate should be done, further studies must be conducted to verify this inflammatory potential.

The evidence obtained in this study with the application of different forms of PRF proves that platelets, fibrin, leukocytes, and growth factors, along with another acellular biological material like PRF GEL, seem to have a significant meaning in maintaining volume and attracting fibroblasts for dermal restructuring. It is worth mentioning that this restructuring is validated by the high growth factors in i-PRF, including vascular endothelial growth factor (VEGF), which ensures this restructuring through angiogenesis [21,39–41].

The literature has shown that platelet concentrates should be applied at least twice to achieve the best results, with an interval of no less than 21 days [42]. In a study by Brodt et al., dermal thickness enhancement is observed following the initial application and further increases after the second application. In this study, the first application was performed to

prove dermal improvement. Other studies should be conducted already employing the technique of applying i-PRF and ALB-Gel concentrates separately to demonstrate progress in different areas and to define the interval between them.

There were no significant incidents or side effects, only minor oedema and bruises, which disappeared within a week after application. The use of anaesthesia in the infraorbital nerve ensured a painless procedure.

The negative data measured in the present work can be attributed to the influence of working conditions with the ultrasound equipment. The pressure that the professional applies on the transducer over the skin can influence the results and the difference in the thickness of the contact gel between the transducer and the skin. A minimal amount of gel interferes with the clarity of the ultrasonographic image, making it challenging to measure dermal thickness. It is important to emphasise the importance of prior training of a single professional in this work to measure the dermis in order to establish a standard for this study. Although no study specifies the adequate thickness of contact gel between the transducer and skin to evaluate images appropriately, it was observed that an increased gel thickness provides better image resolution. And this is confirmed among most ultrasound professionals.

Upon reviewing the figures (graphs and photos), it is noted that the outcomes of the examination were satisfactory. Nonetheless, the clarity of the visual result in the photo examination appeared less pronounced, as evidenced by the images of Figure 5A and 5B for patient six in Table 1. This indicates the necessity to consider other underlying structures for analysis, including subcutaneous and muscular layers, regional inflammation, and the skin type of the treated area.

Despite treatment with i-PRF via intradermotherapy appearing to be the best treatment route, its results are sometimes questioned due to the lack of a methodological standard and the absence of comparative studies. However, its clinical outcomes in routine practice encourage further studies to support its effectiveness in facial aesthetics as a treatment and in the preparation of the local biological terrain.

## **CONCLUSION**

In this novel and in vivo study, it is possible to conclude that the protocol of i-PRF with high centrifugal force provides satisfactory dermal thickening results and the subjective aesthetic response of the individuals studied in the nasolabial fold region. The comparison between the gains obtained on the right and left hemiface suggests that the separate application of ALB-Gel enhances the treatment with i-PRF, increasing the results' significance. Despite the need for further studies of this material, this approach indicates a fundamental direction for more assertive clinical guidance in treatments with platelet concentrates aimed at volumising, biostimulation, and autologous tissue regeneration.

## CONSENT

Every participant in this study was fully briefed on the procedures they were to undergo and provided their signed Informed Consent Form (ICF). Documentation of these consent forms is accessible for examination by the Editorial Office, Chief Editor, or members of the Editorial Board of this journal.

## ETHICAL APPROVAL

The authors collectively affirm that all experiments conducted in this study underwent scrutiny and authorisation by the pertinent ethics committee, thus ensuring adherence to the ethical guidelines delineated in the 1964 Declaration of Helsinki.

## REFERENCES

1. MOORE, K. L.; DARLLY AF. Clinic-oriented anatomy. 4. Rio de Janeiro: Guanabara; 2001.
2. Poon F, Kang S, Chien AL. Mechanisms and treatments of photoaging. *Photodermatol Photoimmunol Photomed* [Internet]. 2015 Mar;31(2):65–74. Available from: <https://onlinelibrary.wiley.com/doi/10.1111/phpp.12145>
3. Visnardi AR. Effect of low-intensity ultrasound on collagen in healthy rat skin [Internet]. [São Carlos]: University of São Paulo; 2007. Available from: <http://www.teses.usp.br/teses/disponiveis/82/82131/tde-14022008-105151/>
4. TP Announcement. *Nutricosmetics* [Internet]. [Ribeirão Preto]: University of São Paulo; 2011. Available from: <http://www.teses.usp.br/teses/disponiveis/60/60137/tde-20092011-210914/>
5. Ortolan MCAB, Biondo-Simões M de LP, Baroni E do RV, Auersvald A, Auersvald LA, Montemor Netto MR, et al. Influence of aging on skin quality in white women: the role of collagen, elastic material density and vascularization. *Rev Bras Cir Plástica* [Internet]. 2013 Mar;28(1):41–8. Available from: [http://www.scielo.br/scielo.php?script=sci\\_arttext&pid=S1983-51752013000100008&lng=pt&nrm=iso&tlng=en](http://www.scielo.br/scielo.php?script=sci_arttext&pid=S1983-51752013000100008&lng=pt&nrm=iso&tlng=en)
6. I EJMR, Yadira D, Corrales M. Facial biostimulation with platelet-rich plasma. *Arch Doctor Camagüey*. 2015;19(2):167–78.
7. Sataloff RT, Johns MM, Kost KM. Skin aging: Free radical theory and treatments aimed at preservation and rejuvenation. *Rev Uningá*. 2010;24.
8. Gava AA, Zanoni JN. Cellular Aging. *UNIPAR Health Sciences Arq* [Internet]. 2005;9(1):41–6. Available from: <http://revistas.unipar.br/saude/article/view/218/192>
9. Naveilhan P, Baudet C, Jabbour W, Wion D. A theory that may explain the Hayflick limit — a means to delete one copy of a repeating sequence during each cell cycle in certain human cells such as fibroblasts. *Mech Aging Dev* [Internet]. 1994 Sep;75(3):205–13. Available from: <https://linkinghub.elsevier.com/retrieve/pii/0047637494900108>

10. Borson LAMG, Romano LH. Review: The genetic process of aging and the paths to longevity. *Rev Saúdeem Foco – Edition no. 12 – Year 2020* [Internet]. 2020;239–44. Available from: <https://portal.unisepe.com.br/unifia/wp-content/uploads/sites/10001/2020/08/REVISÃO-O-PROCESSO-GENÉTICO-DE-ENVELHECIMENTO-E-OS-CAMINHOS-PARA-A-LONGEVIDADE-239-a-244.pdf>
11. Castelo-Branco C. *Skin and mucosal aging*. Madrid, Spain; 2010.
12. Silva WJM da, Ferrari CKB. Mitochondrial metabolism, free radicals and aging. *Rev Bras Geriatr e Gerontol* [Internet]. 2011;14(3):441–51. Available from: [http://www.scielo.br/scielo.php?script=sci\\_arttext&pid=S1809-98232011000300005&lng=pt&tling=pt](http://www.scielo.br/scielo.php?script=sci_arttext&pid=S1809-98232011000300005&lng=pt&tling=pt)
13. Nacopoulos C. Use of Platelet-Rich Fibrin in Aesthetics and Facial Rejuvenation. In: *Platelet-rich fibrin in regenerative and aesthetic dentistry: biological bases and clinical applications*. 2018th ed. São Paulo: Quintessence Editora; 2018. p. 215–35.
14. Breda PL de CL. Persistent Delayed Intermittent Edema (ETIP) after using hyaluronic acid-based substances. *Brazilian J Heal Rev* [Internet]. 2022 Jul 15;5(4):12821–38. Available from: <https://brazilianjournals.com/ojs/index.php/BJHR/article/view/50317>
15. Cavallieri FA, Balassiano LK de A, Bastos JT de, Fontoura GHM da, Almeida AT de. Persistent, Intermittent Delayed Swelling PIDS intermittent swelling: late adverse reaction to Hyaluronic Acid fillers. *SurgCosmet Dermatology* [Internet]. 2017;9(3). Available from: <http://www.surgicalcosmetic.org.br/detalhe-artigo/583>
16. Takamori ER, Teixeira MVT, Menezes K, Carias RBV, Borojevic R. Platelet-rich fibrin: preparation, quality definition, clinical use. *Health Surveillance in Debate*. 2018;6(1):118.
17. Hassan H, Quinlan DJ, Ghanem A. Injectable platelet-rich fibrin for facial rejuvenation: A prospective, single-center study. *J Cosmet Dermatol* [Internet]. 2020 Dec 23 ;19(12):3213–21. Available from: <https://onlinelibrary.wiley.com/doi/10.1111/jocd.13692>
18. Choukroun J. Une opportunitéenparo-implantologie: le PRF. *Implantology*. 2001;42(55):e62.
19. Dohan DM, Choukroun J, Diss A, Dohan SL, Dohan AJJ, Mouhyi J, et al. Platelet-rich fibrin (PRF): A second-generation platelet concentrate. Part I: Technological concepts and evolution. *Oral Surgery, Oral Med Oral Pathol Oral Radiol Endodontology* [Internet]. 2006 Mar;101(3):e37–44. Available from: <https://linkinghub.elsevier.com/retrieve/pii/S107921040500586X>
20. Miron RJ, Fujioka-Kobayashi M, Hernandez M, Kandalam U, Zhang Y, Ghanaati S, et al. Injectable platelet rich fibrin (i-PRF): opportunities in regenerative dentistry? *Clin Oral Investig* [Internet]. 2017 Nov 2;21(8):2619–27. Available from: <http://link.springer.com/10.1007/s00784-017-2063-9>
21. Fujioka-Kobayashi M, Miron RJ. Biological Components of Platelet Rich Fibrin: Growth Factor Release and Cellular Activity. In: *Platelet Rich Fibrin in Regenerative Dentistry: Biological Background and Clinical Indications* [Internet]. Oxford, UK: John Wiley & Sons, Ltd; 2017. p. 15–31. Available from: <https://onlinelibrary.wiley.com/doi/10.1002/9781119406792.ch2>

22. Miron RJ, Choukroun J. *Fibrin e plaquetas na odontologia e medicina regenerativa e estética: bases biológicas e aplicações clínicas*. 2018th ed. São Paulo: Quintessence Editora; 2018.
23. Cortellini S, Castro AB, Temmerman A, Van Dessel J, Pinto N, Jacobs R, et al. Leucocyte- and platelet-rich fibrin block for bone augmentation procedure: A proof-of-concept study. *J Clin Periodontol* [Internet]. 2018 May;45(5):624–34. Available from: <https://onlinelibrary.wiley.com/doi/10.1111/jcpe.12877>
24. Ghanaati S, Booms P, Orlowska A, Kubesch A, Lorenz J, Rutkowski J, et al. Advanced Platelet-Rich Fibrin: A New Concept for Cell-Based Tissue Engineering by Means of Inflammatory Cells. *J Oral Implantol* [Internet]. 2014 Dec 1;40(6):679–89. Available from: <https://meridian.allenpress.com/joi/article/40/6/679/6702/Advanced-Platelet-Rich-Fibrin-A-New-Concept-for>
25. El Bagdadi K, Kubesch A, Yu X, Al-Maawi S, Orlowska A, Dias A, et al. Reduction of relative centrifugal forces increases growth factor release within solid platelet-rich-fibrin (PRF)-based matrices: a proof of concept of LSCC (low speed centrifugation concept). *Eur J Trauma Emerg Surg* [Internet]. 2019 Jun 21 ;45(3) :467–79. Available from: <http://link.springer.com/10.1007/s00068-017-0785-7>
26. Wang X, Zhang Y, Choukroun J, Ghanaati S, Miron RJ. Effects of an injectable platelet-rich fibrin on osteoblast behavior and bone tissue formation in comparison to platelet-rich plasma. *Platelets* [Internet]. 2018 Jan 2;29(1):48–55. Available from: <https://www.tandfonline.com/doi/full/10.1080/09537104.2017.1293807>
27. Wang X, Yang Y, Zhang Y, Miron RJ. Fluid platelet-rich fibrin stimulates greater dermal skin fibroblast cell migration, proliferation, and collagen synthesis when compared to platelet-rich plasma. *J Cosmet Dermatol* [Internet]. 2019 Dec 16;18(6):2004–10. Available from: <https://onlinelibrary.wiley.com/doi/10.1111/jocd.12955>
28. Miron RJ, Horrocks NA, Zhang Y, Horrocks G, Pikos MA, Sculean A. Extending the working properties of liquid platelet-rich fibrin using chemically modified PET tubes and the Bio-Cool device. *Clin Oral Investig* [Internet]. 2022 Mar 23;26(3):2873–8. Available from: <https://link.springer.com/10.1007/s00784-021-04268-x>
29. Barros Mourão C de A, Gheno E, Lourenço E, Barbosa RL, Kurtzman G, Javid K, et al. Characterization of a new membrane from concentrated growth factors associated with denatured Albumin (Alb-CGF) for clinical applications: A preliminary study. *Int J Growth Factors Stem Cells Dent* [Internet]. 2018;1(2):64. Available from: <http://www.cellsindentistry.org/text.asp?2018/1/2/64/235911>
30. Doghaim NN, El-Tatawy RA, Neinaa YME. Assessment of the efficacy and safety of platelet poor plasma gel as autologous dermal filler for facial rejuvenation. *J Cosmet Dermatol* [Internet]. 2019 Oct 26;18(5):1271–9. Available from: <https://onlinelibrary.wiley.com/doi/10.1111/jocd.12876>
31. Fujioka-Kobayashi M, Schaller B, Mourão CF DAB, Zhang Y, Sculean A, Miron RJ. Biological characterization of an injectable platelet-rich fibrin mixture consisting of autologous albumin gel and liquid platelet-rich fibrin (Alb-PRF). *Platelets* [Internet]. 2021;32(1):74–81. Available from: <https://doi.org/10.1080/09537104.2020.1717455>

32. Carruthers J, Cohen SR, Joseph JH, Narins RS, Rubin M. The science and art of dermal fillers for soft-tissue augmentation. *J Drugs Dermatol* [Internet]. 2009 Apr;8(4):335–50. Available from: <http://www.ncbi.nlm.nih.gov/pubmed/19363852>
33. Requena L, Requena C, Christensen L, Zimmermann US, Kutzner H, Cerroni L. Adverse reactions to injectable soft tissue fillers. *J Am Acad Dermatol* [Internet]. 2011 Jan;64(1):1–34. Available from: <https://linkinghub.elsevier.com/retrieve/pii/S0190962210006973>
34. İzol BS, Üner DD. A New Approach for Root Surface Biomodification Using Injectable Platelet-Rich Fibrin (I-PRF). *Med Sci Monit* [Internet]. 2019 Jun 26; 25:4744–50. Available from: <https://www.medscimonit.com/abstract/index/idArt/915142>
35. Ozsagir ZB, Saglam E, Sen Yilmaz B, Choukroun J, Tunali M. Injectable platelet-rich fibrin and microneedling for gingival augmentation in thin periodontal phenotype: A randomized controlled clinical trial. *J Clin Periodontol* [Internet]. 2020 Apr;47(4):489–99. Available from: <https://onlinelibrary.wiley.com/doi/10.1111/jcpe.13247>
36. Janmey PA, Winer JP, Weisel JW. Fibrin gels and their clinical and bioengineering applications. *J R Soc Interface* [Internet]. 2009 Jan 6;6(30):1–10. Available from: <https://royalsocietypublishing.org/doi/10.1098/rsif.2008.0327>
37. Cortellini S, Castro AB, Temmerman A, Van Dessel J, Pinto N, Jacobs R, et al. Leucocyte- and platelet-rich fibrin block for bone augmentation procedure: A proof-of-concept study. *J Clin Periodontol*. 2018;45(5):624–34.
38. Karam EZ, Gan A, MuciMendozaR, Martinez E, Perez E. Visual Loss after Platelet-rich Plasma Injection into the Face. *Neuro-Ophthalmology* [Internet]. 2020 Nov 1;44(6):371–8. Available from: <https://www.tandfonline.com/doi/full/10.1080/01658107.2020.1740936>
39. Antônio Colussi da Silva J, Giacomini M, Warmeling M, Miranda Pagnoncelli R. Use of growth hormone associated with injectable platelet- and leukocyte-rich fibrin (I-PRF). *Rev of FacOdontol - UPF*. 2019;24(2):309–15.
40. Rodríguez Flores J, Palomar Gallego MA, Torres García-Denche J. Platelet-rich plasma: biological foundations and applications in maxillofacial surgery and facial aesthetics. *Rev Española Cirugía Oral y Maxilofac* [Internet]. 2012 Jan;34(1):8–17. Available from: <https://linkinghub.elsevier.com/retrieve/pii/S113005581100102X>
41. Choi SW, Pangeni R, Jung DH, Kim SJ, Park JW. Construction and Characterization of Cell-Penetrating Peptide-Fused Fibroblast Growth Factor and Vascular Endothelial Growth Factor for an Enhanced Percutaneous Delivery System. *J NanosciNanotechnol* [Internet]. 2018 Feb 1 ;18(2):842–7. Available from: <http://www.ingentaconnect.com/content/10.1166/jnn.2018.14864>
42. Brodt FP, Garcia RP, Costa MF, Marchi CM De, Barja PR, Doria ACOC, et al. Evaluation of Injectable Platelet-rich Fibrin (i-PRF) as an Autologous Tissue Regenerator in Facial Aesthetics. *J Adv Med Med Res* [Internet]. 2023 Sep 13;35(21):97–109. Available from: <https://journaljammr.com/index.php/JAMMR/article/view/5215>
43. Donola, Gisele, and Vivian Castilho. *Complications in Body and Facial Aesthetics and the Use of Ultrasonography*. 1st ed., vol. 1, Napoleão Quintessence Publishing Brazil, 2023.

44. Napit IB, Shrestha D, Neupane K, et al, Autologous blood products: Leucocyte and Platelets Rich Fibrin (L-PRF) and Platelets Rich Plasma (PRP) gel to promote cutaneous ulcer healing – a systematic review *BMJ Open* 2023;13 : e073209. doi: 10.1136/bmjopen-2023-073209

UNDER PEER REVIEW