

Calretinin: An Explicit Marker For Ameloblastoma

Abstract :

We report 3 cases of dentigerous cyst showing ameloblastomatous changes, radicular cyst revealing ameloblastoma like features and Basal cell adenoma mimicking ameloblastoma. A wide range of diseases known as odontogenic cysts and tumors develop from the tooth-forming mechanism and its byproducts. It encompasses a broad range of clinical features, from benign to malignant. Calretinin immunopositivity was limited to stellate reticulum-like cells, where micro- and macrocysts were prominently stained. The cells that resembled peripheral ameloblasts were negative. These findings were similar to the observations reported previously. Its utility as diagnostic adjunct is crucial in the differential diagnosis of ameloblastoma and other odontogenic lesion. This distinction is essential for determining appropriate treatment protocol as different lesions require different treatment approaches with potentially serious functional and esthetic consequences for patient. Therefore, calretinin expression level can significantly impact treatment planning & patient outcome.

Keywords: macrocysts, Immunopositivity, stellate reticulum, ameloblastomatous changes

Introduction:

Odontogenic cysts and tumors are a diverse group of lesions originating from the tooth-forming apparatus and its remnants. They exhibit a wide range of clinical characteristics, from benign to malignant. Occasionally, the morphological and histopathologic patterns of these lesions mimic each other, making definitive diagnosis challenging. Various molecular markers have been studied in odontogenic lesions to identify specific cellular events. Calretinin, a 29-kilodalton (kDa) calcium-binding protein (CaBp), acts as a mediator of intracellular calcium ion signaling. These ions are important second messengers involved in numerous cellular processes, including proliferation and differentiation. Calretinin serves as a specific immunohistochemical (IHC) marker for neoplastic ameloblastic epithelium and plays a role in the transition of the epithelial lining of odontogenic cysts to ameloblastomatous epithelium. Therefore, it may be used as a diagnostic tool to differentiate between cystic odontogenic lesions and ameloblastic tumors.

Herein, reporting 3 cases, case- 1 dentigerous cyst showing ameloblastomatous changes, case- 2 radicular cyst revealing ameloblastoma like features and case-3 Basal cell adenoma mimicking ameloblastoma. So, to confirm the final diagnosis, Immunohistochemical marker (calretinin) applied which showed positive expression in case 1 & case 2 while negative immunostaining for case 3 which ruled out to be ameloblastoma.

Case Report 1

A 20-year-old female patient reported with a chief complaint of pain and swelling in the upper left back region of her jaw, persisting for one year. Extraorally, the swelling extended superoinferiorly from zygoma region to the corner of mouth, anteroposteriorly from ala of nose to mid zygoma region. Intraorally swelling was seen on left palatal side which was swelling is

soft, erythematous, soft & fluctuant on palpation. It extended from 21-24 leading to obliteration of buccal vestibule.

Histologically, 2-5 cell layered non-keratinized stratified squamous epithelium, characterized by the absence of rete pegs .Loose, haphazardly arranged collagen fibre bundles with mild degree of chronic inflammatory cells consisting lymphocytes & plasma cells. Few odontogenic epithelial islands showed peripheral cells reverse polarity and hyperchromatic nuclei suggestive of ameloblastomatous epithelium.

In this case on incisional biopsy, the initial diagnosis suggested an infected dental cyst. Notably ,a few odontogenic islands exhibited reverse polarity & hyperchromatic nuclei characteristic of ameloblastomatous epithelium, however with calretinin upon further examination the biopsy results indicated features consistent with ameloblastoma.

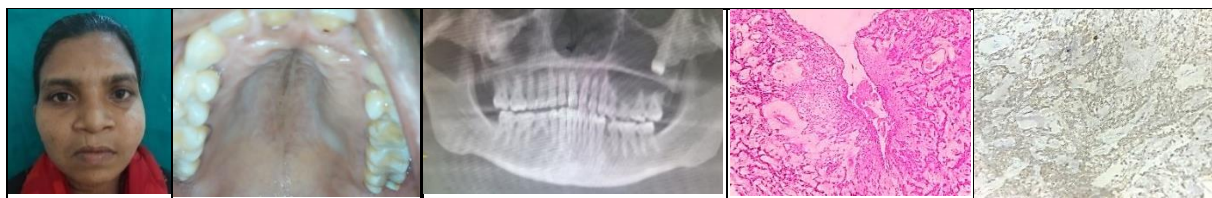

Fig 1. (a) Extraoral photograph- shows swelling (b) Intraoral photograph- showing swelling left palatal region (c) Panoramic radiograph shows well-defined corticated expansile lesion with impacted teeth (d) H & E (10x) (e) Calretinin positive.

Case Report 2

A 30 year old female patient presents with a chief complaint of pain and swelling in lower left back region of jaw since a month. Extraoral swelling visible on left lower jaw extending upto the angle of mandible. Intraoral examination revealed obliteration of buccal vestibule, hard and firm swelling on palpable in region 46 , distal caries with 46. Radiographically showed ill defined radiolucency with 45 to 48. Root resorption with 45.

Histologically Non keratinised stratified squamous epithelium with fibrocellular connective tissue stroma. Peripheral columnar to cuboidal cells with hyperchromatic nuclei & reverse polarity suggestive of ameloblast like cells & centrally placed stellate reticulum like cells.

Final diagnosis based on histopathological finding & clinical examination final diagnosis was given as radicular cyst. Provisional diagnosis given as radicular cyst, odontogenic island showing peripheral tall columnar to cuboidal cells with hyperchromatic nuclei & reverse polarity suggestive of ameloblast like cells & centrally placed stellate reticulum like cells. Immunostaining of calretinin positive .

Positive Immunostaining of calretinin suggestive provisional diagnosis as ameloblastoma.

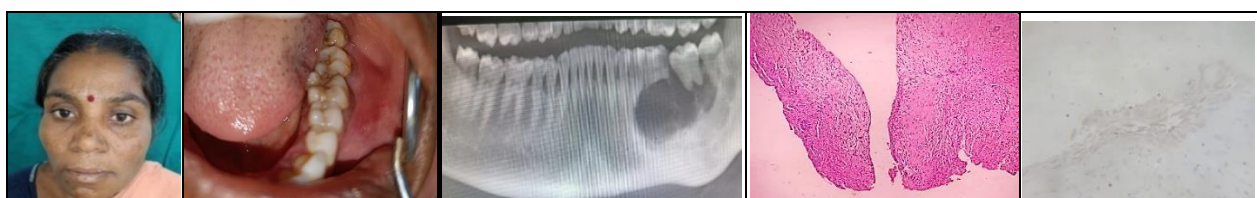

Fig 2. (a) Extraoral photograph shows swelling on left lower jaw (b) Intraoral photograph showing swelling on left lower vestibular region with 35,36 (c) Panoramic radiograph shows well-defined corticated expansile lesion with root resorption 34,35,36(d) H & E (10x) (e) Calretinin positive.

Case Report 3-

A 70-year-old male patient presented with the chief complaint of an unhealed wound in his mouth persisting for six months, following the self-extraction of a loose upper right molar. Extraoral examination revealed a diffuse swelling over the right maxillary sinus region extending to the nose, which had gradually increased in size. The patient also experienced numbness over the right maxillary sinus region, a blocked nostril, and decreased hearing on the same side as the lesion. Intraoral examination showed an unhealed socket at the site of tooth 17, with necrotic bone inside and everted margins surrounding the socket. Contrast-enhanced computed tomography (CT) revealed an ill-defined, heterogeneously enhancing neoplastic mass involving the right maxillary sinus.

An enclosed mass made of isomorphic basaloid cells producing tubular and trabecular structures within a sparse stroma was discovered during an incisional biopsy. Two different cell populations were visible in these formations, which were spotted penetrating the surrounding epithelium: the center round to ovoid cells and the peripheral tall columnar cells. A large area of the lesion had a stellate reticulum-like appearance due to the discohesiveness of the core cells.

In this case, a provisional diagnosis of basal cell adenoma mimicking ameloblastoma was made, with a differential diagnosis of basal cell adenocarcinoma. Immunostaining for calretinin helped rule out ameloblastoma.

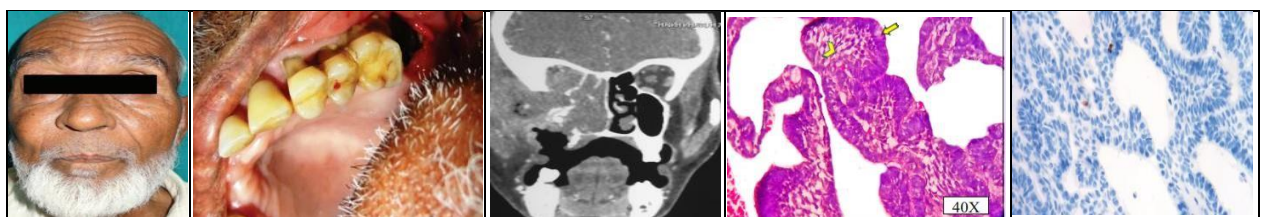

Fig 3. (a) Extraoral photograph (b) Intraoral photograph showing swelling left upper buccal vestibular region with 25,26 (c) Computed tomogram (coronal view) shows a well-defined osteolytic lesion (d) H & E (40x) (e) Calretinin negative.

Discussion-

“Calretinin, a calcium-binding protein, is widely distributed in various normal and neoplastic tissues. It is the most specific and sensitive marker for both benign and malignant mesothelial cells. The expression of calretinin in peripheral ameloblast-like cells differs from its expression during normal odontogenesis. During normal odontogenesis, the inner enamel epithelial (IEE) cells fail to mature into functional secretory ameloblasts. This failure has been attributed to

mutations in genes encoding various enamel proteins, including ameloblastin, which play crucial roles in enamel formation. These mutations disrupt the normal process of enamel formation, contributing to the characteristic histological features of ameloblastoma. Ameloblastin has been shown to play a role in the cytodifferentiation of IEE cells. The presence or absence of calretinin can serve as a marker for the differentiation status of these cells during tooth development. Immunopositivity for calretinin was confined to stellate reticulum-like cells, with prominent staining around microcysts and macrocysts. The peripheral ameloblast-like cells were negative. These findings are consistent with previous observations” [7].

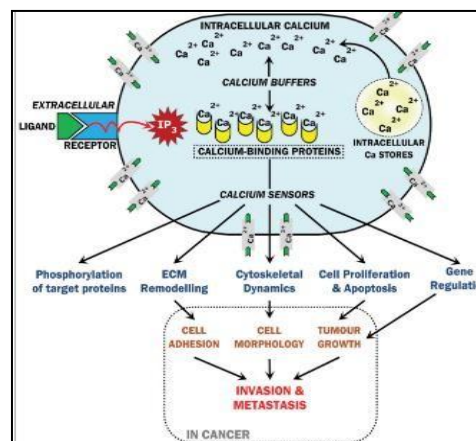


Fig 4: Mechanism of action of calretinin

Odontogenic lesions arise from the tooth-producing apparatus or its remnants and may originate from odontogenic epithelium and/or ectomesenchyme. The WHO 2017 classification system categorizes odontogenic lesions based on their origin as epithelial, mesenchymal, or a combination of both. These lesions exhibit variable clinical and biological behaviors, which can complicate diagnosis and sometimes lead to significant confusion.

“Ameloblastoma is a benign, locally aggressive epithelial odontogenic tumor with the potential for local invasion and metastasis to distant sites such as the lungs and kidneys. It accounts for about 14% of all jaw tumors and cysts and is considered the most common odontogenic tumor, typically occurring between the ages of 30 and 60 years. However, it is actually the second most common odontogenic tumor after odontoma. Radiographically, ameloblastoma usually presents as an expansile, radiolucent, multiloculated cystic lesion with a characteristic "soap bubble" or "honeycomb" appearance”¹²

According to Ide et al. (2001), “a lesion exhibiting the combined histopathological characteristics of two or more previously recognized odontogenic tumors and/or cysts of different categories is termed a hybrid lesion”.⁶

Alaeddini et al. also found that “calretinin immunoreactivity was positive only for ameloblastoma when compared to calcifying epithelial odontogenic tumour, adenomatoid odontogenic tumour, ameloblastic fibroma, and odontogenic myxoma, stating that this protein may have a role in the transition of the dental lamina remnants to ameloblastoma. They hypothesized that calretinin may be one of the factors responsible for the differences between this aggressive neoplasm and other odontogenic tumors”.⁴

Altini et al. stated that “the better the differentiation of the epithelium was, the lesser the expression of calretinin occurred in their study, where they found little or no immunostaining in those cases of unicystic ameloblastoma that were lined by typical ameloblastic epithelium, while the epithelium which completely lacked ameloblastic features frequently expressed calretinin. Hence they indicated that calretinin expression in some cells varied according to their metabolic activity and may be lost when this activity changes”.⁷

Coleman et al. observed “intense positive staining in both areas of epithelial lining and areas with typical ameloblastic features in unicystic ameloblastoma, which indicated that although the metaplastic cyst linings may have lost their typical ameloblastic features, the cells have retained their immunophenotypic characteristics resulting in the continued expression of calretinin”.⁴

Altini et al., Coleman et al., De Villiers et al. and Sundaragiri et al. found positive staining in both unicystic ameloblastoma and ameloblastoma, whereas none of the odontogenic cysts linings showed positive staining.^{7,4,8}

Present study suggests that calretinin may be used as a specific immunohistochemical marker for ameloblastic epithelium as calretinin positivity was observed exclusively in ameloblastomas & the expression of calretinin might be recapitulating dental ontogeny.

Conclusion -

Calretinin is an unequivocal diagnostic marker for ameloblastoma and plays a role in the transition of the epithelial lining of odontogenic cysts to ameloblastoma epithelium. Therefore, its utility as a diagnostic adjunct is crucial in the differential diagnosis of ameloblastoma and other odontogenic lesions. This distinction is essential for determining appropriate treatment protocols, as different lesions require different approaches, which can have serious functional and esthetic consequences for patients. Consequently, calretinin expression levels can significantly impact treatment planning and patient outcomes.

Ethical Approval:

As per international standards or university standards written ethical approval has been collected and preserved by the author(s).

Consent

As per international standards or university standards, patient(s) written consent has been collected and preserved by the author(s).

References -

1. Soluk-Tekkesin M, Wright JM. The World Health Organization Classification of Odontogenic Lesions: A Summary of the Changes of the 2022 (5th) Edition. Turk Patoloji Derg. 2022;38(2):168-184. doi: 10.5146/tjpath.2022.
2. Rudra raju A, Venigalla A, Babburi S, Soujanya P, Subramanyam RV, Lakshmi KR. Calretinin expression in odontogenic cysts and odontogenic tumors and the possible role of calretinin in pathogenesis of ameloblastoma. J Oral Maxillofac Pathol

2019;23:349-55.

3. Varshney A, Aggarwal S, Gill SK, Aggarwal A, Jaiswal Y, Sharma J. Comparison of calretinin expression in dentigerous cysts and ameloblastoma: An immunohistochemical study. *Natl J Maxillofac Surg.* 2020 Jul-Dec;11(2):224-230.
4. Coleman H, Altini M, Ali H, Doglioni C, Favia G, Maiorano E. Use of calretinin in the differential diagnosis of unicystic ameloblastomas. *Histopathology* 2001;38:312-7.

5. Alaeddini M, Etemad-Moghadam S, Baghaili F. Comparative expression of calretinin in selected odontogenic tumours: A possible relationship to histogenesis. *Histopathology* 2008;52:299-304.
6. Coleman H, Altini M, Ali H, Doglioni C, Favia G, Maiorano E. Use of calretinin in the differential diagnosis of unicystic ameloblastomas. *Histopathology* 2001;38:312-7.
7. Altini M, Coleman H, Doglioni C, Favia G, Maiorano E. Calretinin expression in ameloblastomas. *Histopathology* 2000;37:27-32.
8. DeVilliers P, Liu H, Suggs C, Simmons D, Daly B, Zhang S. Calretinin expression in the differential diagnosis of human ameloblastoma and keratocystic odontogenic tumor. *Am J Surg Pathol* 2008;32:256-60.
9. Sundaragiri SK, Chawda J, Gill S, Odedra S, Parmar G. Calretinin expression in unicystic ameloblastoma: An aid in differential diagnosis. *J Oral Biosci* 2010;52:164-9.
10. Mistry D, Altini M, Coleman HG, Ali H, Maiorano E. The spatial and temporal expression of calretinin in developing rat molars (*Rattus norvegicus*). *Arch Oral Biol* 2001;46:973-81.
11. Gomes CC, Duarte AP, Diniz MG, Gomez RS. Review article: Current concepts of ameloblastoma pathogenesis. *J Oral Pathol Med* 2010;39:585-91.
12. Dunfee BL, Sakai O, Pistey R, Gohel A. Radiologic and pathologic characteristics of benign and malignant lesions of the mandible *Radiographics*. 2006;26:1751-68
13. Margaritescu C, Mercut V, Mogoanta L, Florescu M, Simionescu C, Cionca L, et al. Salivary gland Basal cell adenomas – Immunohistochemical evaluation of four cases and review of the literature. *Rom J Morphol Embryol* 2005;46:29-40.