

Calretinin -An Explicit Marker For Ameloblastoma

Abstract

We report 3 cases of dentigerous cyst showing ameloblastomatous changes, radicular cyst revealing ameloblastoma like features and Basal cell adenoma mimicking ameloblastoma. Odontogenic cysts and tumors are a diverse group of lesions that arise from the tooth forming apparatus and its remnants. It represents a wide spectrum of clinical characteristics ranging from benign to malignant. Immunopositivity of calretinin was confined to stellate reticulum -like cells, with prominent staining around microcysts and macrocysts. The peripheral ameloblast -like cells were negative. These finding were similar to the observations reported previously. its utility as diagnostic adjunct is crucial in the differential diagnosis of ameloblastoma and other odontogenic lesion. This distinction is essential for determining appropriate treatment protocol as different lesion require different treatment approaches with potentially serious functional and esthetic consequences for patient. Therefore, calretinin expression level can significantly impact treatment planning & patient outcome.

Keywords: macrocysts, Immunopositivity, stellate reticulum, ameloblastomatous changes

INTRODUCTION

Odontogenic cysts and tumors are a diverse group of lesions that arise from the tooth forming apparatus and its remnants. It represent a wide spectrum of clinical characteristics ranging from benign to malignant. On occasion, the morphological and histopathologic patterns of this lesions mimic each other, and it is very difficult to make a definitive diagnosis. Several markers have been studied in odontogenic lesions as specific molecular markers which are characteristic of particular cellular events.

Calretinin is a calcium-binding protein (CaBp) of 29-kilodalton (kDa). CaBp acts as a mediator of signaling intracellular calcium ions, considered as an important second messenger intervening in several cellular processes, which includes proliferation and differentiation. It is a specific IHC marker for neoplastic ameloblastic epithelium and has a role in the transition of the epithelial lining of the odontogenic cyst to ameloblastomatous epithelium. It may act as a diagnostic tool for differentiating cystic odontogenic lesions from ameloblastic tumors.

Herein, reporting 3 cases, case- 1 dentigerous cyst showing ameloblastomatous changes, case- 2 radicular cyst revealing ameloblastoma like features and case-3 Basal cell adenoma mimicking ameloblastoma. So, to confirm the final diagnosis, Immunohistochemical marker (calretinin)applied which showed positive expression in case 1 & case 2 while negative immunostaining for case 3 which ruled out to be ameloblastoma.

CASE REPORT 1

A 20 year female patient with chief complaint of pain and swelling in upper left back of jaw since one year. Extraorally, the swelling extended superoinferiorly from zygoma region to the corner of mouth, anteroposteriorly from ala of nose to mid zygoma region . Intraorally swelling was seen on left palatal side which was swelling is soft, erythematous , soft & fluctuant on palpation. It extended from 21-24 leading to obliteration of buccal vestibule.

Histologically, 2-5 cell layered Non keratinized stratified squamous epithelium with absence of rete pegs. Loose, haphazardly arranged collagen fibre bundles with mild degree of chronic inflammatory cells consisting lymphocytes & plasma cells. Few odontogenic epithelial islands showed peripheral cells reverse polarity and hyperchromatic nuclei suggestive of ameloblastomatous epithelium.

In case 1: On incisional biopsy, the initial diagnosis suggested an infected dental cyst. Notably ,a few odontogenic islands exhibited reverse polarity & hyperchromatic nuclei characteristic of ameloblastomatous epithelium, however with calretinin upon further examination the biopsy results indicated features consistent with ameloblastoma.

Positive immunostaining of calretinin suggestive of provisional diagnosis as ameloblastoma.

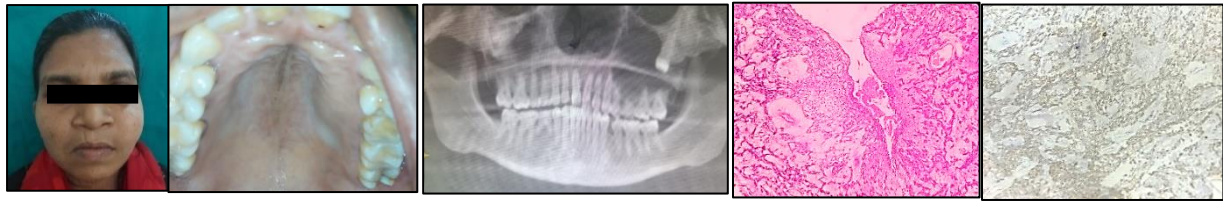

Fig 1. (a) Extraoral photograph- shows swelling (b) Intraoral photograph showing swelling left palatal region (c) Panoramic radiograph shows well-defined corticated expansile lesion with impacted teeth (d) H & E (10x) (e) Calretinin positive.

CASE REPORT 2

A 30 Year female patient with a chief complaint of pain and swelling in lower left back region of jaw since a month. Extraoral swelling visible on left lower jaw extending upto the angle of mandible. Intraoral examination revealed obliteration of buccal vestibule, hard and firm swelling on palpable in region 46 , distal caries with 46. Radiographically showed ill defined radiolucency with 45 to 48. Root resorption with 45.

Histologically Non keratinised stratified squamous epithelium with fibrocellular connective tissue stroma. Peripheral columnar to cuboidal cells with hyperchromatic nuclei & reverse polarity suggestive of ameloblast like cells & centrally placed stellate reticulum like cells.

Final diagnosis based on histopathological finding & clinical examination final diagnosis was given as radicular cyst. Provisional diagnosis given as radicular cyst, odontogenic island showing peripheral tall columnar to cuboidal cells with hyperchromatic nuclei & reverse polarity suggestive of ameloblast like cells & centrally placed stellate reticulum like cells. Immunostaining of calretinin positive .

Positive Immunostaining of calretinin suggestive provisional diagnosis as ameloblastoma.

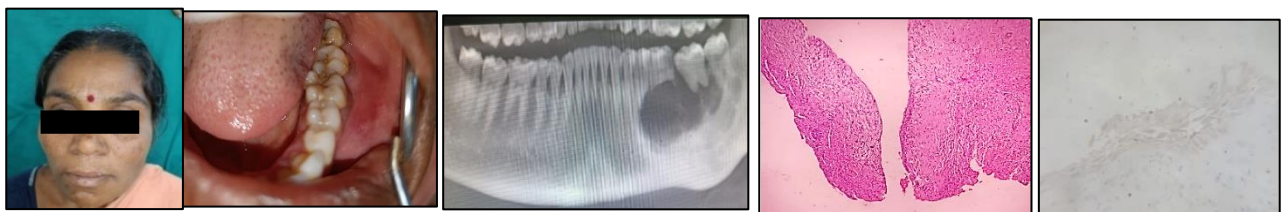

Fig 2. (a) Extraoral photograph shows swelling on left lower jaw (b) Intraoral photograph showing swelling on left lower vestibular region with 35,36 (c) Panoramic radiograph shows well-defined corticated expansile lesion with root resorption 34,35,36(d) H & E (10x) (e) Calretinin positive.

CASE REPORT 3-

A 70-year-old male patient reported with the chief complaint of an unhealed wound in the mouth since 6 months narrating history of pulling out his loose upper right molar by himself. Extraoral examination revealed diffuse swelling over the right maxillary sinus region extending over the nose which gradually increased in size. Numbness over the right maxillary sinus region, blocked nostril and decreased hearing from the same side of the lesion were also observed. Intraoral examination revealed an unhealed socket of 17 with necrosed bone inside with everted margin surrounding the socket.

Contrast-enhanced computed tomography revealed, an ill-defined heterogeneously enhancing neoplastic mass involving the right maxillary sinus.

Incisional biopsy showed, an encapsulated mass consisting of isomorphic basaloid cells forming trabecular and tubular structures in a scanty stroma. These structures were seen infiltrating into the overlying epithelium and showed two cell populations: peripheral tall columnar and central round to ovoid cells. The central cells displayed discohesiveness giving stellate reticulum-like appearance in a considerable portion of the lesion.

In case 3: provisional diagnosis given as basal cell adenoma mimicking ameloblastoma. differential diagnosis of basal cell adenocarcinoma. Immunostaining of calretinin helped to rule out ameloblastoma.

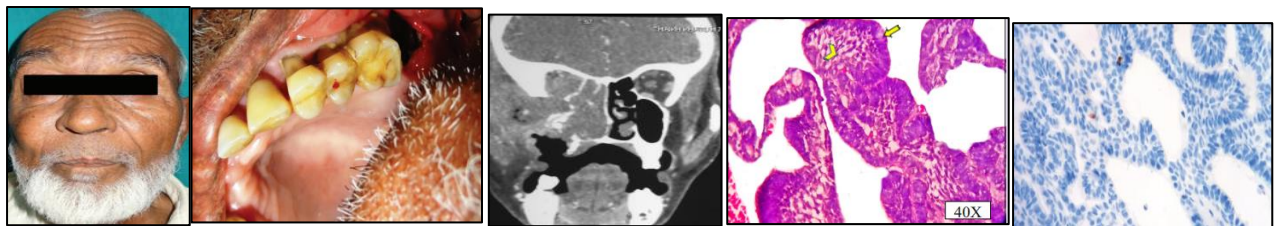
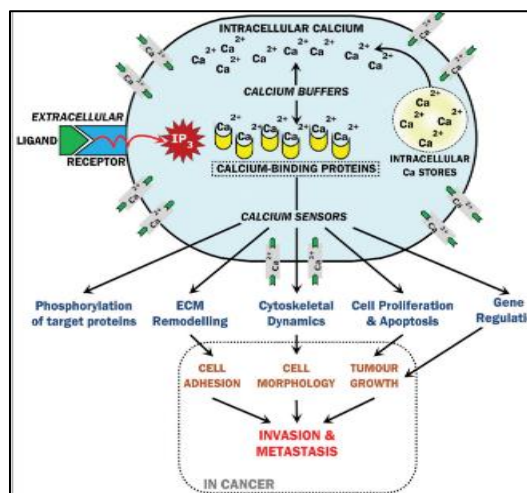


Fig 3. (a) Extraoral photograph (b) Intraoral photograph showing swelling left upper buccal vestibular region with 25,26 (c) Computed tomogram (coronal view) shows a well-defined osteolytic lesion (d) H & E (40x) (e) Calretinin negative.

DISCUSSION-

Calretinin, a calcium -binding protein, has a widespread distribution in many normal and neoplastic tissues. Calretinin most specific and sensitive marker for both benign and malignant mesothelial cells.¹ Expression of calretinin in peripheral ameloblasts like cells differ from its expression during normal odontogenesis. The inner enamel epithelial cells fails to reach the functional maturation as secretory ameloblasts. This inability, has been attributed to the mutation in gene encoding various enamel protein including ameloblastin which plays crucial roles in enamel formation during normal odontogenesis. These mutation disrupts the normal process of enamel formation, contribution to the characteristic histological features of ameloblastoma. Ameloblastin has been shown to play a role in the cytodifferentiation of IEE cells. The presence or absence of calretinin can serve as a marker for the differentiation status of these cells during tooth development.

Immunopositivity of calretinin was confined to stellate reticulum -like cells, with prominent staining around microcysts and macrocysts. The peripheral ameloblast -like cells were negative. These finding were similar to the observations reported previously.



Mechanism of action of calretinin

Odontogenic lesions are group of lesions arising from the tooth -producing apparatus or its remnants. They may originate from odontogenic epithelium and /or ectomesenchyme. Therefore, WHO 2017 odontogenic lesion classified on basis of origin as epithelial, mesenchymal or both.

These lesion have variable clinical & biological behaviors which may lead to difficulties in diagnosis with occasional serious confusion. Ameloblastoma is a benign, locally aggressive epithelial odontogenic tumor. It has the potential to local invasion and produce metastasis to distant sites such as lungs and kidneys. It constitutes about 14% of all jaw tumors and cysts. Ameloblastoma is as the most common odontogenic tumor, typically occurring between ages of 30 and 60 years. However it actually considered the second most common odontogenic tumor after odontoma. Radiographically ameloblastoma typically presents as an expansile, radiolucent, multiloculated cystic lesion, with a characteristic “soap bubble or honey comb” like appearance.¹¹

According to Ide F et al (2001) “A lesion showing the combined histopathological characteristics of two or more previously recognized odontogenic tumors and/or cysts of different categories is called Hybrid lesions.”

Alaeddini et al. also found that calretinin immunoreactivity was positive only for ameloblastoma when compared to calcifying epithelial odontogenic tumour, adenomatoid odontogenic tumour, ameloblastic fibroma, and odontogenic myxoma, stating that this protein may have a role in the transition of the dental lamina remnants to ameloblastoma. They hypothesized that calretinin may be one of the factors responsible for the differences between this aggressive neoplasm and other odontogenic tumors.⁴

Altini et al. stated that the better the differentiation of the epithelium was, the lesser the expression of calretinin occurred in their study, where they found little or no immunostaining in those cases of unicystic ameloblastoma that were lined by typical ameloblastic epithelium, while the epithelium which completely lacked ameloblastic features frequently expressed calretinin. Hence they indicated that calretinin expression in some cells varied according to their metabolic activity and may be lost when this activity changes.⁶

Coleman et al. observed intense positive staining in both areas of epithelial lining and areas with typical ameloblastic features in unicystic ameloblastoma, which indicated that although the metaplastic cyst linings may have lost their typical ameloblastic features, the cells have retained their immunophenotypic characteristics resulting in the continued expression of calretinin.³

Altini et al., Coleman et al., De Villiers et al. and Sundaragiri et al. found positive staining in both unicystic ameloblastoma and ameloblastoma, whereas none of the odontogenic cysts linings showed positive staining.^{6,3,7}

Present study suggests that calretinin may be used as a specific immunohistochemical marker for ameloblastic epithelium as calretinin positivity was observed exclusively in ameloblastomas & the expression of calretinin might be recapitulating dental ontogeny.

CONCLUSION-

Calretinin serves as an unequivocal diagnostic marker for ameloblastoma and plays a role in the transition of the epithelial lining of the odontogenic cyst to ameloblastoma epithelium. Hence, its utility as diagnostic adjunct is crucial in the differential diagnosis of ameloblastoma and other odontogenic lesion. This distinction is essential for determining appropriate treatment protocol as different lesion require different treatment approaches with potentially serious functional and esthetic

consequences for patient. Therefore, calretinin expression level can significantly impact treatment planning & patient outcome.

REFERENCES –

1. Rudra raju A, Venigalla A, Babburi S, Soujanya P, Subramanyam RV, Lakshmi KR. Calretinin expression in odontogenic cysts and odontogenic tumors and the possible role of calretinin in pathogenesis of ameloblastoma. *J Oral Maxillofac Pathol* 2019;23:349-55.
2. Varshney A, Aggarwal S, Gill SK, Aggarwal A, Jaiswal Y, Sharma J. Comparison of calretinin expression in dentigerous cysts and ameloblastoma: An immunohistochemical study. *Natl J Maxillofac Surg.* 2020 Jul-Dec;11(2):224-230.
3. Coleman H, Altini M, Ali H, Doglioni C, Favia G, Maiorano E. Use of calretinin in the differential diagnosis of unicystic ameloblastomas. *Histopathology* 2001;38:312-7.
4. Alaeddini M, Etemad-Moghadam S, Baghahi F. Comparative expression of calretinin in selected odontogenic tumours: A possible relationship to histogenesis. *Histopathology* 2008;52:299-304.
5. Coleman H, Altini M, Ali H, Doglioni C, Favia G, Maiorano E. Use of calretinin in the differential diagnosis of unicystic ameloblastomas. *Histopathology* 2001;38:312-7.
6. Altini M, Coleman H, Doglioni C, Favia G, Maiorano E. Calretinin expression in ameloblastomas. *Histopathology* 2000;37:27-32.
7. DeVilliers P, Liu H, Suggs C, Simmons D, Daly B, Zhang S. Calretinin expression in the differential diagnosis of human ameloblastoma and keratocystic odontogenic tumor. *Am J Surg Pathol* 2008;32:256-60.
8. Sundaragiri SK, Chawda J, Gill S, Odedra S, Parmar G. Calretinin expression in unicystic ameloblastoma: An aid in differential diagnosis. *J Oral Biosci* 2010;52:164-9.
9. Mistry D, Altini M, Coleman HG, Ali H, Maiorano E. The spatial and temporal expression of calretinin in developing rat molars (*Rattus norvegicus*). *Arch Oral Biol* 2001;46:973-81.
10. Gomes CC, Duarte AP, Diniz MG, Gomez RS. Review article: Current concepts of ameloblastoma pathogenesis. *J Oral Pathol Med* 2010;39:585-91.
11. Dunfee BL, Sakai O, Pistey R, Gohel A. Radiologic and pathologic characteristics of benign and malignant lesions of the mandible *Radiographics.* 2006;26:1751–68

