

Case report

Malignant hypertension. Importance of the fundus in emergency services”

Abstract :

In this article, we highlight the importance of the ophthalmologist in the diagnosis of hypertensive emergencies. It is crucial to know how to make the correct diagnosis and correctly refer the patient. We report a case of a 23-year-old female patient with a history of undocumented nephropathy since the age of 10 years that was admitted for a sudden decrease in visual acuity and persistent headaches that did not respond to pain medication. Diagnosis is often difficult and delayed, the role of the ophthalmologist remains crucial, as our case illustrates. It underlines the urgent need to reduce blood pressure, and highlights the importance of regular follow-up and compliance with treatment to prevent serious complications

keywords: malignant, hypertension, retinopathy

Introduction :

Malignant hypertension may present with retinopathy, choroidopathy, and optic neuropathy. Flame-shaped retinal hemorrhages, an early finding, are due to smooth muscle necrosis and bleeding along the nerve fiber layer. Hypertensive optic neuropathy is a late finding. Optical coherence tomography is a relatively new imaging technique for evaluating retinal thickness and the location of pathology in patients with malignant hypertension [9]. Ophthalmologic disease most commonly affects the retina, choroid, and optic nerve and has a variety of presentations both acute and chronic [10].

Presentation of case:

A 23-year-old female patient with a history of undocumented nephropathy since the age of 10 years was admitted for a sudden decrease in visual acuity and persistent headaches that did not respond to pain medication. The patient had previously stopped taking her anti-hypertensive medication 5 years ago due to poor compliance. Upon examination, it was found that her visual acuity was severely impaired in both eyes. Fundus examination revealed bilateral **disc edema**, with more pronounced symptoms on the left. The fundus also showed flaming hemorrhages and dry exudates, as well as retinal serous detachment with a stellate appearance of the macula. Additionally, there was significant narrowing of the entire arterial vascular tree (figure 1). OCT showed retinal serous detachment with cystoid oedema (figure 2). During the general examination, it was discovered that her blood pressure was 200mmHg systolic and 150mmHg diastolic. After quickly stabilizing her blood pressure, further tests were performed, including urea and creatinine levels in the blood, as well as a complete blood ionogram, which did not reveal any abnormalities. A cerebral CT scan ruled out

intracranial expansion, hydrocephalus, and venous thrombosis. The patient was then referred to the nephrology department for further management.

Discussion :

Although rare, malignant arterial hypertension (MAHT) is a condition with a relatively stable incidence rate (1) and has a severe prognosis if not adequately treated (2).

The majority of cases of malignant hypertension are in fact cases of essential hypertension (3), like that of our patient.

Malignant hypertension is characterized by a sudden increase in blood pressure, accompanied by grade III or IV retinopathy (4).

The characteristic lesions observed on the fundus can be used to diagnose malignant hypertension (5).

Ophthalmological involvement is defined by stage III or IV of the Keith and Wagener classification on the fundus. This is characterized by the presence of retinal hemorrhages and exudates, as well as optic disc edema, all of which occur bilaterally (6).

The prognosis of hypertensive retinopathy is generally favorable. Characteristic retinal changes tend to resolve rapidly, within two to three months, with early antihypertensive treatment. However, it's important to stress that not all malignant retinopathies are fully reversible(7).

Malignant hypertension is a serious, life-threatening emergency. It requires immediate blood pressure reduction. Ocular changes generally disappear with the use of systemic antihypertensive drugs (8).

The mortality rate for untreated malignant hypertension is as high as 50% within 2 months of diagnosis, and nearly 90% by the end of 1 year.

Conclusion:

Malignant hypertension requires rapid diagnosis and management because of the vital risk involved. Although diagnosis is often difficult and delayed, the role of the ophthalmologist remains crucial, as our case illustrates. It underlines the urgent need to reduce blood pressure, and highlights the importance of regular follow-up and compliance with treatment to prevent serious complications and death.

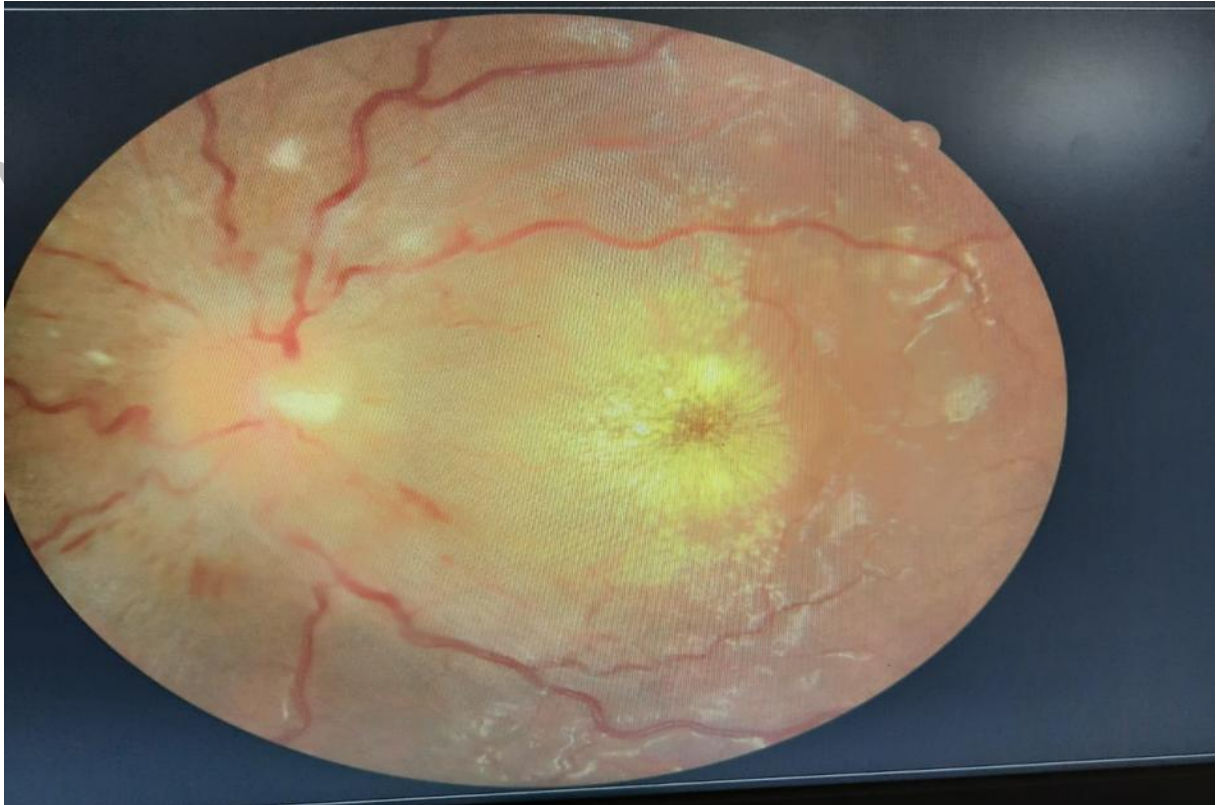
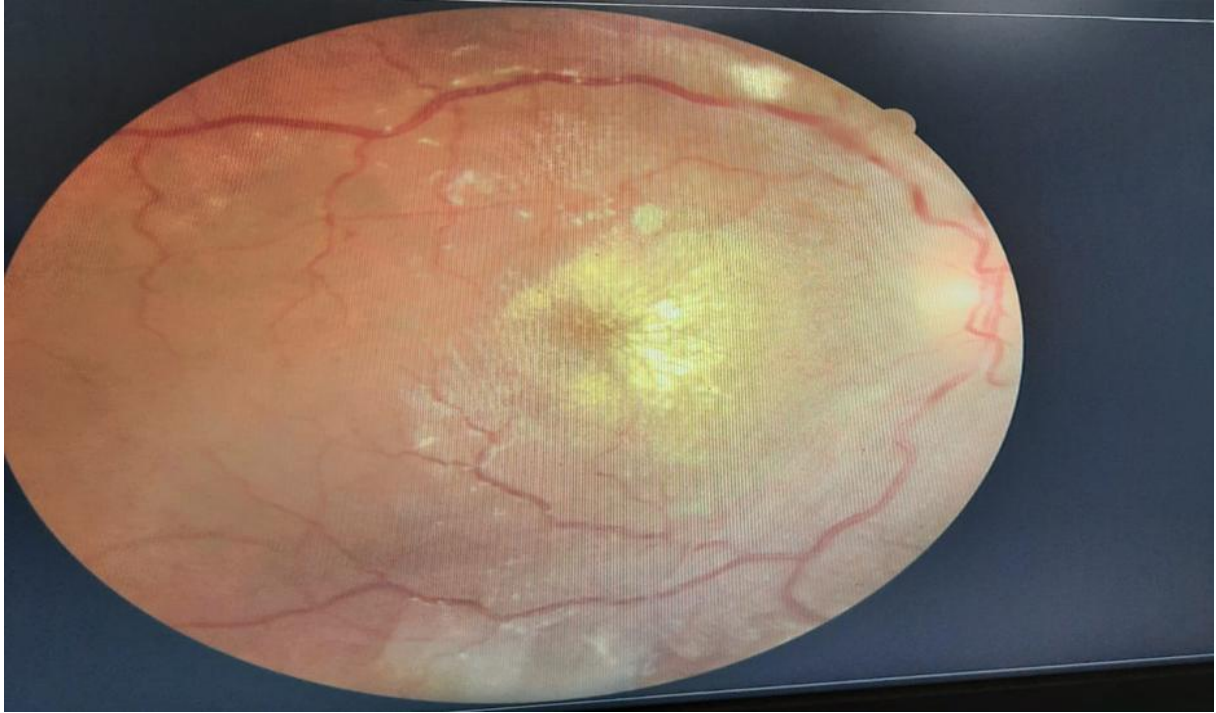
Figure 1: showed bilateral papilledema dry exudates, as well as retinal serous detachment with a stellate appearance of the macula

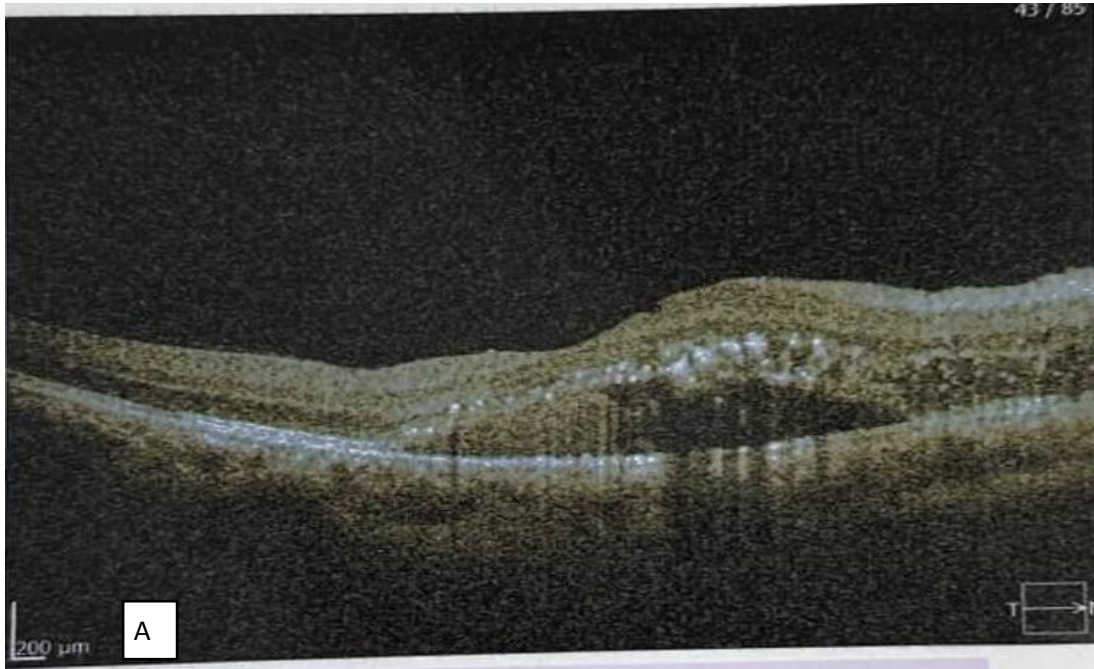


Figure 2: OCT showed retinal serous detachment with cystoid oedema **A:**right eye **B:**left eye

Références :

1. Lip GY, Beevers M, Beevers G. The failure of malignant hypertension to decline: a survey of 24 years' experience in a multiracial population in England. *J Hypertens*. nov 1994;12(11):1297-305.
2. 2. Boulestreau R, Cremer A, Lorthioir A, Rubin S, Tharaux PL, Persu A, et al. Malignant arterial hypertension, a promising future. *The Medical Press*. Dec 2019;48(12):1439-44
3. 3. Predisposing factors for severe, uncontrolled hypertension in an inner-city minority population. Shea S, Misra D, Ehrlich MH, Field L, Francis CK. *N Engl J Med*. 1992;327:776–781
4. 4. Keith NM, Wagener HP, Barker NW (1974) Some different types of essential hypertension: their course and prognosis. *Am J Med Sci* 268:336–45
5. 5. Kitiyakara C, Guzman NJ (1998) Malignant hypertension and hypertensive emergencies. *J Am Soc Nephrol* 9:133–42
6. 6. Boulestreau R, Cremer A, Lorthioir A, Rubin S, Tharaux PL, Persu A, et al. Malignant arterial hypertension, a promising future. *The Medical Press*. Dec 2019;48(12):1439-44
7. 7. Multimodal imaging of hypertensive chorioretinopathy by swept-source optical coherence tomography and optical coherence tomography angiography: case report. Rotsos T, Andreanos K, Blounas S, Brouzas D, Ladas DS, Ladas ID. *Medicine (Baltimore)* 2017;96:0
8. 8. Treatment of acute severe hypertension: current and newer agents. Varon J. *Drugs*. 2008;68:283–297.
9. 9. Hammond S, Wells JR, Marcus DM, Prisant LM. Ophthalmoscopic findings in malignant hypertension. *The Journal of Clinical Hypertension*. 2006 Mar;8(3):221-3.
10. 10. Zhu I, Mieler WF, Kim SK, Jakobiec FA. Hypertension and Its Ocular Manifestations. In: Albert and Jakobiec's Principles and Practice of Ophthalmology 2022 Apr 23 (pp. 6991-7016). Cham: Springer International Publishing.