

# **IMPACT OF COMBINING IMMUNE CHECKPOINT INHIBITORS WITH CHEMOTHERAPY IN THE MANAGEMENT OF ADVANCED SEROUS ENDOMETRIAL ADENOCARCINOMA**

## **Abstract:**

Chemo-immunotherapy is a relatively recent approach to the treatment of advanced or relapsed endometrial cancer. The aim of these therapies is to remove immune suppression, enabling the immune system to better recognise and destroy cancer cells. We report a clinical case of stage 4 endometrial cancer in a 69-year-old patient with several comorbidities in whom we obtained a complete response after four cycles of paclitaxel+carboplatin combined with pembrolizumab followed by maintenance immunotherapy. Immunotherapy combined with chemotherapy is a relatively recent approach to the treatment of advanced or relapsed endometrial cancer. This case report demonstrates the importance of adding immunotherapy to chemotherapy in the management of advanced endometrial cancer.

**Key words:** advanced endometrial cancer, immunotherapy, chemotherapy, complete clinical response.

## **INTRODUCTION :**

Endometrial cancer is one of the few malignant diseases whose incidence and mortality are currently on the rise. By 2040, it is expected to become the third most common cancer and the fourth leading cause of cancer death in women.<sup>1</sup> It has a favourable prognosis in the early stages, but a poor prognosis in the advanced stages (metastatic or relapsed), with few treatment options.<sup>2</sup>

Metastatic and/or relapsed endometrial cancer therefore remains a fairly frequent and serious situation, requiring multidisciplinary management.<sup>3</sup> The combination of pembrolizumab and cytotoxic chemotherapy resulted in clinically significant improvements in progression-free survival and overall survival in patients with several types of solid tumours<sup>4</sup> such as stage 4 lung cancer, melanoma, triple-negative breast cancer and certain digestive cancers (colon microsatellite instability (MSI) status, metastatic stomach, Programmed Death-Ligant 1 (PDL1) CPS $\geq$ 5 )<sup>7,8,9</sup>.

We report the case of a 69-year-old patient with stage 4 high-grade serous adenocarcinoma who achieved a complete pathological response with immunotherapy combined with chemotherapy.

## **CASE PRESENTATION :**

This is a 69-year-old patient, hypertensive on triple therapy (Amlodipine 10mg, Valsartan 160mg and Hydrochlorothiazide 12.5mg daily), type 2 diabetic on oral antidiabetics (Metformin 2000mg daily) having developed secondary dyslipidaemia

on atorvastatin, venous insufficiency (wearing compression stockings) and transluminal angioplasty for 15 years who consulted in July 2023 for epigastralgia, intermittent abdominal pain with transit disorders and pelvic pain associated with metrorrhagia, all evolving in a context of conservation of general condition.

As part of the aetiological work-up, the patient underwent FOGD, which was found to be without anomalies. Hysteroscopy revealed three polyps in the uterine cavity, which were resected. The histological study of this resection showed a morphological appearance in favour of a high-grade invasive serous carcinoma, with negative Human Epidermal Growth Factor Receptor 2 (HER2) (score 0), 50% positive oestrogen receptors and 100% positive Microsatellite Stability (MSS) and P53 on immunohistochemistry.

As part of the extension work-up, a thoracic-abdominopelvic CT scan showed a large peritoneal effusion, with no distant secondary lesions. An exploratory laparoscopy revealed a carcinomatous miliary covering the entire peritoneum. Several biopsies were taken, and the pathology report showed a peritoneal and epiploic location of an invasive high-grade adenocarcinoma consistent with the patient's known endometrial serous adenocarcinoma. Tumour markers: CA125: 654U/ml, CA19.9: 279 U/ml.

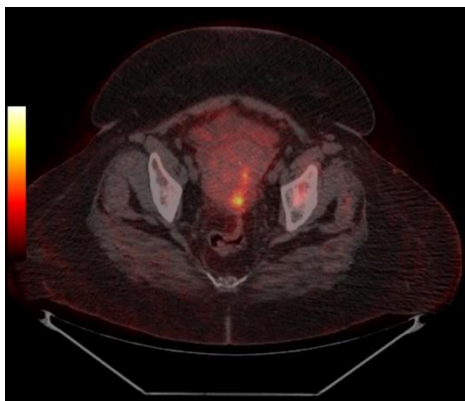
We presented a 69-year-old patient with several comorbidities presenting with high-grade serous invasive endometrial carcinoma, Microsatellite Stability Profile (MSS), P53 positive, oestrogen receptor (ER) positive, progesterone receptor (PR) negative and Human Epidermal Growth Factor Receptor 2 (HER2) negative, at stage 4 with peritoneal and epiploic localisations.

The decision to undergo chemoimmunotherapy (pembrolizumab 200mg weekly and paclitaxel 60mg/m<sup>2</sup> + carboplatin AUC2 weekly) was taken in a multidisciplinary consultation meeting. The first and fourth courses were given without paclitaxel because of peripheral neuropathy associated with her diabetes.

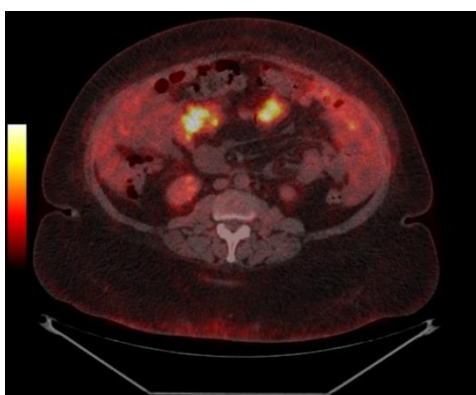
The patient's follow-up was marked by clinical intolerance to chemotherapy, requiring hospitalisation for profound asthenia, anorexia and an isolated febrile syndrome (with no clinical, biological or radiological signs of infection), and justifying reductions in the dose of chemotherapy.

The first assessment after the third cycle was in favour of a partial response on the pet scan : persistence of micronodular infiltration of the mesentery and greater omentum with macrovesicular lithiasis. We therefore decided to carry out the fourth course of treatment with carboplatin AUC 1.5 and pembrolizumab because the neuropathy persisted, followed by maintenance treatment with pembrolizumab. The patient tolerated the maintenance treatment well.

A positional emission tomography scan was carried out as part of the evaluation after the sixth course of pembrolizumab, showing the total disappearance of the abdomino-pelvic hypermetabolic foci described above, and therefore a complete response.



**Fig1** :Posterior uterine hypermetabolism



**Fig2** : peritoneal effusion and peritoneal carcinomatosis

Cycles	Date	Molecules	Symptômes	CA125:	Evaluation pet scan
<b>First cycle</b>	15-09-2023	Carboplatin +pembrolizumab	None	654U/ml	Not done
<b>Second cycle</b>	16-10-2023	Paclitaxel+carboplatin+pembrolizumab	Grade 1 fébrile neutropenia		Not done
<b>Third</b>	<b>23-11-</b>	<b>Paclitaxel+carbop</b>	<b>Grade 2</b>	<b>97U/ml</b>	<b>Partial response</b>

<b>cycle</b>	<b>2023</b>	<b>latin+pembrolizu mab</b>	<b>peripheral neuropathy</b>		
<b>Fourth cycle</b>	15-12- 2023	Carboplatin +pembrolizumab	Grade 2 peripheral neuropathy		Not done
<b>Fifth cycle</b>	05-01- 2024	pembrolizumab	Grade 1 peripheral neuropathy		Not done
<b>Sixth cycle</b>	<b>16-01- 2024</b>	<b>pembrolizumab</b>	<b>Grade 1 peripheral neuropathy</b>	<b>28U/ml</b>	<b>Complete Response with disappearance of peritoneal carcinomatosis and peritoneal effusion.</b>

**Fig 3:** patient follow-up table (side effects, molecules used and their dates, and evaluation)

## **DISCUSSION:**

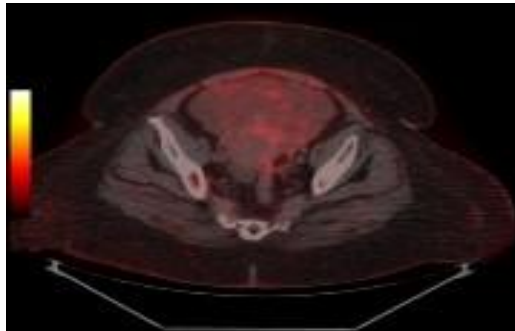
Immune checkpoint inhibitors have profoundly changed the treatment paradigm for many types of tumour, in particular by offering long-term remissions, even in the case of metastases. These immunotherapies aim to restore the activity of T lymphocytes against tumour cells, in particular by inhibiting PD1/PD-L1 interaction. As with lung and kidney carcinomas, as well as melanomas, the management of endometrial and cervical cancers has been affected by the efficacy of PD1/PD-L1 inhibitors.<sup>10</sup>

Chemo-immunotherapy is a relatively recent approach to the treatment of advanced or relapsed endometrial cancer, which raises questions about the modalities and duration of treatment. The immunotherapies most commonly used in endometrial cancer are those that target immune checkpoints, such as anti-PD-1/PD-L1 and anti-CTLA-4 antibodies.

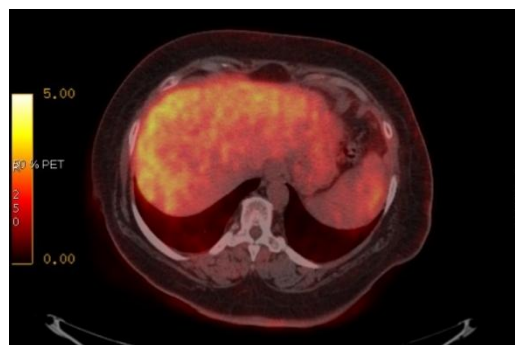
Several Immune Checkpoint Inhibitors (ICI) currently have marketing authorisation for advanced non-small cell lung cancer : pembrolizumab, nivolumab and atezolizumab. These treatments have demonstrated their efficacy in various studies, in 1st line or beyond, with varying planned durations of immunotherapy treatment: pembrolizumab was continued for a total of 35 3-week cycles (KEYNOTE 024, KEYNOTE 407, KEYNOTE 189) or 24 months (KEYNOTE 010).<sup>5</sup>

A previous trial comparing the addition of pembrolizumab to paclitaxel/carboplatin versus placebo and paclitaxel/carboplatin demonstrated that incorporating immunotherapy into the first-line treatment of patients with advanced or recurrent endometrial cancer results in better oncological outcomes, regardless of MMR status or histological findings.<sup>6</sup>

Follow-up of the patient was marked by clinical intolerance to chemotherapy, requiring hospitalisation for profound asthenia, anorexia, neutropenia, isolated febrile syndrome with no clinical, biological or radiological signs of infection, justifying reductions in carboplatin doses, and also persistent peripheral neuropathy, often grade 2, for which we carried out courses without paclitaxel. However, during maintenance treatment with pembrolizumab, the patient tolerated the treatment well.



**Fig 4:**Complete disappearance of uterine hypermetabolism.



**Fig 5 :**Complete disappearance of peritoneal carcinomatosis and peritoneal effusion.

## **CONCLUSION :**

The prognosis of advanced endometrial cancer continues to improve thanks to better multidisciplinary management and access to new innovative strategies such as immunotherapy. In patients with advanced or recurrent endometrial cancer, the addition of pembrolizumab to standard chemotherapy resulted in significantly longer progression-free survival than with chemotherapy alone. However, the duration of treatment remains a matter for debate.

## **REFERENCES:**

1. Rebecca L. Siegel, MPH; Kimberly D. Miller. Cancer Statistics, 2022

Surveillance and health equity Science, American Cancer Society, Atlanta, Georgia.

2. Patricia Pautier, Fanny Pommeret, Systemic treatment of advanced endometrial cancer. *Cancer Bulletin* Volume 104, Issue 12, December 2017, pages 1046-1053.
3. Ramez N. Eskander, M.D., Michael W. Sill, Pembrolizumab plus Chemotherapy in Advanced Endometrial Cancer. *N Engl J Med* 2023;388:2159-2170.
4. Leena Gandhi, M.D., Ph.D., Delvys Rodríguez-Abreu, M.D., and col. Pembrolizumab plus Chemotherapy in Metastatic Non–Small-Cell Lung Cancer, April 16, 2018 *N Engl J Med* 2018;378:2078-2092
5. M. Ferreira , A.B. Cortot, How long should immunotherapy for lung cancer be taken? *Revue des Maladies Respiratoires Actualités* Volume 12, Issue 2, Supplement 2, December 2020, Pages 2S339-2S343.
6. Richard G. Moore, M.D. M. Hope, M.D., Fernanda B. Musa, M.D., Robert Mannel, M.D., Pembrolizumab plus Chemotherapy in Advanced Endometrial Cancer, March 27, 2023 *New England Journal Med* 2023;
7. Satoko Matsueda et David Y Graham ; Immunotherapy in gastric cancer, *World J Gastroenterol.* 21 February 2014; 20(7): 1657-1666
8. Shigeo Koido , Toshifumi Ohkusa , Sadamu Homma , and col. Immunotherapy for colorectal cancer; *World J Gastroenterol.* 14 December 2013; 19(46): 8531-8542
9. Véronique Debien ,Alex De Caluwé ,Xiaoxiao Wang and col. Immunotherapy in breast cancer: an overview of current strategies and perspectives; *Breast cancer npj* volume 9 , Article number : 7 ( 2023 )
10. Paula Nay, Philippe Morice, Félix Blanc-Durand. Immunotherapy in oncogynaecology. *Cancer du taureau* 2023 avril;110(4):395-401.