

Psychiatric presentation of a severe vitamin B12 deficiency associated with Biermer's disease: a case report

Abstract : This case report highlights a 57-year-old female patient presenting with psychiatric symptoms such as depressive mood, social withdrawal, and apathy followed by gait disturbances and tremor, which led to the diagnosis of severe Vitamin B12 deficiency-induced encephalopathy. Despite initially displaying only psychiatric symptoms, MRI revealed cerebral leukoencephalopathy. Metabolic and auto-immune evaluation confirmed profound Vitamin B12 deficiency secondary to Biermer's disease. Treatment with Vitamin B12 replacement therapy resulted in a favorable outcome. This case underscores the importance of considering Vitamin B12 deficiency in patients with neuropsychiatric symptoms, as timely diagnosis and treatment can prevent long-term complications.

Keywords: Vitamin B12 deficiency, cobalamin, psychiatric presentation, encephalopathy, Biermer's disease.

1) Introduction :

Vitamin B12 deficiency is associated with a wide range of neuropsychiatric manifestations, ranging from subtle cognitive impairments to severe psychiatric disorders [1,2]. Deficiency in vitamin B12 can result from various factors, including inadequate dietary intake, malabsorption syndromes, and certain medications [3]. The neurological and psychiatric manifestations of vitamin B12 deficiency can manifest insidiously and mimic other conditions, posing diagnostic challenges. We report the case of a patient presenting with neuropsychiatric manifestations revealing a vitamin B12 encephalopathy secondary to Biermer's disease.

2) Case presentation:

A 57-year-old female patient, with a history of type 2 diabetes treated with insulin, was referred to our department due to a progressive behavioral disorder progressing over the past four months. Characterized by withdrawal from family, social isolation, apathy, depressed mood with episodes of spasmodic crying, and difficulty falling asleep. Subsequently, the patient experienced gait disturbances, including reduced walking perimeter, axial and limb tremors, and urinary incontinence, alongside total anorexia, asthenia, significant weight gain, and headaches without vomiting or fever. The patient denied any alcohol consumption or malnutrition.

Upon clinical examination, the patient presented disorientation in time and space, apathy, and absence of facial expressions, with slightly discolored conjunctivae and android obesity resulting in a BMI of 35. Gait was ataxic, exacerbated by eye closure. Romberg's sign was negative. Muscle strength remained intact with spastic hypertonia on the left side, accompanied by brisk reflexes in all four limbs and bilateral Babinski sign. Sensory functions were intact, and no coordination disorders were observed. Oculomotor examination showed no ophthalmoplegia or nystagmus. Assessment of higher cognitive functions revealed attention and memory deficits consistent with anterograde amnesia.

Brain MRI displayed bilateral and roughly symmetrical T2 and fluid attenuated inversion recovery (FLAIR) hyperintensities in the periventricular and periaqueductal white matter, associated with bilateral T1 hyperintensity of the striatum (Figure 1). EEG indicated a global slowing of background activity without paroxysmal anomalies. Lumbar puncture findings were unremarkable. Metabolic panel

results demonstrated normal levels of thiamine, vitamins B6, and B9, but severely decreased vitamin B12 levels at 62.50 pg/ml, associated with macrocytic anemia. The remainder of the metabolic and infectious workup returned normal results. Upper gastrointestinal endoscopy revealed erosive pan-gastritis alongside positive anti-intrinsic factor and anti-parietal cell antibodies, suggestive of Biermer's disease.

The patient was treated with a regimen of daily intramuscular injections of 5000ug of hydroxocobalamin for 10 days, followed by weekly injections for a month, and then monthly injections. The patient positively responded to the vitamin B12 replacement therapy, experiencing improvement in psychiatric symptoms and resolution of limb tremors within a three-month period.

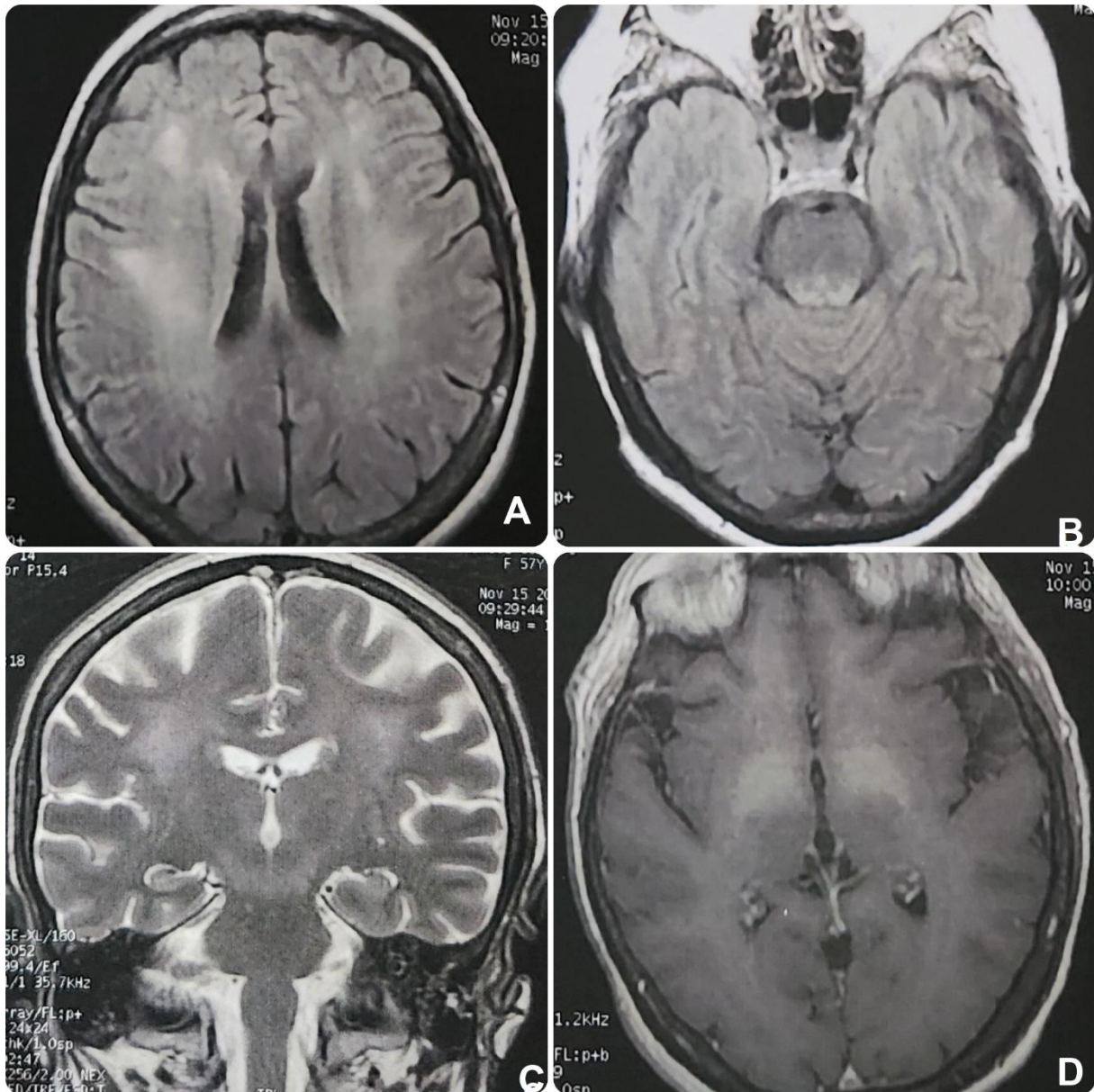


Figure 1: Cerebral MRI in axial T2 FLAIR (A,B) and in coronal T2 (C) showing periventricular and periaqueductal white matter hyperintensities. Axial T1 sequence (D) showing bilateral pallidal hyperintensity.

3) Discussion :

Vitamin B12, also known as hydroxocobalamin, serves as a pivotal cofactor for the enzymes methionine synthase and L-methylmalonyl-coenzyme A mutase. This vitamin is crucial for the development and initial myelination of the central nervous system, as well as for maintaining its normal function [3]. Deficiency in Vitamin B12 represents a significant global health issue, with prevalence rates varying across different populations and regions [3,4]. Biermer's disease, also called pernicious anemia, an autoimmune disorder characterized by the presence of anti-gastric parietal cell and anti-intrinsic factor antibodies, is the predominant cause of Vitamin B12 malabsorption [5].

Vitamin B12 deficiency can often be overlooked in patients if only total serum vitamin B12 is used as a status marker. Consequently, measurement of additional functional biomarkers is recommended, such as methylmalonic acid (MMA) and homocysteine, to accurately diagnose vitamin B12 deficiency. This is particularly pertinent for individuals with borderline vitamin B12 levels, defined as rates between 140 and 300 pmol/L, where elevated levels of MMA and/or homocysteine may provide crucial diagnostic evidence of a deficiency [6,7].

The neuropsychiatric manifestations of vitamin B12 deficiency are diverse and can affect multiple cognitive and affective domains. Cognitive impairments commonly include deficits in memory, attention, executive function, and processing speed. Psychiatric symptoms may range from subtle mood disturbances such as irritability and apathy to more severe presentations resembling depression, psychosis, or even dementia [8]. Neurological manifestations may include peripheral neuropathy, myelopathy, and optic neuropathy [9]. The heterogeneity of clinical manifestations emphasizes the necessity of conducting a comprehensive evaluation, including meticulous history-taking, thorough physical examination, and relevant laboratory testing.

Although serum levels of vitamin B12 are frequently measured, they may not consistently reflect tissue reserves or functional insufficiency. Supplementary examinations such as methylmalonic acid (MMA) and homocysteine levels may provide supplementary insights, particularly in instances of borderline vitamin B12 levels. Cerebral MRI findings are often nonspecific and should be interpreted in conjunction with the clinical context. It may reveal leukoencephalopathy with diffuse hyperintensities on T2 and FLAIR sequences in the periventricular white matter, occasionally accompanied by involvement of the basal ganglia [10,11].

In our patient, psychiatric and behavioral manifestations preceded neurological symptoms. Metabolic and autoimmune investigations, including digestive explorations, led to the diagnosis of encephalopathy due to profound Vitamin B12 deficiency secondary to Biermer's disease. Additionally, cerebral imaging in our case revealed lesions in the periaqueductal gray matter, suggesting the possibility of an association with Wernicke's encephalopathy in the setting of normal thiamine levels [12].

4) Conclusion :

Vitamin B12 deficiency can present with a spectrum of cognitive, psychiatric, and neurological symptoms, with psychiatric manifestations often playing a prominent role in diagnosis. Our case report underscores the necessity of a thorough and multidisciplinary diagnostic approach to vitamin B12 deficiency, emphasizing the importance of early recognition and treatment to prevent long-term complications and improve outcomes for affected individuals.

Consent:

As per international standards, the patient's written consent has been collected and preserved by the authors.

Ethical approval:

Not applicable.

Acknowledgments:

None.

Authors' Contributions:

This work was carried out in collaboration among all authors. YE designed the study, and wrote the manuscript. Authors YE, SS, NM, MH analyzed and interpreted the patient data regarding case presentation. Authors YB and AB supervised the study. All authors read and approved the final manuscript.

Competing interests:

The authors declare no conflict of interest in this study.

References :

1. Hector M, Burton JR. What are the psychiatric manifestations of vitamin B12 deficiency? *J Am Geriatr Soc.* 1988 Dec;36(12):1105-12. doi: 10.1111/j.1532-5415.1988.tb04397.x.
2. Domnisse J. Subtle vitamin-B12 deficiency and psychiatry: a largely unnoticed but devastating relationship? *Med Hypotheses.* 1991 Feb;34(2):131-40. doi: 10.1016/0306-9877(91)90181-w.
3. Stabler SP. Clinical practice. Vitamin B12 deficiency. *N Engl J Med.* 2013 Jan 10;368(2):149-60. doi: 10.1056/NEJMcp1113996.
4. Stabler SP, Allen RH. Vitamin B12 deficiency as a worldwide problem. *Annu Rev Nutr.* 2004;24:299-326. doi: 10.1146/annurev.nutr.24.012003.132440.
5. Htut TW, Thein KZ, Oo TH. Pernicious anemia: Pathophysiology and diagnostic difficulties. *J Evid Based Med.* 2021 May;14(2):161-169. doi: 10.1111/jebm.12435.
6. Harrington DJ. Laboratory assessment of vitamin B12 status. *J ClinPathol.* 2017 Feb;70(2):168-173. doi: 10.1136/jclinpath-2015-203502.
7. Spence JD. Metabolic vitamin B12 deficiency: a missed opportunity to prevent dementia and stroke. *Nutr Res.* 2016 Feb;36(2):109-16. doi: 10.1016/j.nutres.2015.10.003.
8. Mota A, Lázaro M, Alves R, Moreira A, Nobre M. Neuropsychiatric manifestations of vitamin B12 and folate deficiencies: Data from an inpatient psychiatric department. *European Psychiatry.* 2016;33(S1):S371-S371. doi:10.1016/j.eurpsy.2016.01.1333
9. Wolffenbuttel BHR, Wouters HJCM, Heiner-Fokkema MR, van der Klauw MM. The Many Faces of Cobalamin (Vitamin B12) Deficiency. *Mayo ClinProcInnovQual Outcomes.* 2019 May 27;3(2):200-214. doi: 10.1016/j.mayocpiqo.2019.03.002
10. Briani C, Dalla Torre C, Citton V, Manara R, Pompanin S, Binotto G, Adami F. Cobalamin deficiency: clinical picture and radiological findings. *Nutrients.* 2013 Nov 15;5(11):4521-39. doi: 10.3390/nu5114521.
11. Sharrief AZ, Raffel J, Zee DS. Vitamin B12 Deficiency With Bilateral Globus Pallidus Abnormalities. *Arch Neurol.* 2012;69(6):769–772. doi:10.1001/archneurol.2011.1084
12. Ota, Y., Capizzano, A.A., Moritani, T. et al. Comprehensive review of Wernicke encephalopathy: pathophysiology, clinical symptoms and imaging findings. *Jpn J Radiol* 38, 809–820 (2020). <https://doi.org/10.1007/s11604-020-00989-3>

13. Hernandez, J. (2023). The Missing Vitamin in Humans! The Impact of Vitamin D Deficiency on Mental Health in Adolescents: A Cross-Sectional Study. *Journal of Advances in Medicine and Medical Research*, 35(4), 103–107. <https://doi.org/10.9734/jammr/2023/v35i44964>
14. Azhari , S. A. (2023) “25-hydroxyvitamin D Level in Autism Spectrum Disorders and the Efficacy of Vitamin D Supplementation in Saudi Autistic Children”, *Journal of Pharmaceutical Research International*, 35(10), pp. 40–47. doi: 10.9734/jpri/2023/v35i107353.
15. Kennedy KP, Alexander JL, Garakani A, Gross LS, Mintz DL, Parikh T, Pine JH, Sumner CR, Baron DA. Vitamin B12 Supplementation in Psychiatric Practice. *Current Psychiatry Reports*. 2024 May 2:1-8.