

Case report

A Case Report on Diode Laser Excision of Focal Fibrous Hyperplasia

ABSTRACT

Oral cavities frequently exhibit local reactive focal overgrowths. Focal fibrous hyperplasia, pyogenic granuloma, peripheral giant cell granuloma, and peripheral ossifying fibroma are all examples of localised reactive lesions that can manifest on the gingiva. This article describes a case of a male patient who reported with a growth measuring around 1x0.8 cm in the buccal aspect of the mandibular anterior teeth, hard in consistency, extending from 42 to 44. Diode laser was used to excise the growth. The growth was diagnosed as focal fibrous hyperplasia based on the characteristic clinical and histopathological features. No adverse events or recurrence occurred during the 6-month follow-up period.

Keywords: traumatic fibroma, irritational fibroma, diode laser, soft tissue lesions

1. INTRODUCTION

Focal fibrous hyperplasia, also called irritation or traumatic fibroma, is a hyperplastic lesion of the connective tissue that is caused by a reaction and inflammation.¹ Masticatory forces, minor trauma, trapped food and debris, plaque, calculus, and iatrogenic factors all contribute to chronic inflammation of the gingival mucosa which leads to development of such lesions. As a result of calculus, caries, or restorations with irregular margins, they often arise in the interdental papilla.² It typically manifests as a sessile, smooth-surfaced, soft, asymptomatic nodule that is yellowish white or a mucosal colour. Hyperkeratosis and ulceration of the surface are possible outcomes of prolonged exposure to trauma or irritation¹. Each group's clinical and radiographic characteristics aid in the diagnosis of each lesion, but histopathological examination is essential for a definitive diagnosis.³ When operating on soft tissues, a surgeon typically uses a scalpel, laser, or traditional electrosurgical unit. For centuries, surgeons have relied on scalpels for their precision, safety, and low collateral damage. However, scalpels do not offer the hemostasis that would be useful when working with highly vascular tissue.⁴

Consistent evidence from studies has shown that, laser surgery can be done safely with parameters that protect the bone and tooth structures underneath. Lasers have a number of benefits, some of which include increased precision, a relatively bloodless surgical and postsurgical course, sterilization of the surgical area, minimal swelling and scarring, coagulation, vaporization, and cutting, minimal or no suturing, and significantly less or no postsurgical pain.⁵ In addition, lasers offer the patient greater postoperative comfort when compared to traditional scalpel procedures^{10,11}. Diode lasers with wavelengths ranging from 810 to 1064 nanometers are the most common type of laser used in aesthetic procedures gingival recontouring, excision of soft tissue lesions, gingival depigmentation and many more. This is because diode lasers have a small volume, are inexpensive, and are simple to operate. They also have the advantage of faster healing and recovery.⁶ The goal of this case report is to demonstrate the superiority of diode laser excision over conventional surgical removal of this benign oral soft tissue lesion.

2. PRESENTATION OF CASE

A 48-year-old male patient reported with the chief complaint of swelling in the lower front teeth region for the past 1.5 years. Growth was associated with bleeding on brushing with no history of pain. Intraoral examination revealed solitary, sessile growth present on the interdental area of the buccal alveolar mucosa concerning the 42 and 43 regions. The lesion was pink in colour with hard and fibrous consistency measuring 1x0.8cm in size.(Fig.1) The oral hygiene of the patient was poor with presence of anterior deep bite. The provisional diagnosis of traumatic fibroma was given based on the history of the patient, clinical and radiographic evaluation. No evidence of hard tissue involvement was found on radiographs.(Fig.2). All necessary blood tests were performed and found to be within normal limits, and informed consent was obtained from the patient prior to treatment.

To remove local irritants, full mouth oral prophylaxis was performed before excising the lesion. After 14 days excisional biopsy was performed under local anaesthesia using diode laser of 801nm in contact mode.(Fig.3) The area was curettaged to remove any leftover calculus. Proper haemostasis was accomplished without any discomfort to the patient. The patient was advised to take semisolid diet intake for 7 days. The excised growth was sent for histopathological examination.(Fig.4) The histopathological examination under scanner view showed a bit of tissue with epithelium and connective tissue stroma. High power view revealed stratified squamous epithelium and dense fibrous connective tissue stroma with areas of hyperplasia, and overall features after clinicopathological and radiographic correlation suggested the final diagnosis of fibrous hyperplasia.(Fig.4) The patient was reviewed after 10 days, 1 month and 6 months. The lesion completely healed with no signs of recurrence after 6 months.(Fig.5)

3. Discussion

Irritation is a common cause of fibrous epulis, a focal hyperplasia of the gingiva or alveolar mucosa. Many of these lesions are true fibromas, according to Thoma and Goldman, while local irritation is responsible, according to Cooke and Stones.² Frequent incidences of gingival fibrous hyperplasia with mild symptoms are observed. On clinical examination, it will manifest as an increase in the size of gingiva in the interdental papillae. The gingiva usually occurs coral pink or like normal gingiva and sometimes pale in colour with firm consistency. Local irritation resulting from malocclusion, mouth breathing, subpar restoration margins, or orthodontic or prosthetic appliances could be the cause of fibrous hyperplasia.⁷ While fibrous hyperplasia can emerge anywhere in the mouth, the buccal mucosa along the occlusal plane is where it is most often found. Common sites include the labial mucosa, tongue, and gingiva; however, Zarei et al. report that the lesion is most frequently located on the gingiva.⁸ The incidence of the condition is observed to be twice as high in females as compared to males. In most cases, recurrences of this lesion are extremely uncommon. On the other hand, Cook found that out of 78 biopsy specimens, there were only three instances of recurrence.⁹ Although there is a tendency for such overgrowths of gingiva to recur, maintaining excellent oral hygiene may prevent, postpone, or reduce the severity of recurrences of the enlargement.⁷ The recommended approach for managing the gingival lesion involves eliminating local irritants and performing a conservative complete excision of the lesion, followed by regular monitoring to prevent its recurrence.

In the present case, the lesion appeared in an old aged male in the mandibular anterior region as nodular pink fibrous growth with active bleeding on probing and histopathological evaluation revealed presence of dense fibrous connective tissue with stratified squamous epithelium giving the final diagnosis of fibrous hyperplasia. However, diode laser in this case

was used in contact and pulsed mode to avoid more thermal damage to the tissue. Studies investigating the efficacy and safety of diode lasers for the elimination of minor exophytic lesions have indicated that this method is characterised by ease of application, appropriate coagulation, lack of suturing, and minimal levels of inflammation and pain. Additionally, diode laser treatment has been associated with reduced recovery and wound healing time. Diode lasers are also a suitable option for the elimination of benign oral lesions such as ranula, mucocele, pyogenic granuloma and fibrous hyperplasia.⁶ In order to establish a conclusive diagnosis, the biopsy specimen underwent histopathological analysis, resulting in the determination of fibrous hyperplasia as the final diagnosis. The patient was monitored for a period of six months and no evidence of relapse was observed. The probability of recurrence is low unless the underlying trauma persists or recurs.⁴

4. CONCLUSION

In conclusion, diode laser treatment is a highly effective option for the treatment of various benign oral lesions, including fibrous hyperplasia. With reduced recovery and wound healing time, diode lasers are a preferred choice due to the lack of bleeding and pain during the surgical procedure, the absence of suturing requirements, and the lower intensity of postoperative pain. Therefore, diode lasers can be considered the primary option for treatment in the oral cavity.

CONSENT

As per international standard or university standard, patients' written consent has been collected and preserved by the author(s).

Ethical Approval:

As per international standard or university standard guideline participant consent and ethical approval has been collected and preserved by the authors.

REFERENCES

1. de Santana Santos T, Martins-Filho PRS, Piva MR and de Souza Andrade ES. Focal fibrous hyperplasia: a review of 193 cases. J Oral Maxillofac Pathol 2014;18:86-9.
2. Kfir Y, Buchner A and Hansen LS. Reactive lesions of the gingiva: a clinicopathological study of 741 cases. J Periodontol 1980; 51:655-61.
3. Shukla P, Dahiya V, Kataria P and Sabharwal S. Inflammatory hyperplasia: From diagnosis to treatment. J Indian Soc Periodontol 2014; 18:92-4.
4. Pardeshi KV, Mirchandani NM, Agrawal AA and Kale TM. Fibrous hyperplasia: Two case reports. J Dent Lasers 2016;10:23-7.
5. Perry DA, Goodis HE and White JM. In vitro study of the effects of Nd: YAG laser probe parameters on bovine oral soft tissue excision. Lasers Surg Med 1997; 20(1): 39-46.
6. Agop-Forna D, Crețu C, Topoliceanu C, Sălceanu M, Vasincu D and Forna N. Clinical applications of diode lasers in oral surgery: Rom J Oral Rehabil 2020;12(1):24-31.

7. Hine MK. Fibrous Hyperplasia of Gingiva. J Am Dent Assoc 1952; Volume 44(6): 681-91.
8. Zarei MR, Chamani G and Amanpoor S. Reactive hyperplasia of the oral cavity in Kerman province, Iran: a review of 172 cases. Br J Oral Maxillofac Surg 2007; 45(4):288-92.
9. Cooke BE. The fibrous epulis & the fibro epithelial polyp: Their histogenesis & natural history. Br Dent J 1952; 93: 305-9.
10. Do Amaral AL, Carneiro MC, Almeida GD, Santos PS, DO AMARAL AL, CARNEIRO M, ALMEIDA G, DA SILVA SANTOS PS. Surgical Treatment of Oral Fibrous Hyperplasia with Diode Laser: An Integrative Review. International journal of odontostomatology. 2023 Jun;17(2):136-41.
11. Coluzzi, D. J. Fundamentals of lasers in dentistry: basic science, tissue interaction, and instrumentation. J. Laser Dent., 16:4-10. 2008.

Fig.1: pre-operative intraoral

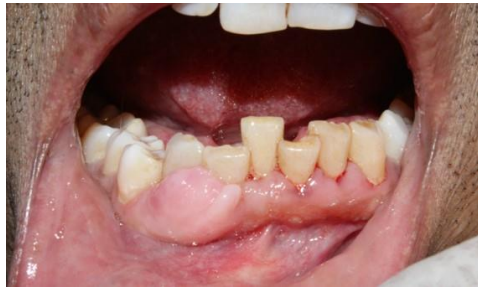

Fig.2: Intraoral periapical radiograph

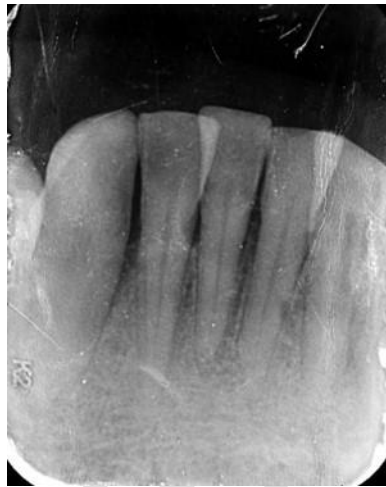

Fig.3 : Immediate post-operative

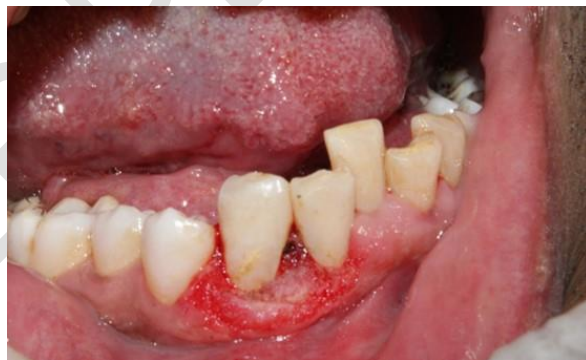




Fig.4: Histopathological examination

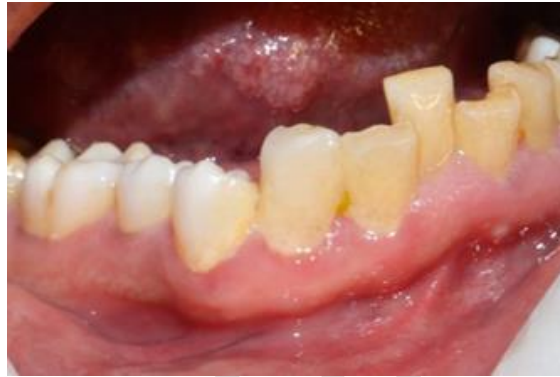

Fig.5: 6 months follow up